

## Incidence Of Synechia Formation After Various Nasal Surgeries

Alpha Omega Kandulna<sup>1</sup>, B.K.Sinha<sup>2</sup>, M. Junaid Alam<sup>3</sup>, Vijaya Bala Murmu<sup>4</sup>  
<sup>1,3</sup> Junior Resident, <sup>2</sup> Associate Professor, Dept. of ENT, Rajendra Institute of Medical Sciences, Ranchi, Jharkhand, India, <sup>4</sup> Senior Resident, Dept. of ENT, Shahid Nirmal Mahto Medical College, Dhanbad, Jharkhand, India.

---

### ABSTRACT

**Introduction:** For a long time intranasal adhesion development has been an important complication in the post operative phase of nasal surgery with an incidence which varies from 10% upto 36%. Nasal adhesions form as a result of contact between raw surface of operated nasal septum and the lateral nasal wall. This results in partial or complete nasal obstruction of affected side.

**Methods:** This is an observational study that was conducted during the period of January 2022 to December 2022 in RIMS, Ranchi in the selected group of patients (n=30) who were operated for various nasal pathologies at ENT OT. They were evaluated for synechia formation.

**Results:** Out of the 30 patients operated for septoplasty (n=6), chronic rhinosinusitis without polyposis (n=6), nasal polyposis (n=16) and CT documentation of sinusitis (n=2), only 4 patients developed synechia in the follow up (13%).

**Conclusion:** The synechia results from traditional methods that are being used which can be overcome by use of powered microdebriders.

**Keywords:** Synechia, FESS.

---

Date of Submission: 04-05-2023

Date of Acceptance: 14-05-2023

---

### I. INTRODUCTION

For a long time intranasal adhesion development has been an important complication in the post operative phase of nasal surgery with an incidence which varies from 10% upto 36%.<sup>1,2</sup>

Functional Endoscopic Sinus Surgery (FESS) has become the standard treatment for the management medically refractory chronic rhinosinusitis and nasal polyps. This is because this approach maintains the sinus mucosa, establishes sinus ventilation and sinus drainage pathway from the natural openings and eliminates the pathology effectively.<sup>3</sup> Synechia formation is the most frequently occurring complication after functional endoscopic sinus surgery (FESS).<sup>4</sup>

Stankiewicz<sup>5</sup> reported synechia in 6.7% of 90 patients. Jacobs et al.<sup>6</sup> reported a 13% incidence of synechia formation. Davis et al.<sup>7</sup> reported synechia in 7.7% of 222 middle meatotomies. Kennedy<sup>8</sup> found middle meatal adhesions in 4% of 227 operated sides. Lazar et al.<sup>9</sup> noted a 27% rate of synechia formation in 513 adults and a 20% rate in 260 children. Gaskins<sup>10</sup> reported an overall scarring incidence of 10.5%, with 4.1% of 970 endoscopic procedures requiring revision surgery because of major scar formation and obstruction.

Nasal adhesions form as a result of contact between raw surface of operated nasal septum and the lateral nasal wall. This results in partial or complete nasal obstruction of affected side. Prevention of post-operative nasal adhesions is an important aspect of nasal surgery. To prevent the formation of these adhesions, meticulous nasal toilet has been advocated. In addition, plastic or silicone splints are placed alongside of nasal septum to prevent contact between raw surface of septum and lateral nasal wall.<sup>11</sup>

### II. MATERIALS AND METHODS

This observational study was conducted during the period of January 2022 to December 2022 in RIMS, Ranchi in the selected group of patients (n=30) who were operated for various nasal pathologies at ENT OT.

**Inclusion criteria were –**

1. Patients aged > 17 years and < 61 years.
2. Patients with DNS presenting with nasal obstructing symptoms and who underwent septoplasty.
3. Patients with chronic rhinosinusitis with no response to medical therapy underwent FESS.
4. Patients with nasal polyposis who underwent FESS.
5. Patients with CT Scan documentation of rhinosinusitis and underwent FESS.

**Exclusion criteria were-**

1. Patients that had previous nasal surgery.
2. Patients presenting with bleeding nasal mass.

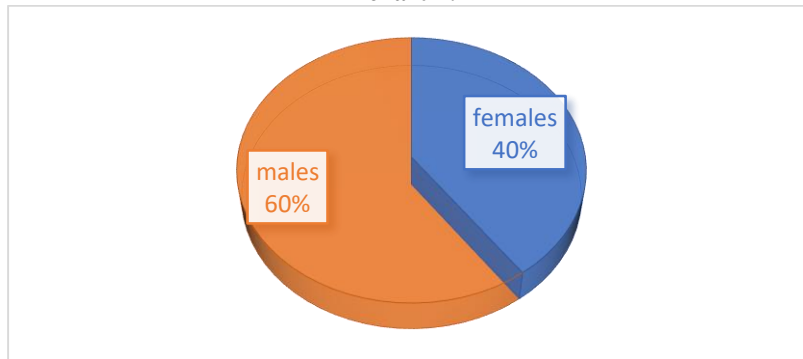
Nasal packing either with Merocel or anterior nasal pack with betadine and liquid paraffin soaked gauge was done and removed after 48 hours in all the patients.

**III. RESULTS**

30 patients satisfied the inclusion criteria in the said period and were followed one week in the post operative period.

Out of 30 patients 18(60%) were males and 12(40%) were females.

**chart 1:**

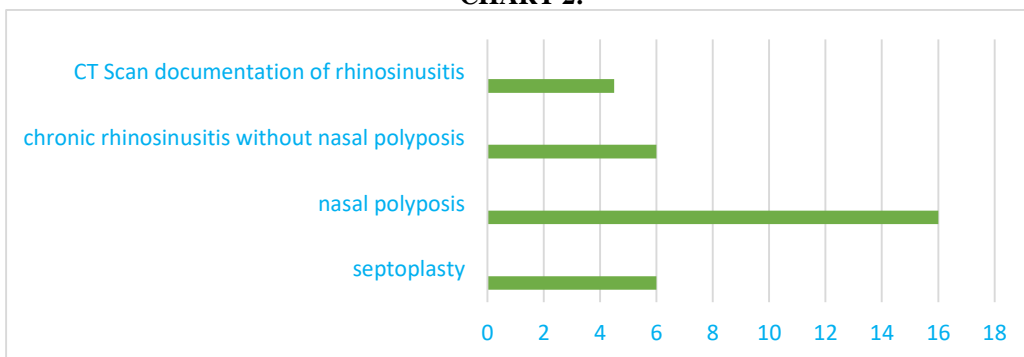


6 patients (20%) underwent septoplasty, 16 patients (53%) underwent FESS for nasal polyposis, 6 patients (20%) underwent FESS for chronic rhinosinusitis without nasal polyposis and 2 patients (7%) underwent FESS for CT Scan documentation of chronic rhinosinusitis.

**Table 1:**

S.NO.	SURGERY AND INDICATION	NUMBER	PERCENTAGE
01	Septoplasty for DNS	06	20%
02	Fess for nasal polyposis	16	53%
03	FESS for chronic rhinosinusitis without nasal polyposis	06	20%
04	FESS for CT Scan documentation of chronic rhinosinusitis	02	7%

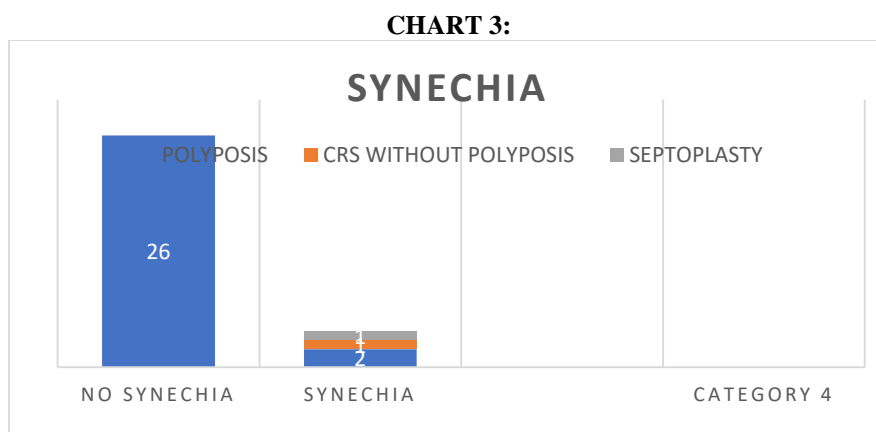
**CHART 2:**



**TABLE 2: CLINICAL PRESENTATION**

S.NO	SYMPTOM	FREQUENCY	PERCENTAGE
01	Nasal obstruction	26	86%
02	Nasal discharge	23	76%
03	Headache/facial pain	16	53%
04	Smell disturbance	13	43%

Out of all those operated 4 patients developed synechia in the follow up period. 2 were of nasal polyposis and one each in septoplasty and chronic rhinosinusitis without polyposis.



#### IV. DISCUSSION

Synechia formation occurs when two opposing denuded mucosal surfaces are allowed to adhere in the process of healing. Most of these synechia are described anteriorly between the lateral nasal wall and middle turbinate.<sup>12</sup>

The probable causes may include middle turbinate trauma, back biting of lateral nasal wall, stripping of mucosa at the junction of middle turbinate and lateral nasal wall.<sup>4</sup> The Blakesley forceps traditionally used causes undue trauma by tearing and stripping off the normal mucosa and leaving exposed areas. In traditional techniques there is frequent need for insertion and removal of instruments and suction tip that adds to the trauma. On the other hand if a powered microdebrider is used, its cutting rather than pulling action of mucosa avoids undue stripping of it. Additionally the continuous suction that is available with microdebrider reduces the frequent needs of insertion and removal of suction.

In the present study the rate of synechia formation is at about 13 % that is concurrent with the prevailing data that ranges from 4% to 27%.<sup>5,6</sup> the probable explanation may be using the traditional methods and not the powered microdebrider.

Hence minimizing tissue trauma and preserving as much as normal mucosa is very much needed to avoid synechia formation and further complications.

#### V. CONCLUSION

The synechia formation after various nasal surgeries was found to be about 13 % (4 out of 30 patients). This probably may be due to traditional methods used in our OT that causes undue trauma to mucosa contrary to minimum trauma caused by the microdebrider.

#### References

- [1]. Shone GR, Clegg RT, Nasal adhesions . Journal of Laryngology and Otology, 1987;101:555-57.
- [2]. White A, Murray JA. Intranasal adhesions following surgery for chronic nasal obstruction. Clinical Otolaryngology, 1988;13:139-43.
- [3]. Gupta M, Motwani G. Role of mitomycin C in reducing adhesion formation following endoscopic sinus surgery. J Laryngol Otol 2006; 120:921-3.
- [4]. Bernstein JM, Lebowitz RA, Jacobs JB. Initial report on postoperative healing after endoscopic sinus surgery with microdebrider. Otolaryngol Head Neck Surg 1998; 118:800-3.
- [5]. Stankiewicz JA. Complications of intranasal endoscopic ethmoidectomy. Laryngoscope 1987;97:1270-3.
- [6]. Jacobs JB, Gittelman P, Holliday R. Endoscopic sinus surgery for ostiomeatal disease. Am J Rhinol 1990;4:41-3.
- [7]. Davis WE, Templer JW, LaMear WR. Patency rate of endoscopic middle meatus antrostomy. Laryngoscope 1991;101:416-20.
- [8]. Kennedy DW. Prognostic factors, outcomes, and staging in ethmoid sinus surgery. Laryngoscope 1992;102(Suppl 57):1-18.
- [9]. Lazar RH, Younis RT, Long TE. Functional endonasal sinus surgery in adults and children. Laryngoscope 1993;103:1-5.
- [10]. Gaskins RE. Scarring in endoscopic ethmoidectomy. Am J Rhinol 1994;8:271-4.
- [11]. Maka TA, Khan Z, Akhtar U, Akram B, Iqbal M. Role Of Intranasal Splints In Preventing Postoperative Nasal Mucosal Adhesions. Pak Armed Forces Med J. 2018;68(1):101-5.
- [12]. Lazar RH, Younis RT, Long TE, Gross CW. Revision functional endonasal sinus surgery. Ear Nose Throat J 1992;71:131-3.