

Atypical Dental Anomalies Associated With Noonan Syndrome – A Case Report

Dr. Indhumathi. E¹, Dr. G.V. Murali Gopika Manoharan²

¹(Post-graduate, Department of Oral Medicine and Radiology, Tamil Nadu Government Dental College and Hospital, Chennai, Tamil Nadu, India)

²(Professor, Department of Oral Medicine and Radiology, Tamil Nadu Government Dental College and Hospital, Chennai, Tamil Nadu, India)

Abstract: Noonan syndrome which resembles Turner syndrome is an autosomal dominant multisystem disorder. Both sexes are affected by this syndrome, with incidence of one per 2500 to one per 1000. Patients with Noonan syndrome display a variety of clinical manifestations because of its genetic variability. Some of the frequently seen clinical characteristics are congenital heart abnormalities, thoracic deformities, short neck with webbing, hypertelorism, and malocclusions. A case of Noonan syndrome with atypical dental anomalies such as multiple impacted permanent teeth and impacted supernumerary teeth was presented herewith. The oral manifestations of Noonan syndrome have not been extensively summarized in the literature, despite the fact that the clinical signs of the condition have been widely studied. Because of diversity in clinical presentation and the need for multidisciplinary care, Dental surgeon and General physician should consider dental anomalies along with other systemic manifestation while diagnosing Noonan syndrome.

Key Word: Noonan syndrome, supernumerary teeth, impacted teeth, Dental anomalies

Date of Submission: 11-05-2023

Date of Acceptance: 21-05-2023

I. Introduction

In 1962, Jacqueline Noonan, a pediatric cardiologist, recognized 9 patients with striking facial similarity, short stature, significant chest deformities, and pulmonary stenosis. Dr. Noonan published a case series in 1968 that included these 9 cases with additional 10 patients with similar features.¹ The term "Noonan syndrome" was coined in honor of Dr. Noonan since she was the first to point out that this disorder might inherit in families, affected both sexes, and was linked to normal chromosomes. It also included congenital cardiovascular disorders. Noonan syndrome is a term used to describe phenotypic males and females who have certain defects that also occur in females with Turner syndrome.² A large forehead, hypertelorism, down-slanting palpebral fissures, a high arched palate, and low-set, posteriorly rotated ears are the characteristic facial traits with 90% of patients having cardiac involvement. Pulmonic stenosis and hypertrophic cardiomyopathy are the most prevalent forms of cardiac disease; however, a number of other disorders are also encountered. Multiple skeletal malformations (chest and spine deformities), webbed neck, mental retardation, cryptorchidism, and bleeding diathesis are other rather common features.³ The most common oral manifestation in Noonan syndrome individuals are high arched palate (55–100%), dental malocclusion (50–67%), articulation difficulties (72%), and micrognathia (33–43%).⁴ The present case report details unusual dental anomalies in a patient with NS, combined with other recognized clinical features.

II. Case report

A 15-year-old female patient was referred from Department of Pediatrics to the Department of Oral Medicine and Radiology for routine dental check-up. The history revealed that she was born of non-consanguineous marriage as second child. She was born full term by vaginal delivery. Her medical history revealed that she has been under medication for pulmonary arterial hypertension for past 12 years and has delayed puberty. Her dental history revealed that this was her first dental visit and had not undergone any dental treatments before. Examination of the parents and the elder sibling revealed that they were not having any similar problem. Patient was fully examined extraorally and intraorally.

On general examination, the patient was conscious, cooperative and well-oriented. She had no sign of pallor, icterus, cyanosis, lymphadenopathy, clubbing, and pedal edema. The patient was afebrile with pulse rate of 100 beats per minute. Respiratory rate was 20 cycles per minute and blood pressure was 100/60 mmHg. The patient was short statured with the height of 117.5cm which was comparatively lesser than the same age group individuals (figure 1). Chest examination revealed characteristic pectus excavatum.

On local examination extraorally, the patient presented with the characteristic feature of convex profile with flattened bridge of the nose and low set ears. Webbing of neck which is a characteristic feature was evident. The lips were potentially competent (figure 2a & 2b). Her eyes showed hypertelorism with downwardly slanted palpebral fissures and hooded eyelids (figure 3).

Figure 1: Short stature of the patient



Figure 2a: Lateral view

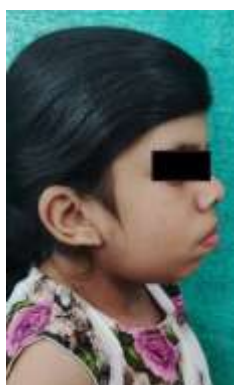

Figure 2b: Extraoral view

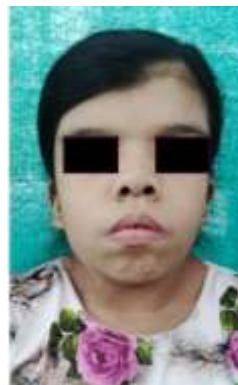

Figure 3: Eyes showing hypertelorism and down slanted palpebral fissures

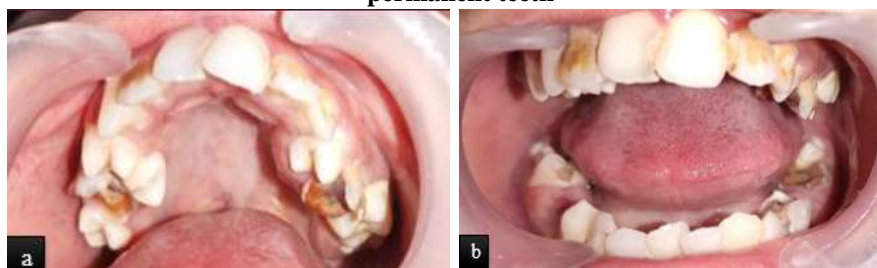


Intraoral examination revealed permanent dentition with poor oral hygiene and generalised gingival inflammation was evident (figure 4). The dentition showed crowding in both maxillary and mandibular arches with characteristic high arched palate. Many permanent teeth were unerupted (23,25,35,45) with multiple retained deciduous teeth (63,65). Multiple carious teeth (16,65,36,46) were evident.(figure 5a & 5b)

Figure 4: Intraoral view

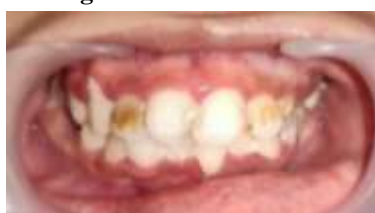

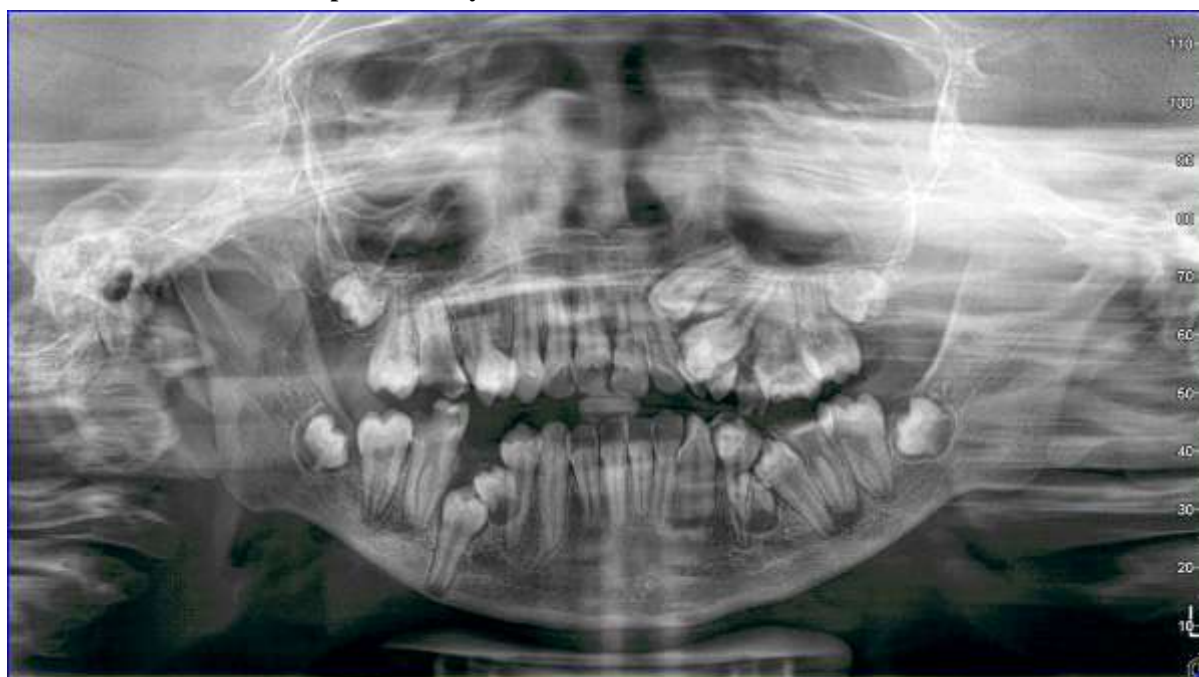Figure 5a,b- Intraoral images showing high arched palate, multiple carious teeth and multiple unerupted permanent teeth



Dental panoramic radiograph revealed multiple impacted permanent teeth 23,25,35,45. Two impacted supernumerary teeth were evident. One supernumerary tooth was present in between 34 and 35 and another supernumerary tooth in between 44 and 45. Coronal radiolucency involving pulp were seen in relation to 16, 65,36, 46. Taurodontism was evident in all maxillary and mandibular molars with developing tooth bud of all third molars. Condylar morphology was normal with no signs of TMJ ankylosis (figure 6). Correlating the history and clinical findings, the case was provisionally diagnosed as Noonan syndrome with differential diagnosis of Turner syndrome, Costello syndrome and Cardiofaciocutaneous syndrome.

Figure 6: Orthopantomogram showing multiple impacted permanent teeth, multiple impacted supernumerary teeth and taurodontism of all molars.



The IQ assessment revealed mild intellectual disability of IQ 65 with patient's basal age being 6 years and terminal age of 14 years. The ophthalmic examination revealed myopia and horizontal nystagmus. Doppler ECHO revealed dilated right atrium and right ventricle, moderate tricuspid regurgitation, Pulmonary hypertension, Supraclavicular mild pulmonary stenosis, moderate Pulmonary regurgitation, IAS septal aneurysm. Based on the reports of investigations, it was finally diagnosed as Noonan syndrome.

III. Discussion

Noonan syndrome is an autosomal dominant disorder. Although patients appear to have normal sex chromatin, it phenotypically resembles Turner syndrome. The underlying cause for Noonan syndrome is unknown. There have been cases found that are both sporadic and autosomal dominant.⁵ Turner syndrome-like characteristics of the body make NS also known as "Pseudo Turner syndrome" in females and "Male Turner syndrome" in males.⁶ No recurrent chromosomal aberration has been identified in NS.⁷ The 12q22 area contains a gene for Noonan Syndrome NS 1, however there is genetic variability.⁵ SHP 2 (src omology region 2 domain

phosphatase 2), a non-receptor protein tyrosine phosphatase, is encoded by the gene PTPN11, which was recently found to be damaged.⁸

The facial features are most distinctive throughout infancy and the early to middle years of childhood, and they become less obvious when individuals age.⁴ It is hypothesised that the orofacial characteristics of NS are caused by edema of the face and neck caused by developmental abnormalities of the third and fourth pharyngeal arches.⁹ Many adults have characteristics that don't significantly differ from those of the general community. Other adults can be identified by their wide-set eyes, low-set ears that are rotated posteriorly and have a fleshy helix, an inverted triangle-shaped face that is broad at the temples and tapers to a small chin, and a long, broad, or webbed neck.¹⁰ In the present case, the patient showed hypertelorism, down slanting palpebral fissures with hooded eyelids, flat nasal bridge, low set ears, webbing of neck and pectus excavatum. This patient has characteristic cardiovascular disease which was consistent with the reported prevalence of 50–80% cardiovascular changes in NS patients.¹¹

Noonan's syndrome has a number of oral characteristics, including micrognathia, a high arched palate, dental malocclusion, dental malformations, a bifid uvula, and, very infrequently, a cleft palate.^{6,12} Our case distinctively included numerous impacted supernumerary teeth, retained deciduous teeth, and multiple impacted permanent teeth.

Despite the fact that numerous case reports did not support the existence of supernumerary teeth, Ortega et al. and Toureno and Park documented the presence of supernumerary teeth.^{13,14} In this case, the patient had two impacted supernumerary teeth in either side of mandibular premolar region and four impacted permanent teeth along with taurodontism in all molars.

For NS patients, oral health care should begin within the first year of life in order to stop dental issues before they progress and become permanent.¹⁵ Due to their propensity for severe dental caries and gingival issues, it is crucial to keep an eye on the oral health of NS patients.¹⁶ The primary goal of the dental treatment was to extract the retained deciduous teeth as well as the impacted supernumerary teeth, and to aid in the eruption of impacted permanent teeth. Due to the high occurrence of cardiac, ocular, growth, orthopaedic, and dental anomalies, the necessity for early detection should be emphasised in these instances.¹⁷

IV. Conclusion

There are no known confirmatory or diagnostic tests for Noonan Syndrome. Due to the distinctive dental and skeletal characteristics, this entity remains completely a clinical diagnosis, and the role of dental surgeons might be crucial in the diagnosis of this syndrome. Numerous oral malformations might be associated with Noonan syndrome, necessitating interdisciplinary treatment planning and prompt therapy. It is very essential to take oral manifestations into consideration as a criterion in the diagnosis of Noonan syndrome since the significance of oral findings in Noonan syndrome has largely gone neglected.

References

- [1]. Noonan JA. Hypertelorism with Turner phenotype. A new syndrome with associated congenital heart disease. *Am J Dis Child* 1968;116:373-80.
- [2]. Nora JJ, Nora AH, Sinha AK, Spangler RD, Lubs HA. The Ullrich-Noonan syndrome (Turner phenotype). *Am J Dis Child* 1974;127:48-55.
- [3]. OMIM, Online Mendelian Inheritance in Man. Available from: <http://www.omim.org/entry/163950>. [Last accessed on 2014 Jul 14].
- [4]. Romano AA, Allanson JE, Dahlgren J, Gelb BD, Hall B, Pierpont ME, et al. Noonan syndrome: Clinical features, diagnosis, and management guidelines. *Pediatrics* 2010;126:746-59.
- [5]. van der Burgt I. Noonan syndrome. *Orphanet J Rare Dis* 2007;2:4.
- [6]. Lee SM, Cooper JC. Noonan syndrome with giant cell lesions. *Int J Paediatr Dent* 2005;15:140-5.
- [7]. Okada M, Sasaki N, Kaihara Y, Okada R, Amano H, Miura K, et al. Oral findings in Noonan syndrome: Report of a case. *J Oral Sci* 2003;45:117-21.
- [8]. Asokan S, Muthu MS, Rathna Prabhu V. Noonan syndrome: A case report. *J Indian Soc Pedod Prev Dent* 2007;25:144-7.
- [9]. Terezhalmay GT, Moore WS. Noonan syndrome presenting with oral and dentofacial abnormalities. *Quintessence Int* 2002;33:554-5.
- [10]. Allanson JE. Noonan syndrome. *Am J Med Genet C Semin Med Genet* 2007;145C: 274-9.
- [11]. Noonan JA. Noonan syndrome revisited. *J Pediatr* 1999;135:667-8.
- [12]. Sahebameer M, Ameri NG, Farhud DD. First report of new oral findings in a case with Noonan syndrome. *Iran J Public Health* 2008;37:131-7.
- [13]. Ortega Ade O, Guará Rde O, Kawaji NS, Ciamponi AL. Orofacial aspects in Noonan syndrome: 2 case report. *J Dent Child (Chic)* 2008;75:85-90.
- [14]. Toureno L, Park JH. Atypical orofacial conditions in Noonan syndrome: A case report. *J Clin Pediatr Dent* 2011;36:197-202.
- [15]. Ierardo G, Luzzi V, Panetta F, Sfasciotti GL, Polimeni A. Noonan syndrome: a case report, *Eur J Paediatr Dent*, 2010, 11(2):97–100.
- [16]. Mallineni SK, Yung Yiu CK, King NM. Oral manifestations of Noonan syndrome: review of the literature and a report of four cases. *Rom J Morphol Embryol*. 2014 Jan 1;55(4):1503.
- [17]. Uloopi KS, Madhuri V, Gopal AS, Vinay C, Chandrasekhar R. Multiple unerupted permanent teeth associated with Noonan syndrome. *Ann Med Health Sci Res* 2015;5:317-20.