

Case Report Of Nanophthalmos Masquerading As Multifocal Choroiditis

Dr. Chetan Gaikwad, Dr. N. Sudha J, Dr. Nipun Bagrecha

Abstract

The term nanophthalmos is derived from the Greek word “nano” meaning “dwarf,” and ophthalmos meaning eye. It is a rare condition and results from the developmental arrest of the globe in all dimensions without other major malformations and has a strong genetic basis. Different fundoscopic appearances have been shown in nanophthalmic eyes, including crowded hyperemic discs, pigmentary changes from retinal flecks to bone spicules, bull's eye maculopathy, macular hypoplasia, retinal and macular cysts, and papillomacular folds. We report a rare case of nanophthalmos presenting with midperipheral chorioretinal pigment abnormalities giving a clinical suspicion of multifocal choroiditis.

Keywords: nanophthalmos, hyperopia, retinal flecks, choroiditis.

Date of Submission: 19-05-2023

Date of Acceptance: 29-05-2023

I. INTRODUCTION

Nanophthalmos is a clinical phenotype of simple microphthalmos with a phenotypically small but structurally normal eye.⁽¹⁾ The condition is defined by high hyperopia ($> +5$ diopters) and/or short axial eye length ($< 20\text{mm}$).⁽²⁻⁵⁾ It poses a significant clinical challenge to ophthalmologists as it has short axial length, thickened sclera, small cornea, shallow anterior chamber and increased lens to eye volume ratio.⁽¹⁾ Increased central macular thickness, subfoveal and nasal choroidal thickness are reported in these patients. These eyes have a propensity to develop high rate of secondary angle-closure glaucoma, spontaneous choroidal effusions, and perioperative complications with cataract and retinal surgeries. It may present as a sporadic or familial disorder, with autosomal-dominant or recessive inheritance.⁽⁶⁾

II. CASE REPORT

60 year old male with no known medical illness presented with complaints of floaters in his left eye since last 4 months. History of wearing contact lenses in both eyes since last 25 years. No complaints of pain, redness, watering, diminution of vision and flashes in either eye. No history of systemic illness or any other surgeries done in the past.

On ocular examination, best corrected visual acuity was 6/9 in both eyes with +11.00 dioptre sphere in right eye and + 12.00 dioptre sphere in left eye. Near vision was N6 with +2.00 dioptre sphere in both eyes. Intraocular pressure was normal in both eyes. Pupillary reactions, colour vision and visual fields showed no abnormality. Anterior segment examination revealed shallow occludable angles in both eyes as confirmed by indirect gonioscopy. Rest of the anterior segment examination was unremarkable. Fundus examination revealed posterior vitreous detachment in left eye with hyperemic and crowded discs with blurred margins and normal macula in both eyes. Multiple irregular hypopigmented yellowish choroidal patches with irregular borders were seen in mid peripheral retina in both eyes with overlying normal retinal blood vessels (Figure 1). A- scan measurements showed axial length of 17.60mm in right eye and 17.61 mm in left eye with white to white corneal diameter of 11.82mm right eye and 11.80mm in left eye.

Bilateral multiple irregular yellowish patches on fundus examination were seen. A clinical diagnosis of bilateral multifocal choroiditis was made. Complete blood count (CBC), erythrocyte sedimentation rate (ESR), venereal disease research laboratory test (VDRL), mantoux test, serum angiotensin converting enzyme levels (Serum ACE levels), blood sugar profile and High resolution computed tomography of chest (HRCT Thorax) were performed.

All of the above tests revealed no significant abnormality. Fundus fluorescein angiography was performed which revealed bilateral staining of the multiple irregular hypopigmented patches with no evidence of leakage or vessel wall staining (Figure 2). No disc leak was present in both eyes. Based on the above findings, diagnosis of bilateral nanophthalmos with posterior vitreous detachment in left eye was made. Prophylactic peripheral iridectomy was advised in view of occludable angles.

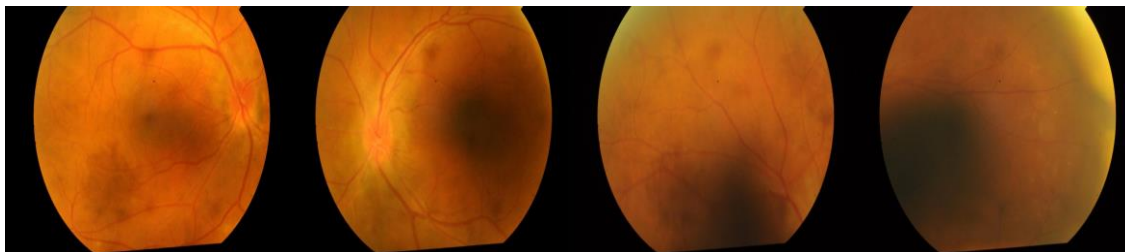


Figure 1-Fundus examination showing multiple irregular hypopigmented yellowish choroidal patches with irregular borders were seen in mid peripheral retina in both eyes with overlying normal retinal blood vessels

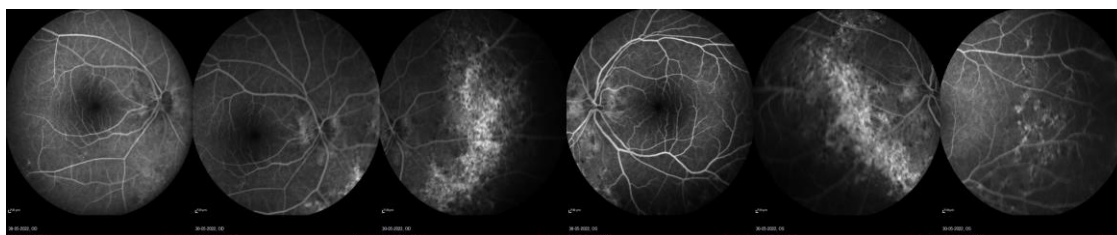


Figure 2- Fundus fluorescein angiography showing bilateral staining of the multiple irregular hypopigmented patches with no evidence of leakage or vessel wall staining.

III. DISCUSSION

Nanophthalmos is a developmental disorder of the eye in which both the anterior and posterior segments are not developed to full dimensions without major structural abnormalities. It may be inherited in sporadic, autosomal dominant, or autosomal recessive fashions.⁽⁷⁾ Small corneal diameter ranging between 9.5 and 11 mm, a shallow anterior chamber depth, ranging from less than 1 mm to 2.7 mm, an increased crystalline lens to total eye volume ratio, and an axial length of 20.5 mm or less are characteristics of nanophthalmos. Various macular changes including papillomacular folds and macular radial folds have been described with nanophthalmic eyes. Crowded discs and yellowish reflex are also a characteristic. Foveal avascular zone abnormalities in nanophthalmic eyes have been reported. Pigmentary retinal degeneration also rarely occurs.⁽⁸⁾

Timoney et al⁽⁷⁾ reported chorioretinal folds involving both the retina and choroid by in two cases of nanophthalmos associated with Kenny-Caffey syndrome. In the case series of Khan and Zafar⁽⁹⁾ elevated chorioretinal fold of normal thickness with an underlying empty vaulted area was reported. Papillomacular folds seen in nanophthalmos were only composed of neurosensory retina without involvement of retinal pigment epithelium and choroid. Crowded posterior segment in nanophthalmic eyes may lead to retinal changes. High refractive amblyopia and chorioretinal changes are the major causes of low vision in these patients.

In our case also, multiple discrete irregular chorioretinal folds in the mid periphery were seen in both eyes due to the crowding of posterior segment which happens in nanophthalmos. These multiple chorioretinal patches seen on fundus examination can give a clinical suspicion of bilateral multifocal choroiditis in these patients but fluorescein angiography and optical coherence tomography findings were not in accordance with multifocal choroiditis. Thus the above ophthalmic features are to be kept in mind while evaluating a case of nanophthalmos.

References:

- [1]. Yang N, Zhao LL, Liu J, Ma LL, Zhao JS. Nanophthalmos: An Update on the Biological Parameters and Fundus Abnormalities. *J Ophthalmol*. 2021 Mar 11;2021:8853811.
- [2]. Utman S. A. K. Small eyes big problems: is cataract surgery the best option for the nanophthalmic eyes? *Journal of the College of Physicians and Surgeons—Pakistan*. 2013;23(9):653–656.
- [3]. Seki M., Fukuchi T., Ueda J., et al. Nanophthalmos: quantitative analysis of anterior chamber angle configuration before and after cataract surgery. *British Journal of Ophthalmology*. 2012;96(8):1108–1116. doi: 10.1136/bjophthalmol-2012-301496.
- [4]. Faisal A. A., Kamaruddin M. I., Toda R., Kiuchi Y. Successful recovery from misdirection syndrome in nanophthalmic eyes by performing an anterior vitrectomy through the anterior chamber. *International Ophthalmology*. 2019;39(2):347–357. doi: 10.1007/s10792-017-0818-6. [
- [5]. Awadalla M. S., Burdon K. P., Souzeau E., et al. Mutation in TMEM98 in a large white kindred with autosomal dominant nanophthalmos linked to 17p12-q12. *JAMA Ophthalmology*. 2014;132(8):970–977. doi: 10.1001/jamaophthalmol.2014.946.
- [6]. Carricondo PC, Andrade T, Prasov L, Ayres BM, Moroi SE. Nanophthalmos: A Review of the Clinical Spectrum and Genetics. *J Ophthalmol*. 2018;2018:2735465. Published 2018 May 9.
- [7]. Timoney P, Darcy F, McCreery K, Reardon W, Brosnahan D. Characterization of optical coherence tomography findings in Kenny-Caffey Syndrome. *Journal of AAPOS*. 2007;11(3):291–293.
- [8]. Ally, N., Ismail, S. & Alli, H.D. Prevalence of complications in eyes with nanophthalmos or microphthalmos: protocol for a systematic review and meta-analysis. *Syst Rev* 11, 25 (2022).

- [9]. Khan A, Zafar SN. Variable retinal presentations in nanophthalmos. *Journal of the Pakistan Medical Association*. 2009;59(11):791–793.

Figure Legends:

- [1]. Fundus Photographs of Right and left eye depicting crowded hyperemic discs with blurred disc margins. Multiple irregular hypopigmented choroidal patches were seen in midperiphery in both the eyes.
- [2]. Fundus Fluorescein angiography of both eyes depicting staining of midperipheral hypopigmented patches in both the eyes.