

Papulosquamous Lesions In Secondary Syphilis With Hiv Infection

Rieska Widyaswari, Prasetyadi Mawardi

Department Of Dermatology Dan Venereology, Dr. Moewardi General Hospital/Faculty Of Medicine, Sebelas Maret University, Surakarta-Indonesia

Abstract

Introduction: Syphilis is one of the most common sexually transmitted infections (STIs) caused by spirochete *Treponema pallidum subspecies pallidum*. Clinical manifestations of secondary syphilis are various such as papulosquamous lesions with polymorphic colors and varying sizes. Human immunodeficiency virus (HIV) exposure through men who have sex with men (MSM) contact is a risk factor for syphilis transmission due to high-risk sexual behavior.

Case: A 36-year-old man came with chief complaints of non-itchy reddish spots on his head, neck, palms, soles, and genitals 3 weeks prior. The patient is an MSM and has been diagnosed with HIV since 2017. Physical examination showed multiple erythematous patches and papules with thin scales in the capital region, superior and inferior extremities, and scrotum. The palmar and plantar regions showed multiple erythematous patches with peripheral scale (Biett's collarete). The results of the Venereal Disease Research Laboratories (VDRL) examination were reactive with a titer of 1:256 and *Treponema Pallidum Hemagglutination Assay (TPHA)* > 1:5120. The treatment given to the patient was a single intramuscular injection of benzathine penicillin G 2.4 million IU. Follow-up was carried out at 1, 3, and 6 months. The results of repeated VDRL examinations in the 6th month was 1:64.

Discussion: Secondary syphilis has various skin manifestations. Papular lesions in secondary syphilis vary in size with the commonest areas in the palmoplantar region, trunk, extremities, and face. Typical maculopapular lesions can be found on the palms or soles called "Biett's collarete". The highest risk factor for increasing the incidence of syphilis is MSM and HIV. The management of secondary syphilis according to the CDC is by a single dose of benzathine penicillin G 2.4 million units intramuscularly. Clinical and serological improvement was evaluated at 1 month, 3 months, 6 months, and 12 months after treatment.

Conclusion: Secondary syphilis has various forms of lesions. One of the characteristic lesions found is a maculopapular erythema with peripheral thin scales on the palms and soles called Biett's collarete. MSM populations and HIV infection are risk factors for syphilis due to high-risk sexual activities. Treatment of secondary syphilis is with a single dose of benzathine penicillin G 2.4 million units intramuscularly

Keywords: HIV, MSM, secondary syphilis

Date of Submission: 01-01-2024

Date of Acceptance: 09-01-2024

I. Introduction

Syphilis is one of the most common sexually transmitted infections (STIs) worldwide.¹ Six million new cases of syphilis per year are found throughout the world with the highest incidence rate found in men aged 15-49 years.² Research in the United States in 2018 reported that at least 50% of men with syphilis were homosexual and 42% were infected with HIV.³ Mawardi et al. in 2019 in Surakarta reported a prevalence of syphilis of 13.7% in the homosexual and transgender population at RSUD Dr. Moewardi and community health centers during March-July 2017.⁴

The manifestations of secondary syphilis are very varied and often resemble skin lesions in other diseases, so it is called "The Great Imitator". The rash in secondary syphilis can be pustular, macular, papular, or scaly lesions which can spread locally or generally.⁵ The initial lesions in secondary syphilis are generally symmetrical, non-itchy, and pink to brownish purple. Lesions can thicken with a papulosquamous appearance with polymorphic colors and varying sizes.⁶

Syphilis is still a global public health problem, especially due to the increase in cases in high-risk groups such as MSM and HIV infection. Treatment for primary and secondary syphilis according to the Centers for Disease Control and Prevention (CDC) is by administering a single dose of benzathine penicillin G 2.4 million units intramuscularly.⁷ This case report discusses a case of secondary syphilis with clinical manifestations of papulosquamous lesions in an MSM man infected with HIV. The purpose of this case report is to add insight into secondary syphilis diagnosis and therapy that can be used in clinical practice.

II. Case

A 36-year-old man was referred from the Voluntary Counseling and Testing (VCT) department with complaints of non-pruritic reddish spots on the head, neck, palms, soles, and genitals 3 weeks ago. Since 2017, the patient has been diagnosed with HIV infection with the treatment of efavirenz, lamivudine, and tenofovir. The patient is a multi-partner MSM with anogenital and orogenital sexual orientation. Physical examination in the capital, superior, and inferior extremities, and scrotum region showed patches and multiple discrete erythematous macular and papular, some of which were hyperpigmented with thin scales on them. In the bilateral palmar manus et plantar pedis region, multiple discrete erythematous patches with peripheral scaling (Biett's collarete) were visible (**Figure 1**).

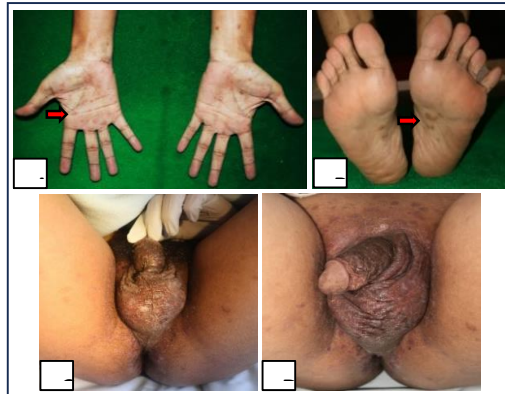


Figure 1. (A-B). In the bilateral palmar and plantar regions, multiple discrete erythematous patches with scaling at the edges (Biett's collarete) were visible. **(C-D).** The genital region shows multiple discrete erythematous patches and papules with thin scales.

The results of the VDRL examination were reactive with a titer of 1:256 and TPHA >1:5120. A cluster of Differentiation (CD) level examination carried out on October 16 2020 showed absolute CD4 486 cells/ul (reference value: 500-1600 cells/ul), absolute CD8 1,517.81 (reference value: 259-1262), and CD4 ratio: CD8 of 46.75%. Based on the results of the history, physical examination, and laboratory examination, the patient's working diagnosis in this case was secondary syphilis with HIV infection.

The treatment given to the patient was a single intramuscular injection of benzathine penicillin G 2.4 million IU. After administering the injection, there were no allergic reactions, fever, or Jarisch-Herxheimer reactions. Follow-up was carried out at months 1, 3 and 6. The results of re-examination of VDRL in the 1st month after treatment were 1:128 and in the 6th month were 1:64. Improvement in the lesions began to appear in the 2nd week after therapy and no new lesions were found (**Figure 2**).

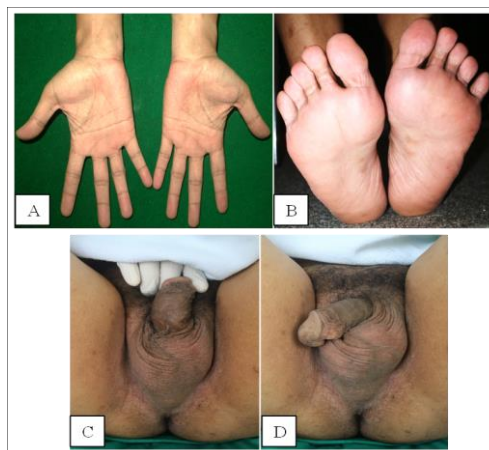

Figure 2. 6th-month follow-up. (A-D). No new lesions were found and the old lesions had disappeared leaving multiple hyperpigmented patches on the bilateral plantar pedis and scrotum.

III. Discussion

Syphilis is a sexually transmitted infection caused by *Treponema pallidum subspecies pallidum*. *Treponema pallidum subspecies pallidum* is a spiral-shaped motile organism with humans as its only natural host. This bacterium has a length of 5-16 μm with a diameter of 0.2-0.3 μm .^{8,9} The incidence of primary and secondary syphilis according to CDC surveillance data in the United States in 2019 was 38,000 cases with the majority of cases found in MSM (56.7%).¹⁰

HIV infection is closely related to syphilis, especially in MSM patients because of the same transmission method and an increase in high-risk sexual behavior such as unprotected sex, multiple partners, or drug use.¹¹ Research by Wu et al in China in 2021 reported that Syphilis infection increases the risk of HIV transmission up to 3-fold and MSM patients with HIV infection have a 96% higher rate of syphilis reinfection compared to MSM without HIV infection.¹² Active *T. pallidum* infection, on the other hand, can also worsen biological parameters associated with HIV such as reducing treatment response. Every individual infected with syphilis should be screened for HIV infection and vice versa.^{13,14}

Most cases of syphilis are transmitted through sexual contact (vaginal, anogenital and orogenital).¹⁵ Inoculation and penetration of bacteria occurs through mucosal or skin surfaces that experience abrasion, especially in the genital and perianal areas.¹ *Treponema pallidum* after the inoculation phase will attach to host cells including epithelial cells, fibroblasts, and endothelial cells by binding to fibronectin, laminin, or other components of the host cells. Infection in all phases of syphilis causes infiltration of lymphocytes, macrophages, and plasma cells. CD4+ T cells will dominate the chancre lesion in primary syphilis while CD8+ T cells are found most often in secondary syphilis. Syphilis infection also causes an increase in T-helper (Th)-1 cytokines such as interleukin (IL)-2 and interferon (IFN)- γ .⁸ *Treponema pallidum* has a long replication time with an average incubation period before lesions appear of 3 weeks. up to 90 days.¹⁶

Syphilis is a chronic STI whose disease course is divided into 4 stages, namely primary syphilis, secondary syphilis, latent syphilis, and neurosyphilis. Secondary syphilis is the stage of syphilis with the most varied skin manifestations, so it is often referred to as "The Great Imitator". Systemic symptoms such as fever, malaise, sore throat, headache, rash on the skin mucosa, and adenopathy can appear at this stage.^{16,17} The first cutaneous manifestation of secondary syphilis is a non-itchy macule consisting of well-defined erythematous or hyperpigmented lesions (syphilitic roseola) which can heal spontaneously after 20 to 40 days. The classic exanthema typical of secondary syphilis will then appear in the form of a diffuse maculopapular rash of pale pink or reddish color measuring 4 to 8 mm which is not itchy. This rash is usually symmetrical and affects the palms of the hands, soles of the feet, and scrotum, which is then followed by papular exanthema.^{11,17}

Typical lesions of secondary syphilis can be found on the palms of the hands or soles of the feet in the form of papules with thin scales on the edges which are called "Biett's collarette". Lesions in the palmoplantar region are found in 70% of patients with secondary syphilis. On the surface of the macerated skin and mucosa, the lesions often appear hypertrophic and confluent.^{6,18} The patient in this case experienced complaints of non-itching reddish patches on the head, body, palms, soles, and scrotum accompanied by thin scales. Physical examination of the patient's region capital, superior and inferior extremities, and scrotum showed multiple discrete erythematous patches and papules, partially hyperpigmented with thin scaling on top. Biett's collarette was found in the bilateral palmar *et* plantar region.

The diagnosis of syphilis is made based on anamnesis regarding sexual history, physical examination, and laboratory tests. Serological testing is the best method for screening and diagnosing syphilis. Two serological tests that are often used are non-treponemal tests and treponemal tests. The non-treponemal test is an examination to detect IgM and IgG antibodies against cardiolipin and lecithin antigens released by bacteria.¹⁹ The most widely used types of non-treponemal tests are VDRL and rapid plasma reagin (RPR). A treponemal test must follow reactive results on the VDRL test. Treponemal serology tests such as TPHA detect antibodies to treponemal antigens and have higher sensitivity than non-treponemal tests. A positive treponemal test result can rule out the possibility of a false positive result in a non-treponemal examination. Individuals with a history of syphilis will usually have positive treponemal test results throughout their lives even after successful therapy.⁸ The results of the patient's serological examination in this case showed reactive VDRL with a titer of 1:264 and reactive TPHA with a titer of >1:5120, thus supporting the diagnosis of secondary syphilis.

Management of syphilis based on CDC recommendations is administration of benzathine penicillin G. The recommended dose in the secondary syphilis stage is 2.4 million units in a single dose intramuscularly. Alternative therapy that can be used is doxycycline 100 mg/12 hours orally for 14 days. Management of syphilis in patients with HIV co-infection is no different from patients without HIV infection.⁷ Evaluation of clinical and serological improvement in syphilis patients is important to ensure cure and detect re-infection, recurrence, or therapy failure. Clinical and serological evaluation of early syphilis was carried out at 1 month, 3 months, 6 months, and 12 months after treatment. The nontreponemal test titer obtained at the beginning of the examination will decrease ≥ 4 times in the 6th month.⁷ Evaluation of clinical improvement and serological tests in this patient was carried out at the 1st month, 3rd month, and 6th month. Clinical improvement began to appear in the 2nd

week after treatment with visible improvement of the lesion and the absence of new lesions. Clinical evaluation at 6 months found no new lesions and the old lesions had disappeared leaving multiple hyperpigmented patches on the bilateral plantar pedis and scrotum. Evaluation of VDRL at the 1st month showed a 2-fold decrease to 1:128, in the 3rd month the VDRL titer remained at 1:128, and in the 6th month after therapy, there was a 4-fold decrease in VDRL to 1:64, indicating a successful response to therapy.

IV. Conclusions

This paper reports a case of secondary syphilis with maculopapular lesions in an HIV-infected MSM individual. MSM and HIV are closely related to the risk of transmitting syphilis due to high-risk sexual behavior. Clinical manifestations of secondary syphilis have various forms of lesions, one of which is papulosquamous. The characteristic lesion that can be found in secondary syphilis is Biett's collarete found in the palmar and plantar regions. The treatment of secondary syphilis with HIV is no different from the treatment of syphilis without HIV by administering a single dose intramuscular injection of benzathine penicillin G 2.4 million IU. A successful response to therapy was obtained by reducing the VDRL titer by ≥ 4 in 3 or 6 months after giving therapy.

References

- [1]. Peeling Rw, Mabey D, Kamb Ml, Chen X, David J, Benzaken As, Et Al. Hhs Public Access. Syphilis. *Nat Rev Dis Prim*. 2018;3(17073):1–48.
- [2]. Kojima N, Klausner Jd. An Update On The Global Epidemiology Of Syphilis. *Curr Epidemiol Reports*. 2018;5(1):24–38.
- [3]. Ghanem Kg, Ram S, Rice Pa. The Modern Epidemic Of Syphilis. *N Engl J Med*. 2020;382(9):845–54.
- [4]. Mawardi P, Soenardi A, Karyosentono H, Prabandari An, Elitasari Ey. Profile And Risk Factors Of Sexual Transmitted Infection Among Homosexual And Transgender In Surakarta, Central Java. 2019;114–114.
- [5]. Hook Ew. Syphilis. *Lancet*. 2017;389(10078):1550–7.
- [6]. Çakmak Sk, Tamer E, Karadağ As, Waugh M. Syphilis: A Great Imitator. *Clin Dermatol*. 2019;37(3):182–91.
- [7]. Workowski Ka, Bachmann Lh, Chan Pa, Johnston Cm, Muzny Ca, Park I, Et Al. Sexually Transmitted Infections Treatment Guidelines, 2021. Vol. 70, *Mmwr. Recommendations And Reports : Morbidity And Mortality Weekly Report. Recommendations And Reports*. 2021. 1–187 P.
- [8]. Tuddenham Sa, Zenilman Jm. Syphilis. In: Kang S, Amagai M, Bruckner Al, Enk Ah, Editors. *Fitzpatrick's Dermatology 9th Edition*. 9th Ed. New York: Mcgraw Hill Companies; 2019. P. 3145–72.
- [9]. Lukehart Sa. Biology Of Treponemes. In: Holmes Kk, Sparling Fp, Stamm We, Piot P, Editors. *Sexually Transmitted Diseases*. 4th Ed. New York: Mcgraw Hill Companies; 2008. P. 647–59.