

Bell's Palsy

Rishanthi .D-

Undergraduate, Karpaga Vinayaga Institute Of Dental Sciences.

Santhana Lakshmi. M–

Undergraduate, Karpaga Vinayaga Institute Of Dental Sciences.

Sharinchandravandhani.S –

Undergraduate, Karpaga Vinayaga Institute Of Dental Sciences.

Dr. Sandhiya. M –

Postgraduate, Department Of Oral Maxillofacial Pathology, Karpaga Vinayaga Institute Of Dental Sciences.

Dr. Arunachalan.M –

Reader, Department Of Oral Maxillofacial Pathology, Karpaga Vinayaga Institute Of Dental Sciences.

Dr. Sathish Kumar. M –

Hod, Department Of Oral Maxillofacial Pathology, Karpaga Vinayaga Institute Of Dental Sciences.

Abstract:

Bell's palsy is a common cranial neuropathy causing unilateral lower motor neuron facial paralysis immune, infective and ischemic mechanism are potential contributor to the development of Bell's palsy. However the etiology of Bell's palsy is unclear and this affects its treatment. Thus, it is critical to determine the causes of Bell's palsy so that targeted treatment approach he's can be developed and employed. This article reviews the literature of the diagnosis of Bell's palsy and examine the possible etiologies of the disorder.

Key Words: *Bell's palsy; trauma; facial nerve palsy; viral infection; ischemia; inflammation; cold stimulation*

Date of Submission: 10-01-2024

Date of Acceptance: 20-01-2024

I. Introduction :

Bell's palsy is the paralysis or severe weakness of the nerve that controls the facial muscles on the same side of the face the facial nerve (7th cranial nerves). Charles bell know for his studies on the nervous system and the brain. In the 19th century discovery the lesion of the 7th cranial nerves causes facial paralysis. The symptoms may last from hours to day and may become maximum within three weeks. Facial weakness may be partially or fully disappear with 6 months. The attack of Bell's palsy usually seen after the age of 40. It is the most common neurologic disorder of the cranial nerve

Bell palsy (BP) this is most common type of facial palsy . It is a type of idiopathic infranuclear facial palsy, the cause of which is not known. The site of involvement is facial canal. Bell's palsy has been associated with reactivation of herpes simplex type I infection, but its causal role is not established.(1)

Definition :

Bell's palsy cause sudden weakness in facial muscles . This make half your face appears to droop. Your smile is one sided , and your eye on that side resist closing. Bell's palsy also known as facial palsy can occur at any age. The exact cause is unknown , but it believed to be the result of swelling and inflammation of nerve that control the muscles on one side of your face(2). It may be reaction that occurs after a viral infection

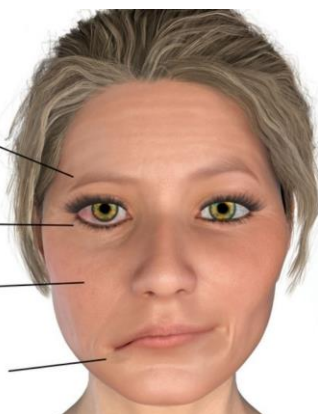Bell's Palsy

Inability to wrinkle brow

Drooping eyelid;
inability to close eye

Inability to puff cheek;
asymmetrical smile

Drooping corner of mouth;
dry mouth



Classification of facial nerve palsy:

The House-Brackmann Facial Nerve Grading System can be used to describe the degree of the facial nerve weakness. This grading system goes from a grade of I (no weakness) to VI (complete weakness).(3)

Grade	Characteristics
I Normal	Normal facial function in all nerve branches
II Mild dysfunction	Slight weakness on close inspection Eye: Complete closure with minimum effort Mouth: Slight asymmetry
III Moderate dysfunction	Obvious but not disfiguring facial asymmetry Eye: Complete closure with effort Mouth: Slight weakness with maximum effort
IV Moderately severe	Asymmetry is disfiguring and/or obvious facial weakness Eye: Incomplete eye closure Mouth: Asymmetrical with maximum effort
V Severe dysfunction	Only slight, barely noticeable, movement Eye: Incomplete closure Mouth: Slight movement
VI Total paralysis	No facial function

Table 6. House-Brackmann scale.

Etiology of Bell's palsy :

The Disease may be precipitated by following conditions:

- Change in the atmospheric pressure, e.g. while flying or diving, etc.
- Malignant tumors of the parotid gland and brain
- Strokes, meningitis, head injury, multiple sclerosis and Lyme disease
- Surgical procedures in the parotid region
- Infections, e.g. acute otitis media and herpes simplex virus infection
- Melkersson-Rosenthal syndrome
- Exposure to cold
- Following incorrect pterygomandibular block anesthesia
- Ischemic damage of the facial nerve. (4)

Pathogenesis:

In most of the cases of Bell's palsy the likely cause is the activation of Herpes simplex virus (latent herpes virus and herpes zoster virus) activation. It is an inflammatory and infectious disease possibly. Maximal damage occurred in the labyrinth part of the facial canal is the nerve damage. In acute palsy of facial nerve damage herpes virus DNA is isolated by polymerase chain reaction. Compression of the labyrinth canal in the first portion of facial canal occurs in most cases. Reversible neurapraxia occurs on nerve inflammations

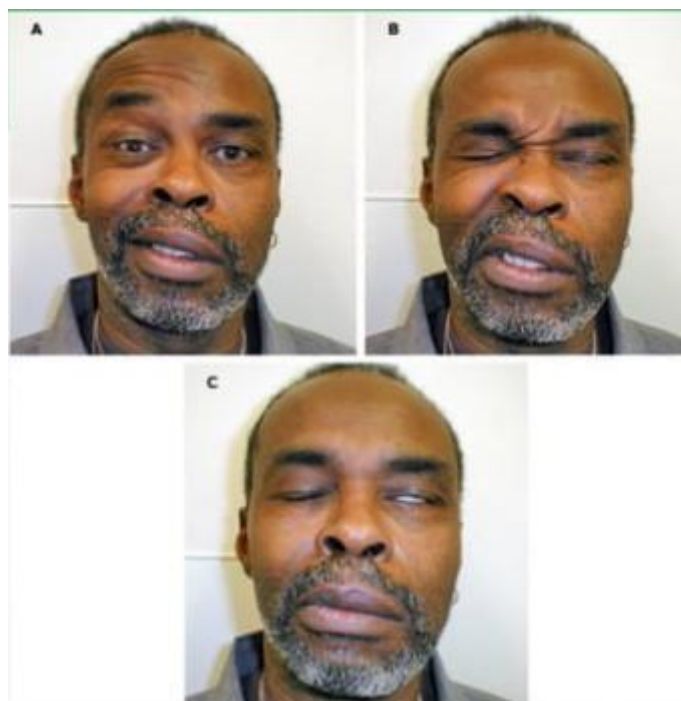
Clinical features:

Bell palsy include ipsilateral sagging of the eyebrow, drooping of the face, flat-Tening of the nasolabial fold, and inability to Fully close the eye, pucker the lips, or raise the Corner of the mouth, ipsilateral pain around the ear, hyperacusis due to disruption of nerve fibers to The stapedius muscle, changes in taste, and dry Eye from parasympathetic dysfunction. Long-term complications can include re-Sidual facial weakness facial synkinesis, facial Contracture, and facial spasm, epiphora tearing while chewing (“crocodile tears”).Postparalytic facialpalsy involves the facial movement disorder of postparalytic facial nerve syndrome,it comprises a varying degrees of zonal synkinesis, hypoactivity, and hyperactivityother focal neurologic deficits (eg, diplopia, facial anesthesia), constitutional symptoms (fever, chills, fatigue, malaise, sweats, weight loss), meningitic (headache,nuchal rigidity), and Lyme-specific symptoms (recent tick bite or exposure, erythema migrans rash, arthralgias, myalgias, low back pain), and inflammatory symptoms (eg,orofacial swelling or parotitis, uveitis.Platysmal synkinesis results in Neck discomfort and facial fatigue. Periocular synkinesis results in a narrowed palpe-Bral fissure width. Lack of meaningful smile occurs in severe cases.Gustatory epiphora (also known as BogoradSyndrome or crocodile tears) is often present(6)

Diagnosis :

In diagnosis of Bell's palsy there is no specific laboratory test to confirm. I'm majority of cases,serologic testing, electrodiagnostic studies, laboratory or imaging studies are not needed. To rule out or diagnose. Magnetic Resonance imaging (MRI) or computerized tomography (CT) is the possible ways to rule out or identity if sources of pressure on facial nerve such as tumor or skull fracture.

Laboratory testing :



Enzyme-linked immunosorbent assay or an in-in-directfluores antibody test is done in Lyme endemic regions. If the test is positive diagnosis is confirmed by Western Blot.

Imaging:

In initial case examination of Bell's palsy imaging is not needed until symptoms are shown and if the examination is atypical.Tumors like facial neuroma, cholesteatoma, haemangioma, meningioma causes facial palsy in 5%-7%of cases inspite of whether it is benign or malignant. Enhanced Computed Tomography or gadolinium-enhanced magnet-Ic resonance imaging of the internal auditory Canal and face is guaranteed for symptoms in patients which is insidious in onset that does not improve in about 3 weeks.(7)

Electrodiagnostic studies:

In evaluation of acute Bell's palsy, electrodiagnostic testing is typically not part of the evaluation. In case of complete paralysis ,electrodiagnostic testing to assess the degree of nerve injury ,chances to recover as patients with complete paralysis have high risk for incomplete recovery.(8)

Differential Diagnosis:

Misdiagnosis of bells palsy may occur. Congenital-Genetical syndromes, birth-related trauma and isolated developmental disorders (eg,developmental hypoplasia of facialmuscles). Acquired- infective (VZV, Lyme disease -rashes ,arthralgias ,Tb, HIV), traumatic (iatrogenic or head trauma), inflammatory (vasculitis, sarcoidosis, autoimmune disease), neoplastic (benign or malignant) and cerebrovascular causes. Mis diagnosis may happen by initial consulting clinician. Missed diagnoses like tumours (eg, facial nerve schwannoma, parotid malignancy and, rarely, acoustic neuroma), herpes zoster eruption in ear canal or pharynx, sarcoidosis and granulomatosis with polyangiitis(Wegener'sgranulomatosis). (9)Refer to tabular column (10)

Differential diagnosis of Bell palsy		
Differential diagnosis	Cause	Distinguishing characteristics
Central nervous system lesion	Stroke, space-occupying lesion	Forehead sparing, headache, limb weakness, multiple neurologic signs
Autoimmune diseases	Guillain-Barré syndrome Multiple sclerosis	Ascending weakness, absent reflexes Upper motor neuron signs, abnormal cerebrospinal fluid
Metabolic diseases	Diabetes	Elevated blood glucose
Infectious diseases		
Meningitis, encephalitis	Viral, bacterial, fungal pathogen	Headache, fever, meningeal signs, abnormal cerebrospinal fluid
Herpes simplex	Reactivation of herpes simplex virus type 1 from geniculate ganglion	Fever, malaise
Lyme disease	<i>Borrelia burgdorferi</i>	Rash, arthralgia, malaise, bilateral facial palsy
Ramsay Hunt syndrome	Varicella zoster	Pain, vesicular eruption
Granulomatous disease	Sarcoidosis	Bilateral facial palsy, elevated angiotensin-converting enzyme
Neoplasm	Parotid tumor, facial nerve tumor, metastasis	Insidious onset, palpable mass, partial involvement of facial nerve branches

TREATMENT :

The treatment of Bell palsy concentrate on increasing recovery and reduce associated complications.

Protect the eyes :

Patients who cannot completely close their eyes , ocular protective care should be given to prevent exposure keratopathy. Frequent application of lubricant eyedrops with artificial tears during the day or ophthalmic ointment at bedtime is recommended.

Eye patching or taping at night may be used. Patients with loss of vision or eye irritation should be referred to an ophthalmologist.(11)

Patients with diabetes, pre-existing eye disease, complete facial palsy having no response on neurophysiology and patient will suffer from ongoing irritation despite the use of the eye protective therapies. (12)

Oral care :

Loss of the sphincter function of the orbicularis oris social inconvenience of oral incontinence and predisposes the lip and inner cheek to abrasion during mastication and subsequent ulceration. Strategic eating may lessen the impact of the setting of flaccid facial paralysis. Using a straw for liquids soft foods are often helpful. The inability to lower and evert the lower lip excludes eating certain foods. Temporary dental 'spacers' adhered to the lateral aspect of the molar teeth may be used to prevent chewing of the buccal mucosa.

Physiotherapy:

Physiotherapy treatment, which broadly encompasses heat therapy, electrostimulation, massage,mimeta plethora of treatment regimes, and their timing and variability in implementation make their broader assessment of utility complex. Although not recommended for all suffers of Bell's palsy.(11)These include patients who have incomplete recovery,hypertonia, or synkinesis,and in these groups neuromuscular retraining is trailed before consideration of chemodenervation.(13)Physiotherapy and chemodenervation are complementary to this treatment.

Antiviral therapy may offer modest benefit:

Antiviral therapy has not been beneficial in Bell palsy,(11)However, an antiviral combined with a corticosteroid may offer modest benefit if started within 72 hours of symptom onset Antiviral therapy may offer modest beneficial if started within 72 hours of symptom onset (level C evidence, ie, possibly effective).(14) Patients starting antiviral therapy should understand that its benefit has not been established.

Surgical decompression remains controversial :

Surgery should be considered only for patients with complete paralysis with a greater than 90% reduction in motor amplitude on a nerve conduction study compared with the unaffected side, and absent volitional activity on needle examination.(11,15)

Acupuncture::

No recommendation Currently, there is no recommendation for acupuncture in the treatment of Bell palsy.(11) A recent clinical trial recommend benefit from acupuncture combined with corticosteroids,(16) but high-quality studies to support its use are lacking.

Bell palsy treatment recommendations for adults presenting within 72 hours		
Class of medication	Recommendation grade	Examples
Corticosteroids	A (established as effective)	Prednisone 50 mg orally daily for 5 days, followed by 10 mg less each day for 5 days Prednisolone 50 mg orally daily for 10 days
Antivirals^a	C (possibly effective)	Valcyclovir 1 g three times daily for 7 days ^b Acyclovir 400 mg five times daily for 7 days ^b

^a In combination with corticosteroids for moderate to severe weakness.
^b Dose should be adjusted for patients with impaired renal clearance.

Based on American Academy of Neurology guidelines, Gronseth GS, Paduga R; American Academy of Neurology. Evidence-based guideline update: steroids and antivirals for Bell palsy: report of the Guideline Development Subcommittee of the American Academy of Neurology. Neurology 2012; 79:2209–2213.

Prognosis:

The severity of bells palsy varies mild to severe, but the prognosis is good. Majority of BP patient will recover within 3 weeks and nearly all patients will recover within five weeks. In BP patient 100% of patients achieved some degree of muscular recovery, and 71% achieved complete recovery.(17)

The severity and recovery of bells palsy was associated with patient's age. Among patients who had incomplete palsy, 94% recovered fully, compared with 61% of patients who had complete palsy.

Based on severity of disease recovery will takes place: Incomplete palsy takes two months to recover, For complete palsy three to Five months. No patients who had residual deficits after six months achieved complete recovery. Better diagnosis results early recovery of bells palsy later recovery associated with aberrant regeneration. Young.aged patient(5 to 14 years) were found to have the most favorable prognosis, with 90% achieving full recovery. Recovery rate decreases with aged person , only about one-third of patients above the age of 60 years regaining normal function.(17)

II. Conclusion:

Bell's palsy is favourable in outcome even without treatment, but improvement is significantly increased in case of treatment with corticosteroids. Features of history, neurologic examination, or head and neck examination suggest a specific or alternative cause if the characters are spontaneous acute onset of unilateral peripheral facial paresis or palsy in isolation.(18)

Reference:

- [1]. Anil K Tripathi, Kamal K Sawlani. Essential Of Medicine For Dental Students,4thedition.
- [2]. Mower S.Bell's Palsy: Excluding Serious Illness In Urgent And Emergency Care Setting. Emerg Nurse.2017 Apr 13;25(1):32-39(Pubmed).
- [3]. Grzybowski A, Kaufman MH. Sir Charles Bell (1774-1842): Contributions To Neuro-Ophthalmology. Acta Ophthalmol Scand 2007; 85:897-901
- [4]. Swapan Kumar Purkait. Essential Of Oral Pathology, 4th Edition;2019
- [5]. Peitersen E. Bell's Palsy: The Spontaneous Course Of 2,500 Peripheral Facial Nerve Palsies Of Different Etiologies. Acta Otolaryngol Suppl 2002; 549:4-30
- [6]. Boahene DO, Olsen KD, Driscoll C, Lewis JE, McDonald TJ. Facial Nerve Paralysis Secondary To Occult Malignant Neoplasms. Otolaryngol Head Neck Surg 2004;130:459-465.

- [7]. Hohman MH, Hadlock TA. Etiology, Diagnosis, And Management Of Facial Palsy: 2000 Patients At A Facial Nerve Center. *Laryngoscope* 2014; 124:E283–E293.7. Baugh RF, Basura GJ, Ishii LE, Et Al. Clinical Practice Guideline: Bell's Palsy *Otolaryngol Head Neck Surg* 2013; 149(Suppl 3):S1–S27
- [8]. Baugh RF, Basura GJ, Ishii LE, Et Al. Clinical Practice Guideline: Bell's Palsy *Otolaryngol Head Neck Surg* 2013; 149(Suppl 3):S1–S27
- [9]. Crosson G, Coulson SE, Mukherjee P. Mistaken Diagnoses In Facial Nerve Disorders [conference Presentation]. 12th International Facial Nerve Symposium. Boston: 7 June 2013.
- [10]. DONIKA K. PATEL, Division Of Neurology, Lebauer Healthcare, Cone Health Medical Group, Greensboro, NCKERRY H. LEVIN, M.D., Chairman, Department Of Neurology; Director, Neuromuscular Center, Neurological Institute, Cleveland Clinic; Professor, Cleveland Clinic Lerner College Of Medicine Of Case Western Reserve University, Cleveland, OH
- [11]. Baugh RF, Basura GJ, Ishii LE, Et Al. Clinical Practice Guideline: Bell's Palsy. *Otolaryngol Head Neck Surg* 2013; 149(Suppl 3):S1–S27
- [12]. Hohman MH, Hadlock TA. Etiology, Diagnosis, And Management Of Facial Palsy: 2000 Patients At A Facial Nerve Center. *Laryngoscope* 2014; 124:E283–93.
- [13]. Hadlock TA, Greenfield LJ, Wernick-Robinson M, Et Al. Multimodality Approach To Management Of The Paralyzed Face. *Laryngoscope* 2006; 116:13859
- [14]. Gronseth GS, Paduga R; American Academy Of Neurology. Evidence-based Guideline Update: Steroids And Antivirals For Bell Palsy: Report Of The Guideline Development Subcommittee Of The American Academy Of Neurology. *Neurology* 2012; 79:2209–2213.
- [15]. Gantz BJ, Rubinstein JT, Gidley P, Woodworth GG. Surgical Management Of Bell's Palsy. *Laryngoscope* 1999; 109:1177–1188.
- [16]. Xu SB, Huang B, Zhang CY, Et Al. Effectiveness Of Strengthened Stimulation During Acupuncture For The Treatment Of Bell Palsy: A Randomized Controlled Trial. *CMAJ* 2013; 185:473–479.
- [17]. Pietersen E. *Acta Otolaryngol Suppl.* 2002; (549):4-30.
- [18]. Yetiser S, Kazkayas M, Altinok D, Karadeniz Y. Magnetic Resonance Imaging Of The Intratemporal Facial Nerve In Idiopathic Peripheral Facial Palsy. *Clin Imaging* 2003