

## A Case Study Of Sickle Cell Trait Presenting As Avascular Necrosis Of Femur.

Dr. Jyotika Chauhan<sup>1</sup>, Dr. Aashi Agarwal<sup>2</sup>, Dr. N.K Gupta<sup>3</sup>, Dr. Shuchi Goyal\*

<sup>1</sup>Resident, <sup>2</sup>Resident, <sup>3</sup>Professor And Hod Department Of General Medicine, Pims, Udaipur, \*Professor And Hod Department Of Biochemistry, Rnt Medical College, Udaipur.

### ABSTRACT:

Sickle cell disease(SCD) is a genetic condition of the hemoglobin synthesis inherited as an autosomal recessive trait, whose prevalence can vary from 5 to 25% in the different parts of the world. It is characterised by the presence of abnormal hemoglobin HbS instead of hemoglobin A. Patients suffering from major forms of SCD present the risk of developing epiphyseal necrosis. Aseptic osteonecrosis of the femoral head (AOFH) caused by ischemia, or bone infarction can affect between 20 and 50% of SCD patients. AOFH have been diagnosed at an early radiological stage in young adults whose average age varies, between 27-36 years. It is estimated that approx. 25-30 % of SCD patients will undergo total hip arthroplasty before 50 years. Gynecological challenges faced by adolescent girls are delayed puberty (late onset menarche), vaso-occlusive pain associated with their menstrual cycle and underdiagnosed abnormal uterine bleeding.

**KEYWORD:** Osteonecrosis, Sickle cell disease, Total hip arthroplasty, abnormal uterine bleeding.

Date of Submission: 12-01-2024

Date of Acceptance: 22-01-2024

### I. INTRODUCTION:

Sickle cell disease(SCD) is an important group of autosomal recessive hereditary disorders of hemoglobin characterised by production of defective hemoglobin synthesis called Sickle Hemoglobin (HbS). HbS imparts sickle shape to red cells on low oxygen tension or deoxygenation. The major entities included are: Sickle Cell Anemia(SS) - is a homozygous state in which both beta globin chains are abnormal.

Sickle cell trait(AS) - It is a heterozygous state in which one gene is defective for HbS (abnormal) while the other gene is for HbA (normal).

Compound heterozygous is characterised by both the beta globin chains having different abnormalities(eg. HbSC, HbS beta thalassemia).

Avascular necrosis of femoral head is a type of osteonecrosis due to disruption of blood supply to the proximal femur. It can occur due to causes like traumatic or atraumatic in origin. These causes include fractures, dislocations, chronic steroid use, chronic alcohol use, coagulopathy, congenital causes and many other.

Patient with sickle cell disease have shorter menstrual cycles than normal females. Their periods lasts longer and are heavier, and they have a greater incidence of dysmenorrhea.

### II. CASE REPORT:

A 37 year old female patient came to the opd with chief complaint of: heavy menstrual bleeding x 1month, white discharge x 1 month, lower abdomen pain x 3 month.

Patient had irregular cycle of 10-15 days associated with dysmenorrhea and presence of clots during cycle.Hysterectomy was done and after hysterectomy bleeding spot seen for 5-7 days. Patient was readmitted again for per vagina bleeding with clots. Patient had anemia for which 2 unit blood transfusion was done. Post coital bleeding/spotting was present. Vaginal discharge from last 1 month which was curdy white discharge with foul smell associated with itching with c/o burning micturition. At the time of admission patient Hb was 7.3 gm%. After 3 blood transfusion Hb was 12.6 gm%. Total Laproscopic Hysterectomy was done in past. Postoperative Hb was 11.1 gm%. Patient had H/O Total Hip Replacement of left side 9yrs back in 2014. Patient was admitted with the complaint of weakness in Left leg since 1 yr. H/O 3 unit blood transfusion in 2014 before surgery and 2 unit blood transfusion after surgery was done. No H/O allergy from any medication. No H/O Hypertension, Diabetes Mellitus, Asthma, Tuberculosis, Thyroid. Age of Menarche is 12yr, 2-3 days duration with 3-4 pads/day, clots present in between. 25-28 days menstrual cycle, irregular, dysmenorrhea present. P4L4: FTND(Home Delivery). All children are alive and healthy. (H/O hospital stay during last pregnancy due to anemia, 4-5 bottles of IV Iron Sucrose given.) During this pregnancy patient femur necrosis started. Diet is nonvegetarian, decreased appetite, bowel /bladder habits are regular, h/o weight loss, tobacco chewing left 2yrs back. No family H/O Sickle

A Case Study Of Sickle Cell Trait Presenting As Avascular Necrosis Of Femur.

Cell Anemia , Blood transfusion, Trauma, Tuberculosis, Diabetes Mellitus, Hypertension, Asthma, Thyroid in family.

**Investigation:**

Serum Ferritin- 939.0 ng/ML (13-290)

Pap smear- Benign cervical smears(Inflammatory smears).

USG Whole Abdomen- Small well defined echogenic papilla arising from left bladder wall measuring approx. 8x3.5mm.

CT SCAN- hepatomegaly with size approx. 17.8cm.

Splenomegaly with size approx. 15cm.

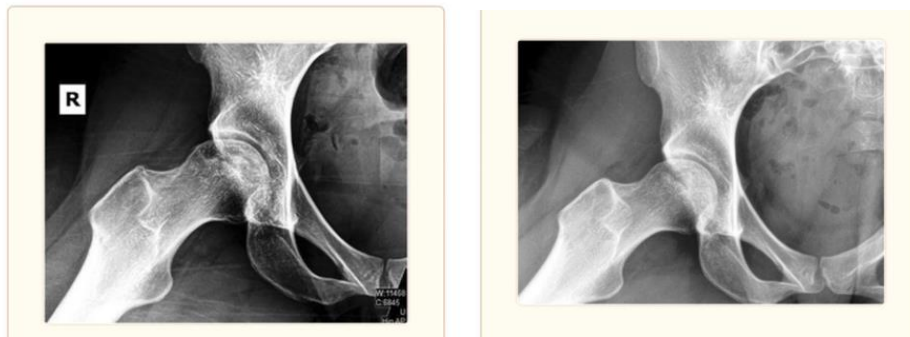
Generalised increased bone density is seen S/O fluorosis.

THR Implant in right hip joint.

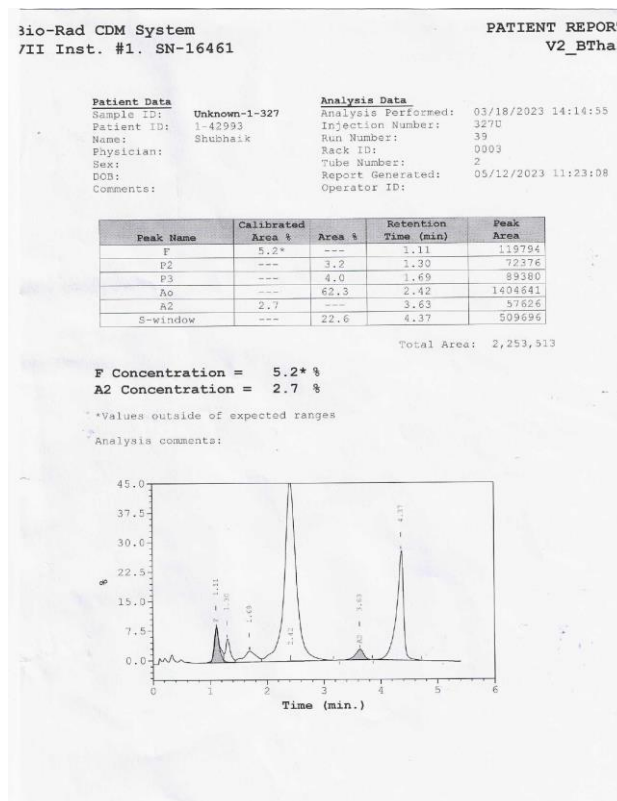
Changes of AVN with femur head collapse.

PBF: RBC- Microcytic hypochromic red blood cells with moderate anisopoikilocytosis, tear drop cells, pencil cells and normocyte seen. WBC- Count toward lower side of normal limit with normal morphology. Platelet- Adequate in number.

Hb Electrophoresis: Hb-S Heterozygous condition.



AP view of the right femoral head shows areas of hyperlucency and surrounding sclerosis, as well subtle changes in the shape of the articular surface. The necrosis also spreads into the acetabulum.



### **III. DISCUSSION:**

Sickle Cell Anemia is a homozygous form of HbS(HbSS). This result from single point replacement of glutamine by valine at position 6 of beta globin chain. Under low oxygen conditions, the absence of a polar amino acid at position 6 of the beta globin chain promotes the non-covalent polymerisation of hemoglobin, which distorts red blood cells into a sickle shape and decreases their elasticity. As a consequence, these rigid blood cells are unable to deform as they pass through narrow capillaries, leading to vessel occlusion and Ischemia. Proper and adequate counselling should be given to intending couple before marriage and hemoglobin genetic counselling and education should be included in the curriculum of students from primary to tertiary education levels to avert the crisis associated with the sickle cell anemia. Patient was started on Hydroxyurea, a myelosuppressive agent. It raises the level of HbF and the haemoglobin level.

### **REFERENCE**

- [1]. Rees Dc, Williams Tn, Gladwin Mt. Sickle-Cell Disease. *Lancet*. 2010;376:2018–31.
- [2]. Booth C, Inusa B, Obaro Sk. Infection In Sickle Cell Disease: A Review. *Int J Infect Dis*. 2010;14:E2–E12.
- [3]. Royal College Of Obstetricians And Gynaecologists. Management Of Sickle Cell Disease In Pregnancy. Green-Top Guideline No. 61. 2011. [Cited 2021 Jul 8]
- [4]. Desai Dv, Hiren D; Sickle Cell Disease. History And Origin. *The Internet Journal Of Hematology*, 2004; 1(2).
- [5]. Kumar S, Powars D, Haywood Ij; Anxiety, Self Concept And Personal And Social Adjustment In Childern With Sickle Cell Anemia *J.Pediatr*,1976;88: 859.
- [6]. Platt Os, Orkin Sh, Dover G, Beardsley Gp, Miller B, Nathan Dg. Hydroxyurea Enhances Fetal Hemoglobin Production In Sickle Cell Anemia. *J Clin Invest*. 1984 Aug;74(2):652-6.
- [7]. Steinberg Mh, Sebastiani P. Genetic Modifiers Of Sickle Cell Disease. *Am J Hematol*. 2012 Aug;87(8):795-803.
- [8]. Naoum Pc. Sickle Cell Disease: From The Beginning Until It Was Recognized As A Public Health Disease. *Rev Bras Hematol Hemoter*. 2011;33(1):7-9.