

A Case Study Dipicting Various ThromboticAccidents In Peripartum Period

1st Author -Dr.Hari Anupama

2nd Author-Dr.Renu Sahani

3rd and corresponding Author-Dr.P Lakshmi Tejeswini

Mallareddy Medical College For Women Hyderabad

Date of Submission: 20-01-2024

Date of Acceptance: 30-01-2024

I. INTRODUCTION

Pregnancy is a thrombogenic hypercoagulable state wherein the three components of Virchow's triad are active simultaneously

- Stasis of blood
- Damage to vascular endothelium
- Changes in coagulants and anticoagulants.

Anticoagulant regimens

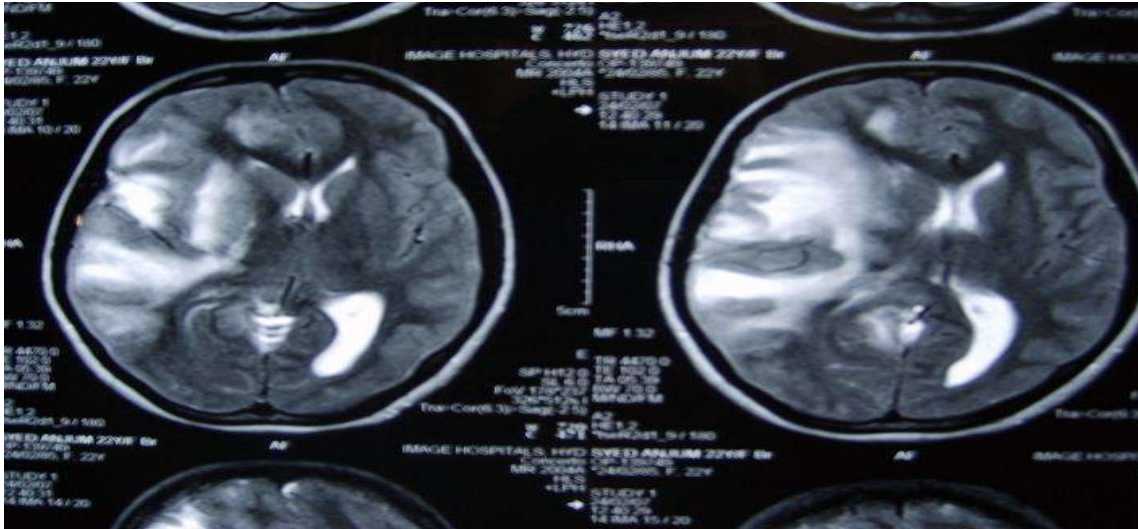Name of the drug	Dosage	Monitoring
Prophylactic LMWH	Enoxaparin 40 mg s.c once a day	Anti Xa levels of 0.1-0.2 U/ml 4 hrs after injection
Therapeutic LMWH	Enoxaparin 1 mg/kg/12 hrly	Anti Xa levels 0.6-1.0 U/ml tested after 4 hrs
Prophylactic UFH	1 st trimester-5000 to 7500 U/12 hr subcutaneously 2 nd trimester-7500 to 10000 U/12 hr subcutaneously 3 rd trimester-10000 U/12 hrly	aPTT should be in normal range Heparin levels of 0.1-0.2 U/ml
Therapeutic UFH	10000 U or more every 12 hrly subcutaneously	aPTT level should be 1.5-2.5 times more than the control measured 6 hrs after injection
Warfarin(postpartum period) only therapeutic	Start with 5-10 mg/day orally, dose can be adjusted according to INR target.(target INR is 2-3)	Overlap UFH or LMWH until INR is >2 for more than 2 days

II. Methodology

- Case series
- Study conducted in obstetrics and gynecology department- Mallareddy medical college for women
- Time duration - 4 years period
- A 25 yr old Mrs S was admitted in view of bad obstetric history with married life of 7yrs with 4months amenorrhoea. She was gravida 8 with previous seven first- trimester abortions. Last abortion was one and half years ago.
- There was no history of consanguinity, nor there were any genetic disorders in the family.
- She was thoroughly investigated. The renal function and hepatic function were normal. Hemoglobin was 10.4 Gm/dl. Viral serology was negative.. Blood group was B +ve.
- An obstetric ultrasound showed a life fetus of 16 weeks gestation.
- The antiphospholipid antibodies were positive at IgG- 14 GPL units (<10 negative) IgM- 22 MPL units (>12 positive) IgA – 7 APL units (<15 negative).
- She was advised low molecular heparin therapy but she did not consent and was lost to follow up. One month later she presented with headache and left hemiparesis of three days duration.
- The MRI brain scan was suggestive of venous infarct with pressure effect. There was further deterioration of

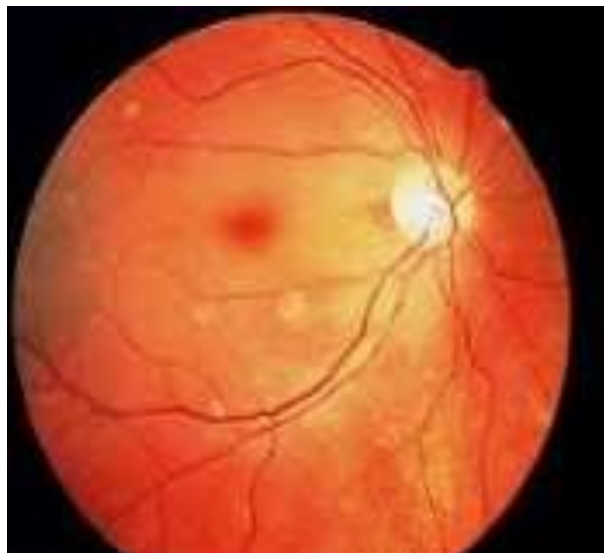
sensorium, she was operated and left temporoparietal decompressive craniectomy was performed.

- As she recovered she was put on low molecular heparin till term.
- Elective cesarean was done one month before due date and a healthy male child was delivered.
- T2 weighted cranial MRI showing venous infarct in right cerebral hemisphere, mass effect and midline shift



III. Bilateral retinal artery thrombosis in severe preeclampsia

- A 23 years aged female patient, primigravida referred from a community hospital in view of severe pre-eclampsia for safe confinement
- At the time of admission, her BP was 210/130mmHg. Urine proteins 3+. HerBMI was 33.
- She complained of diminished vision which progressed to complete blindness
- The patient was immediately put on Pritchard regimen of Magnesium sulfate and intravenous labetalol.
- The ophthalmologist found bilateral retinal artery thrombosis and papilloedema of both eyes on fundoscopic examination. and was diagnosed as bilateral retinal artery thrombosis
- Since it was term pregnancy, induction of labour was done on the same day and she delivered a live male child of 2.2 kg.
- After 6 hours of delivery the patient was kept on heparin subcutaneously for 1 week.
- Patient was on Acitrom (acenocoumorol) for 2 months.
- Patient was regularly followed on monthly basis but had only partial regain of vision.
- Central retinal artery thrombosis resulting in cherry red spot

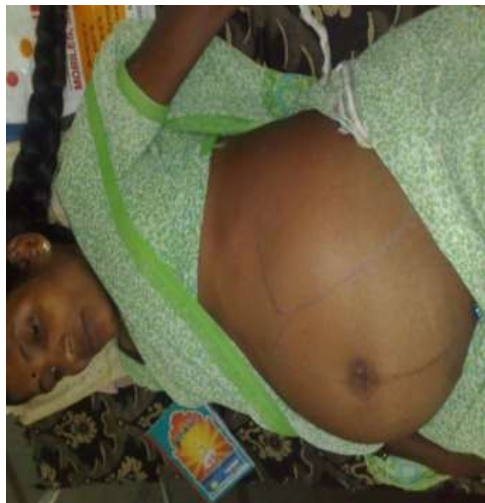
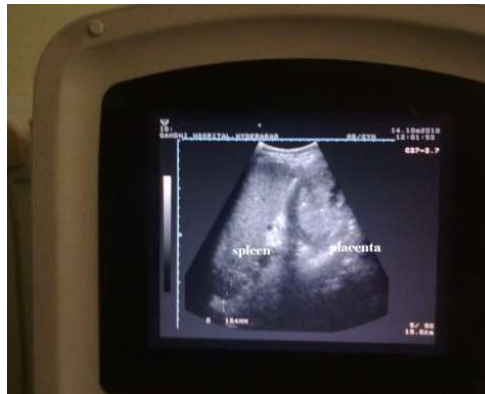
IV. Splenic vein thrombosis

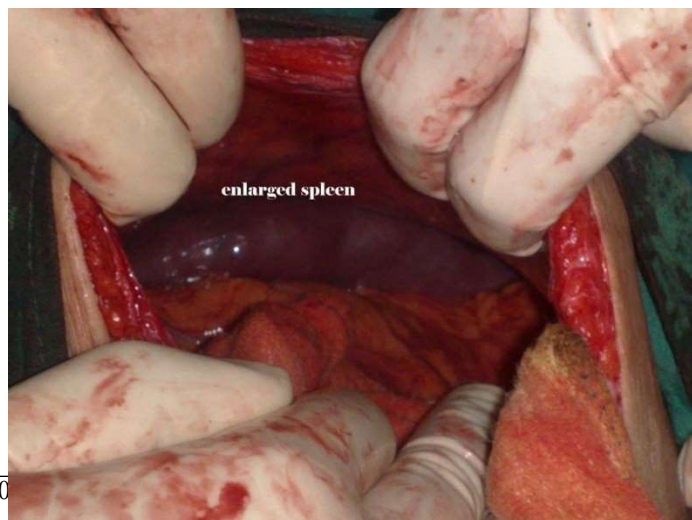
- A 28 years old gravida 4 with 1 live child and 2 miscarriages (at first trimester) came to the hospital with severe abdominal pain of 2 days duration.
- On examination she was found to be a case of severe form of preeclampsia.

A Case Study Depicting Various Thrombotic Accidents In Peripartum Period

- Her uterus was of 34 weeks of gestation with presence of fetal heart. Lefthypochondrial tender mass was palpable suggestive of splenomegaly .
- Ultrasound examination revealed a single live fetus of 34 weeks besides splenomegaly and there were no signs of placental abruption.
- Splenic vein doppler showed thrombosis of the vein.
- As the patient went in severe hypotension and severe pain, an emergency LSCS was done.
- Baby was alive and kept in NICU. In the same setting, splenectomy was done as the spleen was congested and gangrenous.
- The patient was followed up post operatively and recovered well
- Gravid uterus with tender, enlarged spleen due to splenic vein thrombosis Antenatal scan showing enlarged spleen and gravid uterus



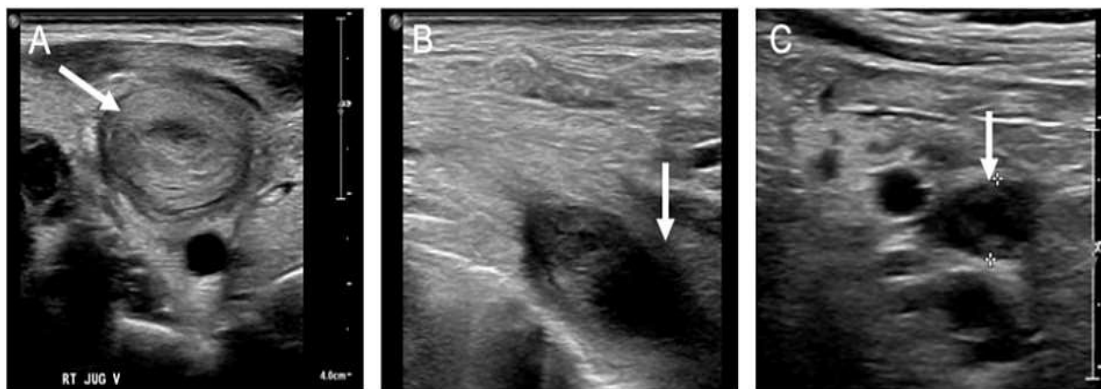
Intra-operative finding of enlarged, congested and gangrenous spleen



V. Subclavian Venous Thrombosis

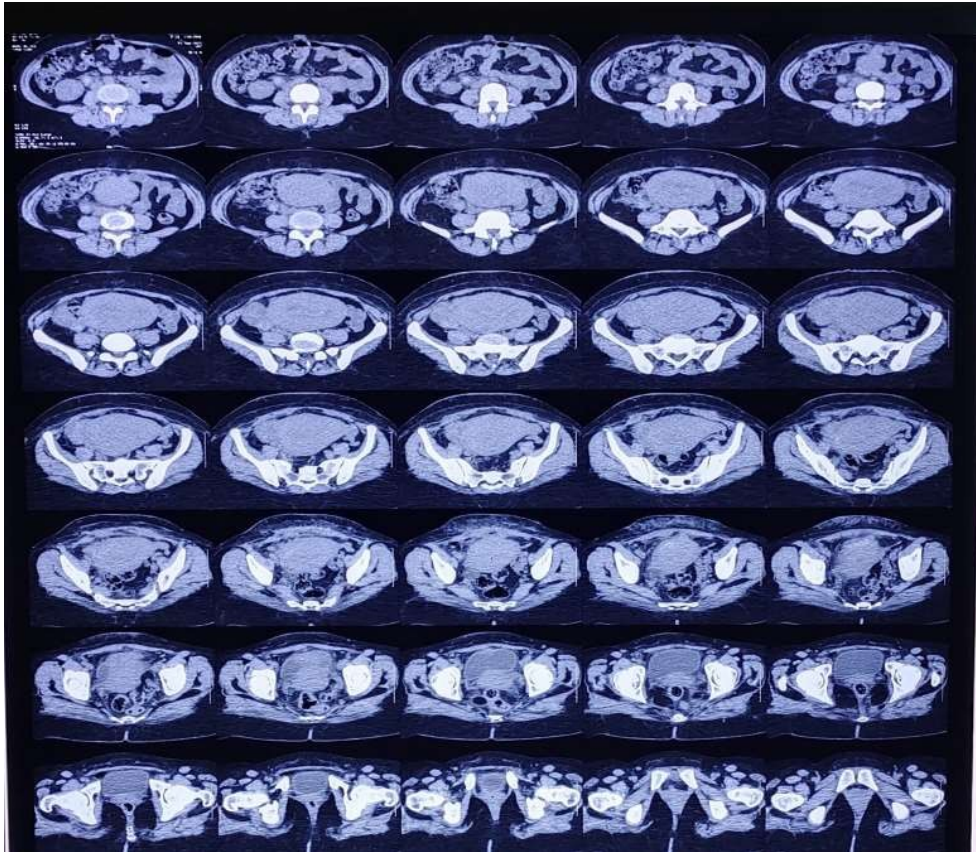
- Mrs.P underwent a repeat cesarean operation. At the time of admission, pre operatively her serological investigations along with coagulation profile were normal.
- Intra operatively she had severe post partum hemorrhage, controlled with whole blood transfusion.
- **3**
- Platelet count decreased to 30,000/mm³, four units of random donor platelets were also transfused.
- Patient completely recovered from hemorrhagic shock.
- On the second post operative day, tachycardia at 160 beats per minute, mild right upper extremity swelling, and tenderness on palpation.
- A small mass was appreciated over the right thyroid along with right neck swelling with no overlying skin changes or cervical lymphadenopathy.
- Initial sonographic study revealed diffuse right internal jugular, axillary, basilic, brachial, and subclavian vein thrombosis.
- On further evaluation, the D-dimer value was 665 ng/ml
- 2D echocardiography was normal including the right atrium.
- A diagnosis of Right subclavian venous thrombosis was made.
- 60 mg of LMWH was started twice daily.
- **th**
- After 11 post operative day repeat Doppler study revealed an improvement of flow on right side.
- Patient was put on 2 mg of acitrom per day and followed monthly with appropriate dietary instructions and monitoring of INR.
- In this case obstetric hemorrhage leading to thrombotic thrombocytopenia could be one important factor leading to thrombotic episode.

Intraluminal echogenicity indicating thrombus (white arrow) in the right internal jugular vein (A), subclavian (B), and axillary (C).



VI. Ovarian vein thrombosis

- Unbooked 31-year-old G2P1L1 underwent emergency lscs i/v/o prev lscs in with scar tenderness.
- K/c/o Hypothyroid on 50 mcg levothyroxine and GDM on metformin.
- On POD 4 of cesarean section she complained of diffuse abdominal pain.
- Her abdomen was very distended with pain on superficial and deep palpation in all quadrants and missing bowel sounds.
- Pelvic examination showed an involuted uterus below the umbilical line.
- There was no evidence of deep vein thrombosis in the lower extremities.
- Laboratory exams revealed elevated white blood cell count (19000 cells/mm³) with neutrophilia and elevated C reactive protein.
- On POD 5 patient had severe pain abdomen with vomitings and high fever spikes.
- Usg abdomen done and revealed –
- Linear retroperitoneal tubular structure noted extending from the right ovary to the right renal vein region with no vascularity on the color flow - likely thrombosed right ovarian vein. The tubular structure is seen right anterolateral to the IVC.
- Patient was started on higher antibiotics and Inj. Clexane 80mg BD.
- Patient was advised to continue enoxaparin for 2 months and review.



On pod 12 patient was comfortable and discharged after Usg abdomen and pelvis done showed -:

- Thin endometrial fluid measuring 4.5 mm noted.
- Linear retroperitoneal mildly echogenic tubular structure noted extending from the right ovary to the right renal vein region with no vascularity on the color flow - likely thrombosed right ovarian vein. No obvious color flow noted within the vein - likely complete thrombosis. No extension of the thrombus into the IVC at present scan.
- There is complete resolution of the IVC thrombus noted.
- Right ovary is enlarged in size with mildly heterogenous echotexture.

VII.

CONCLUSION

- Pregnancy, preeclampsia, APLA Obesity and cesarean section increase the risk of DVT.
- Unsupervised antenatal patients can pose a challenge as they might present in an emergency with life threatening complications.
- Early detection and prevention will help us in preventing maternal morbidity and mortality.

REFERENCES

1. Christian Mp And Charles JI – Thromboembolic Disorders In Pregnancy. Obstetrics- Normal And Problem Pregnancies 7 Ed, Elsevier 2017; 965-977.
2. Creanga Aa, Berg Cj, Syverson C, Seed K, Bruce C, And Callaghan Wm - Pregnancy-Related Mortality In The United States. *Obstet Gynecol.* 2015; 125:5-12.
3. Acog Committee Opinion. Number 299, September 2004 (Replaces No. 158, September 1995). Guidelines For Diagnostic Imaging During Pregnancy. *Obstet Gynecol.* 2004;104 (3):647-651.
4. American College Of Obstetricians And Gynecologists Committee Opinion: Anticoagulation With Low Molecular Weight Heparin During Pregnancy. Number 211, November 1998.
5. E Schapkaitz, B F Jacobson, P Manga, R S Chitsike, E Benade, S Jackson, S Haas, H R Buller - On Behalf Of The South African Society Of Thrombosis And Hemostasis - Recommendations For The Anticoagulation Of Pregnant Patients With Mechanical Heart Valves OnBehalf Of The South African Society Of Thrombosis And Haemostasis *Samj* 2015; 105(9):733- 738.
6. De Stefano V, Martinelli I, Rossi E, Batterglioli T, Za T, Mannuccio Mannucci P And Leone G -The Risk Of Recur- Rent Venous Thromboembolism In Pregnancy And Puerperium Without Antithrombotic Prophylaxis. *Br J Haematol.*2006;135:386-391.