

An Ectopic Maxillary Central Incisor Causing Nasal Obstruction: A Rare Case Report

Dr. Shabina Jasmine. C, Dr. Roshnni. A, Dr. Anu Jose

Junior Resident, Department Of Oral And Maxillofacial Surgery, M.E.S Dental College, Kerala, India

Professor, Department Of Oral And Maxillofacial Surgery, M.E.S Dental College, Kerala, India.

Assistant Professor, Department Of Oral And Maxillofacial Surgery, M.E.S Dental College, Kerala, India.

Abstract:

Surgical removal of impacted teeth in the nasal floor poses a unique challenge due to their close proximity to vital structures. This case report describes the successful surgical removal of an impacted maxillary incisor from the nasal floor using a transoral approach. An 18-year-old male presented with missing right maxillary central incisor. Imaging studies revealed an obliquely impacted maxillary right central incisor crown appears to be placed labially in relation to upper right central incisor region extending beyond the floor of nasal cavity. The surgical procedure involved a transoral approach to access and remove the impacted maxillary incisor from the nasal floor. Intraoperative findings, technique, and postoperative care are detailed in the case report.

Keywords: Impacted maxillary central incisor, nasal floor, nasopalatine canal proximity, intraoral approach.

Date of Submission: 12-12-2024

Date of Acceptance: 22-12-2024

I. Introduction

The impaction of maxillary central incisors significantly affects both the dental and facial aesthetics of a person [1]. Properly aligned anterior teeth contribute a confident smile and boost self-esteem, which is particularly important during adolescence. Impaction of the maxillary central incisor is a rare occurrence, with only a few reported cases of 0.06-0.2%.[2] The order of frequency of impacted teeth typically includes the mandibular third molar, maxillary third molar, maxillary cuspid, mandibular cuspid, mandibular premolar, maxillary premolar, and lastly, the maxillary central and lateral incisors [1].

Teeth have been located in various atypical locations such as the ovaries, testes, anterior mediastinum, and presacral regions, as well as within the maxillofacial region including the maxillary sinus, mandibular condyle, coronoid process, chin, nose, and even the orbit[10]. In cases of an ectopic tooth located in the nasal cavity, extraction typically involves a minor surgical procedure. However, challenges may arise when dealing with a tooth deeply embedded in a bony socket within the nasal floor[7]. In addition to the usual impediments associated with the impacted tooth, there will be nose related complications while surgically retrieving the tooth from nasal floor like nasal obstruction, sinusitis, pain and discomfort due to impingement on nasopalatine nerve, damage or displacement to adjacent teeth, development of cysts or tumors, perforation of the nasal septum, abscess of the nasal septum[4]. Management of impacted maxillary anteriors can be done surgically or orthodontically and by both. The purpose of this case study is to emphasize the surgical management of an unusual impaction.

II. Case Report

A healthy 18 year-old male patient reported to our Department of Oral and Maxillofacial surgery with a chief complaint of missing upper right front tooth. There was history of nasal congestion with no history of any pain, swelling, paresthesia or epistaxis. On intraoral examination, the right permanent central incisor was missing with no bulge in the labial and palatal aspect (Fig1). On palpation, a hard tooth like mass was felt on the superior most aspect of labial vestibule with respect to 12.

A panoramic radiograph revealed an opacity above the root of 12 (Fig 2).

Cone beam computed tomography (CBCT) confirmed the presence of obliquely impacted maxillary right central incisor apical to 12 in the nasal floor with breach in the floor of nasal cavity and proximity of nasopalatine canal. Crown appears to be placed labially in relation to 11 region extending beyond the labial cortical plate and floor of nasal cavity (Fig 3).

Surgical removal of impacted tooth was planned under General anesthesia after obtaining opinion from Department of Orthodontics for extraction.

After induction of General Anesthesia, patient aseptically painted and draped. 2% lignocaine with 1:200000 adrenaline injection given along the proposed incision site. Vestibular incision was placed from 13 to 21 region and full thickness mucoperiosteal flap was raised labially and incisal third of crown exposed in the nasal floor (Fig 4a). Nasal mucosa carefully separated from maxillary bone using periosteal elevator and protected with Howarth's elevator to prevent tear during the procedure. Bone guttering was done around the tooth (distally and inferiorly).

Complete tooth structure removed by using Cryer elevator without injuring the nasal floor (Fig 4b&c). Hemostasis is achieved and irrigated with betadine and saline. Closure was done using absorbable sutures (3-0 Vicryl)(Fig 4d). Postoperatively the patient was given oral antibiotics and analgesics.

Clinical follow up was done at 1 week and 1 month. There was no evidence of any complications and patient reports symptomatic improvement.

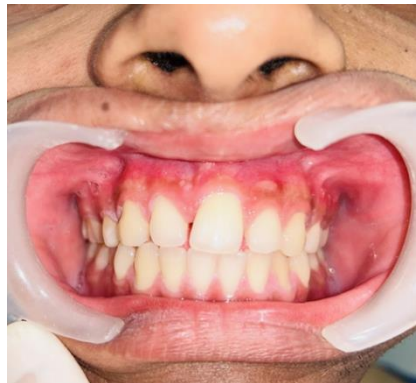

Figure 1: Missing permanent right central incisor

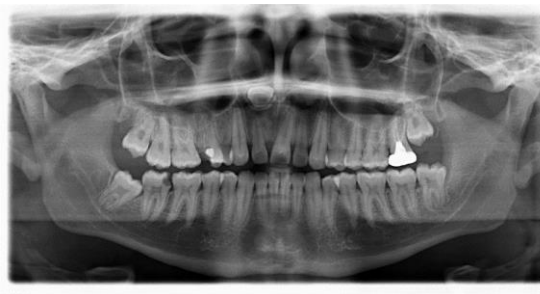

Figure 2: Panoramic radiograph revealed an opacity above the root of 12

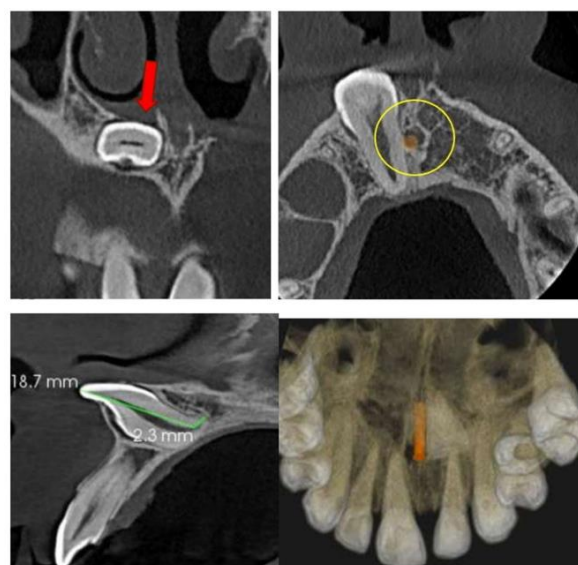


Figure 3: CBCT shows breach in the floor of nasal cavity and proximity of naso-palatine canal and Crown appears to be placed labially in relation to 11 region extending beyond the labial cortical plate and floor of nasal cavity

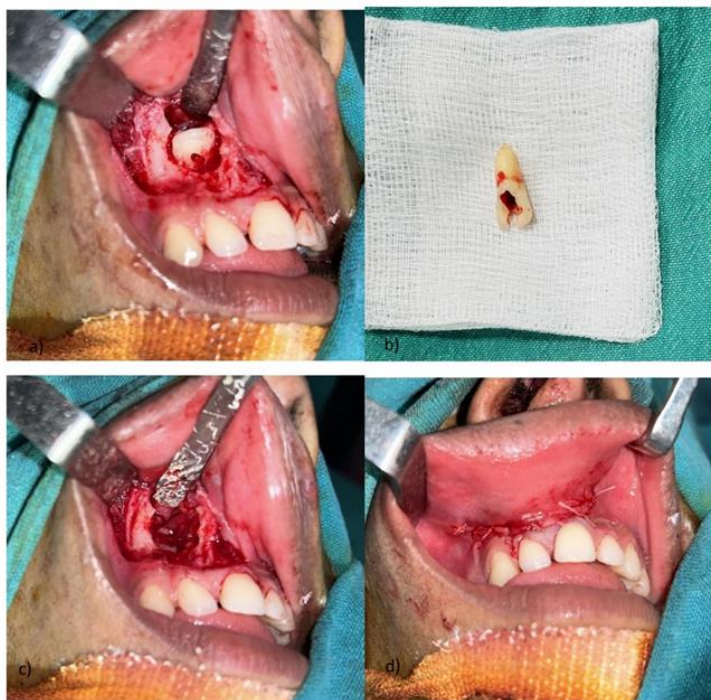


Figure 4: a) Vestibular incision was placed from 13 to 21 region and incisal third of crown exposed in the nasal floor, b) Completely removed impacted right central incisor d) Closure done using 3-0 vicryl

III. Discussion

An individual may experience significant aesthetic and functional concerns due to the absence of the maxillary central incisor. Research shows that the frequency of maxillary central incisor impaction falls within a certain range of 0.1 -1 % [8]. Common etiology for the impaction are arch length discrepancy, presence of supernumerary teeth, mucosal or bony barrier, retained deciduous teeth, trauma [3,5]. Clinically, an intranasal tooth manifest as a white mass within the nasal cavity, often encased in granulation tissue and debris. Surrounding soft tissues typically exhibit characteristics consistent with granulation tissue observed during clinical and pathological examinations. The differential diagnosis for nasal teeth includes considerations for radiopaque foreign bodies, rhinoliths, odontoma etc. [9]

In this case, there was no visible tooth like structure in the nasal as well as oral cavities. Therefore, radiograph required to confirm the presence of tooth. The major concern of the patient was unappealing smile due to asymmetry of the dentition and right nasal congestion. Conventional radiography has limitations such as superimposition of other structures and inability to view the impacted area in three planes to assess the relation with adjacent vital structures. This limitation often results in the need for additional imaging techniques, such as computed tomography (CT) or cone-beam computed tomography (CBCT) to obtain a more comprehensive view of the affected area [6]. So that after taking OPG for initial assessment, CBCT study done to obtain the information regarding alignment of tooth in the nasal floor and proximity of adjacent vital structures to minimize intra-operative and post-operative complications.

In cases of an ectopic tooth located in the nasal cavity, extraction typically involves a minor surgical procedure. However, challenges may arise when dealing with a tooth deeply embedded in a bony socket within the nasal floor. The presence of teeth in the nasal cavity can be either without symptoms or can present with a range of manifestations, such as facial pain, nasal congestion, headaches, epistaxis, malodorous nasal discharge, deformities of the external nose, and obstruction of the nasolacrimal duct. Potential complications associated with nasal teeth include rhinitis caseosa resulting in septal perforation, aspergillosis, and the formation of a naso-oral fistula. [7]

Management modalities for impacted maxillary central incisors include surgical removal followed by a bridge or implant, surgical exposure and orthodontic traction of the impacted central incisor into the alignment [6]. In this case, the surgical removal was planned after consultation with the orthodontics and prosthodontics departments. Our strategy involved surgical removal of the impacted right maxillary central incisor, then deciding between a fixed partial denture or implant placement after orthodontically creating the necessary space.

Based on our findings, the intraoral vestibular approach performed under general anesthesia proved to be an effective and comfortable method for ensuring a pain-free experience for the patient. Following surgery, the patient noted a significant improvement in nasal congestion, indicating successful relief postoperatively.

IV. Conclusion:

In conclusion, this case report highlights the successful surgical removal of an impacted maxillary central incisor from the nasal floor. Pre-operative imaging and careful planning were crucial in ensuring a successful outcome, as the delicate nature of the nasal floor posed a risk for potential complications. Through a combination of appropriate pre-operative assessments and detailed surgical technique the impacted tooth was safely and efficiently removed without any adverse effects on the surrounding structures. This case serves as a reminder of the importance of thorough evaluation and meticulous surgical technique in managing complex dental pathologies.

References

- [1] Nawaz Mkk, Sivaraman Gs, Santham K: Surgical Management Of An Inverted And Impacted Maxillary Central Incisor - Case Report. *Journal Of The West African College Of Surgeons*. 2015;5(3):84-89.
- [2] Grover Ps, Lorton L. The Incidence Of Unerupted Permanent Teeth And Related Clinical Cases. *Oral Surgery, Oral Medicine, And Oral Pathology*. 1985 Apr;59(4):420-425.
- [3] Mockutė G, Klimaitė G, Smailienė D. The Morphology Of Impacted Maxillary Central Incisors: A Systematic Review. *Medicina*. 2022; 58(4):462.
- [4] Bernal Bg, Coronado Jea, Soto Jms, Nájera Ris. Supernumerary Tooth Impacted Close To The Nasal Cavity: Case Report. *International Journal Of Applied Dental Sciences*. 2023;9(2):216-218.
- [5] Sharifi R, Shafiei S, Moslemi H, Mohammadi Khah M. Intraoral Transnasal Approach For Surgical Extraction Of Bilateral Deeply Impacted Mesiodens: A Case Report. *Clin Case Rep*. 2021;9:E05037.
- [6] Jun-Jie Xue, Nian-Song Ye, Jing-Yu Li, Wen-Li Lai. Management Of An Impacted Maxillary Central Incisor With Dilacerated Root. *Saudi Med J* 2013; 34 (10):1073-1079.
- [7] Chen A, Huang Jk, Cheng Sj, Sheu Cy. Nasal Teeth: Report Of Three Cases. *American Journal Of Neuroradiology*. 2002 Apr 1;23(4):671-3
- [8] Sanei-Moghaddam Et Al. / *British Journal Of Oral And Maxillofacial Surgery* 47 (2009) 484–485.
- [9] Alfayez N, Alhumaid Sa, Alfayez A. Ectopic Nasal Tooth: A Case Report. *International Journal Of Surgery Case Reports*. 2021 Nov 1;88:106459.
- [10] Mathur, Stuti1, Verma, Bhavika1; Dabholkar, Yogesh1; Saberwal, Akansha1. Supernumerary Tooth In The Nasal Cavity. *Journal Of Oral And Maxillofacial Pathology* 25(2):P 373-374, May–Aug 2021.