

Management Of Extra-Oral Mandibular Cutaneously Pus Draining Sinus Tract In A 13-Years Old Girl - A Case Report.

Baksh-Inder Singh Lyall, Akhil Sharma, Jasneet Kaur, Divye Malhotra

Associate Professor, Dept. Of Pedodontics And Preventive Dentistry, Luxmi Bai Institute Of Dental Sciences And Hospital, Patiala, Punjab, India.

Associate Professor, Department Of Pedodontics, Subharti Dental College, Haryana India.

Mds, Dept. Of Pedodontics And Preventive Dentistry, Himachal Dental College, Sundernagar, H.P, India.

Professor, Dept. Of Oral Surgery, Himachal Dental College, Sundernagar, H.P, India

Abstract

Odontogenic cutaneous sinus tract is a rare but well-documented condition. A common manifestation of pulp necrosis is draining sinus tract or fistula, which could be intra-oral or extra-oral. The microbiologically induced inflammation spreads along the path of least resistance by penetrating the alveolar bone. Ultimately, to form a path of drainage, the inflammatory process can reach the surrounding tissues. These conditions are often misdiagnosed as other non-pulp pathologies. So misdiagnosed as a local skin lesion and maltreated by systemic antibiotics, we came across a 13-year-old girl patient who presented with a cutaneous lesion of dental etiology in the sub-mental region with frequent purulent discharge which was not responding to systemic antibiotics. The management of this condition using endodontic therapy of the involved tooth followed by surgical excision of sinus tract so as to minimize the residual scar formation are presented here. Keywords: Extra-oral sinus tract, odontogenic infections, skin diseases

Date of Submission: 15-07-2024

Date of Acceptance: 25-07-2024

I. Introduction

The term sinus tract "refers to a tract leading from an enclosed area of inflammation to an epithelial surface" (An Annotated Glossary of Terms in Endodontics). It also states that the term dental fistula "should be discouraged, and the more proper term sinus tract should be used." In 1961, Bender and Seltzer reported that they found sinus tracts to be lined with granulation tissue not epithelium.[1] A chronic inflammation of pulpal origin is one of the reasons for an extra oral sinus of odontogenic origin.[2] Microorganisms and their by-products, which are present in the periradicular area, might perforate the cortical plate with the infection draining onto the mucosal or cutaneous surface following the path of least resistance, after exiting from the necrotic pulp canal system.[3] time because of the drainage through the sinus tract, a chronic abscess can remain asymptomatic for extended periods of time. If there is a closure of the sinus tract, then the chronic abscess may become symptomatic.[4] Misdiagnosis adds to the chronicity of the lesion and has profound effects on facial esthetics due to unnecessary treatments resulting in cutaneous scarring and dimpling. For this reason, the differential diagnosis of this entity is of utmost importance. There is little reported literature on the prevalence of extra-oral cutaneous sinus lesions in the paediatric dental patient as the presentation is often delayed resulting in misdiagnosis and consequential mismanagement.[5] Therefore, this article presents a case of pediatric patient having an extra-oral cutaneous sinus tract in the sub-mental region, management initiated conservatively by nonsurgical endodontic treatment of the offending teeth followed by the surgical excision of the sinus tract so as to minimize the residual scar formation and dimpling as esthetics was of great concern to the patient herself and her parents.

II. Case Report

A 13 year old girl patient reported to the Department of Pedodontics and preventive dentistry department of Himachal Dental college, Sundernagar, H.P [INDIA], with chief complaint of pus drainage around the sub-mental region associated with sharp pain since last 2 weeks. The patient gave a history of recurrence and remission of the fever for one month, for which she was treated by a general physician. The medical history was noncontributory. The patient recalled that the sinus tract started 6 months ago, as a small swelling in the sub-mental region, associated with mild discomfort in the area. Soon after, it developed to a small skin lesion with spontaneous drainage. Following, she asked medical advice from a physician that started

treating the lesion as of skin infection by means of systematic antibiotic administration. Since there was a recurrence of the lesion and fever over and over again, she was referred to our dental institute for our opinion.

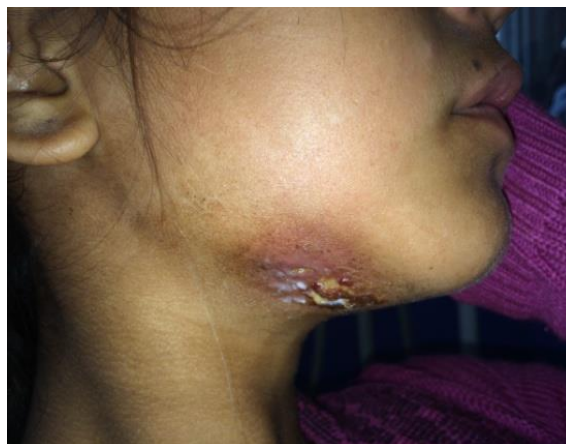

Figure 1-A

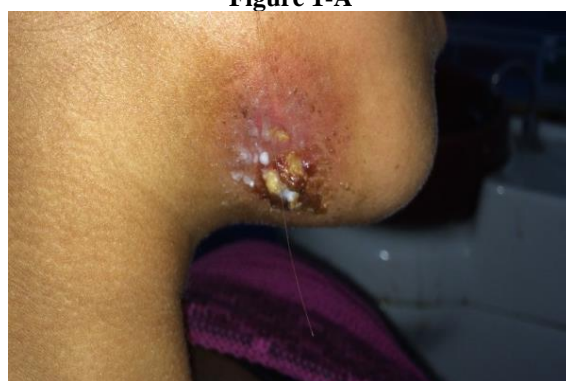

Figure 1-B

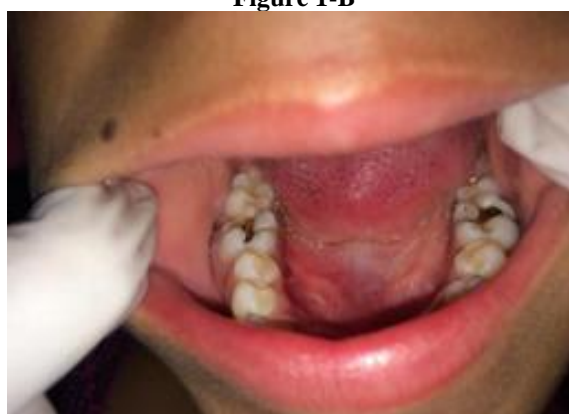

Figure 1:C:- Intra oral examination revealed patient had grossly carious mandibular first molars. [#36 and #46]

Figure 1: [A,B,C]

Extra Oral cutaneous lesion on (5-6 cm) the right side of the cheek with purulent discharge.

Dental carious lesions were prominent on both mandibular first molar i.e #36 and #46 and required adequate dental treatment. The involved tooth with the lesion i.e. #46 was not tender on percussion and it did not respond to heat and electric pulp testing. On radiographic examination, it was found that there was an evidence of dental caries, which involved the pulp in the disto-occlusal aspect of the crown and diffuse periapical radiolucency. Furthermore, CAD-CAM interpretation of accumulated data detailed us on the exact extent of peri-apical infection which has formed a pus draining sinus tract on extra oral surface of same side of angle of mandible.[Figure-2] Root canal treatment with rubber dam isolation of the involved tooth was performed. Surgical excision of sinus tract was planned as to prevent dimpling and to minimize residual scar formation. Under Local anesthesia, primary full thickness incision was made. [Figure 3]. The area was dissected

to surgically remove the cord-like tract of approx. 1.6 1.8 cm in size [Figure 4&5]. The skin was undermined to relax the affected area and restore the normal facial contour. Sub-cuticular sutures was placed [Figure 6]. After 3 months of follow up, the cutaneous lesion had healed completely with neat linear scar formation, which is esthetically satisfactorily for patient herself and her parents [Figure 7&8].

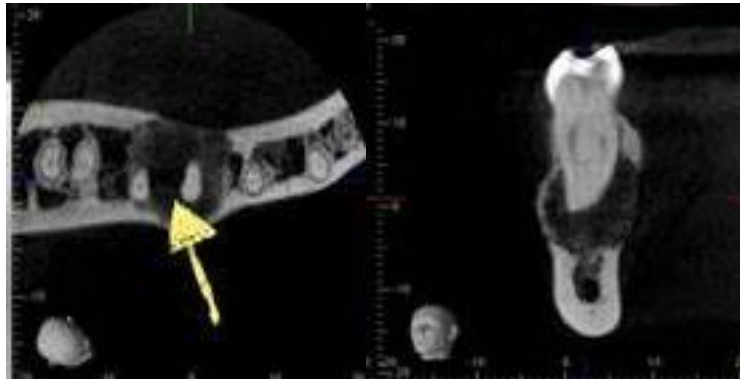


Figure-2 :- CAD-CAM Interpretation Of Accumulated Data Detailed Us On The Exact Extent Of Peri-Apical Infection Which Has Formed A Pus Draining Sinus Tract On Extra Oral Surface Of Same Side Of Angle Of Mandible #46

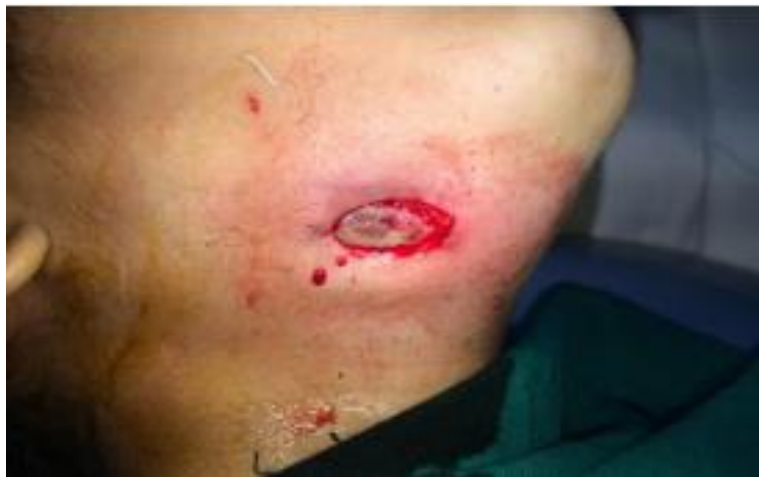

Figure-3 :- Under Local Anesthesia, Primary Full Thickness Incision Was Made.

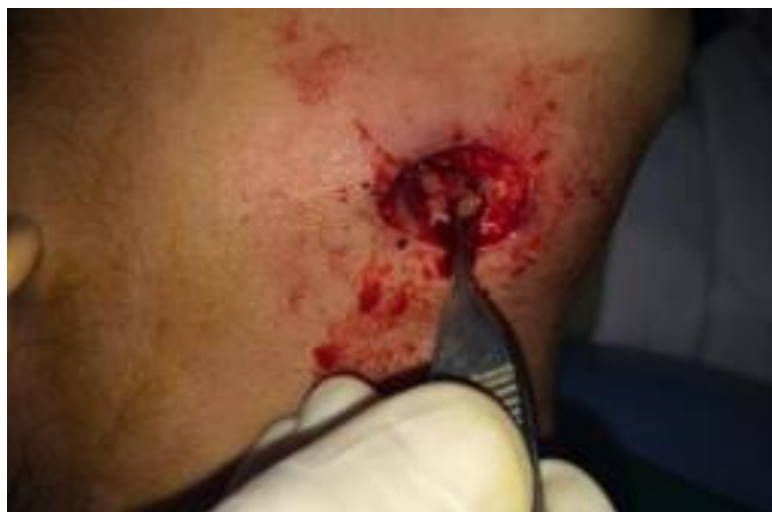

Figure 4- Surgical Excision Of Sinus Tract.

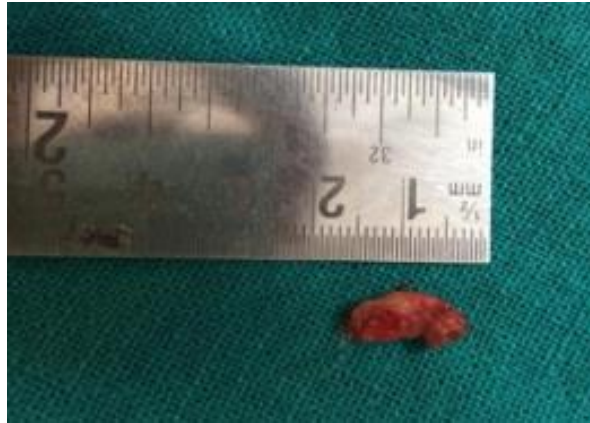

Figure- 5- Dimension Of Specimen Sinus Tract Fragment.

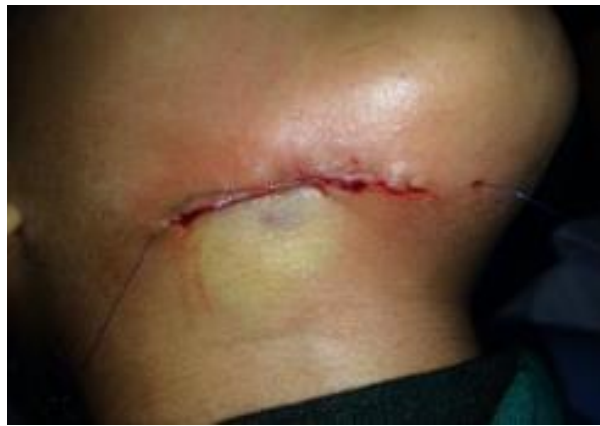

Figure-6 Sub-Cuticular Sutures

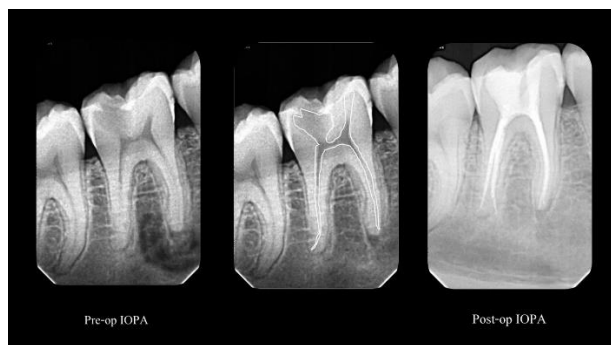

Figure-7 Pre And Post Operative Radiographic View Of Successful Intervention With The Help Of Endodontical With Surgical Procedures.

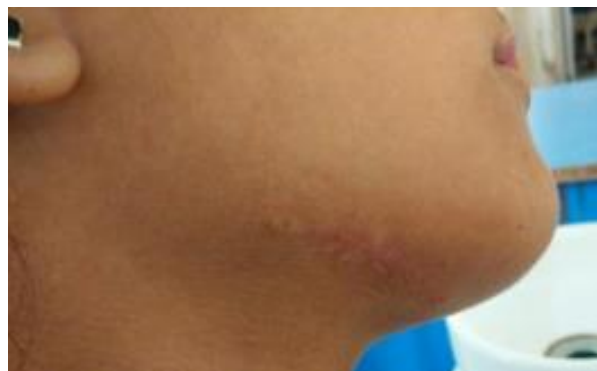

Figure-8 :- After 3 Months Of Follow Up, The Cutaneous Lesion Had Healed Completely With Neat Linear Scar Formation.

III. Discussion

Cutaneous sinus tracts of dental origin have been well documented in both the medical literature [1–9] and the dental literature.[6-7] However, these lesions can present a diagnostic challenge because these tracts often have a clinical appearance similar to other facial lesions and are relatively uncommon.[8] The differential diagnosis should include traumatic lesions, fungal and bacterial infections, neoplasms, presence of a foreign body, local skin infections (carbuncle and infected epidermoid cyst), pyogenic granuloma, chronic tuberculosis lesion, osteomyelitis, actinomycosis, and gumma of tertiary syphilis. Rare entities to be included in the differential diagnosis are developmental defects of thyroglossal duct origin or branchial cleft, salivary gland and duct fistula, dacryocystitis, and suppurative lymphadenitis.[9] However, these lesions continue to be a diagnostic dilemma. The evaluation of a cutaneous sinus tract must begin with a thorough patient history and awareness that any cutaneous lesion of the face and neck could be of dental origin. Winstock[10] described cutaneous lesions with dental infections. Kaban[11] elaborated the path of spread of chronic dental infections. Approximately 80% of the reported cases are associated with mandibular teeth and 20% with maxillary teeth.[12] Most commonly involved areas are the chin and sub-mental region.[13] Root-canal therapy is the treatment of choice if the tooth is restorable. Extraction is indicated for non restorable teeth.[9] In the case of a chronic odontogenic sinus tract, extraction of the causal tooth may not be sufficient for complete healing to occur. In those cases, the cord-like tract must be eliminated. It can be either cut from its insertion (attachment) to the underlying alveolar bone or removed by complete excision. Biopsy alone should be avoided as it may lead to exacerbation of infection or scarring. Antibiotic therapy is indicated when there are signs of systemic involvement (e.g., fever or lymphadenopathy).[14] In this case, report the cord was removed from its origin to the point of skin attachment, which allowed relaxation of the facial skin, elimination of the skin dimpling in the affected area, and restoration of normal facial contours

IV. Conclusion

Elimination of the source of infection by endodontic treatment or tooth removal generally results in resolution of the sinus tract. But in the case of an older sinus tract, wound contraction and scar tissue formation may require surgical management to excise the cord-like tract. This report describes a case involving a cutaneous sinus tract of dental origin that required surgical removal of the sinus tract from the periapical zone of the causal teeth. The aim of this paper is to present a dental and medical literature review of cutaneous sinus tract with a dental origin and to present the surgical technique used to eliminate the cord-like tract and dimpling of the skin for esthetic concerns.

References

- [1] N Cohenca, S Kami, I Rotstein. Extraoral Sinus Tract Misdiagnosed As An Endodontic Lesion. *J Endod.* 2003; 29 (12):841-843
- [2] Bender Ib, Seltzer S. The Oral Fistula: Its Diagnosis And Treatment. *Oral Surg Oral Med Oral Pathol.* 1961; 14: 1367-76
- [3] Kotecha M, Browne Mk. Mandibular Sinuses Of Dental Origin. *Practitioner.* 1981;225:910-5.
- [4] Mohan S. Endodontic Management Of Cutaneously Draining Odontogenic Sinus Using Shoe Lace Technique. *Indian Journal Of Clinical Practice.* 2013; 24(4):330-335.
- [5] Swales Kl, Rudralingam M, Gandhi S. Extraoral Cutaneous Sinus Tracts Of Dental Origin In The Paediatric Patient. A Report Of Three Cases And A Review Of The Literature. . [*Int J Paediatr Dent.* 2015;22 Doi: 10.1111/IpD.12205
- [6] Cioffi Ga, Terezhalmly Gt, Parlette Hl. Cutaneous Draining Sinus Tract: An Odontogenic Etiology. *J Am Acad Dermatol.* 1986; 14(1):94-100.
- [7] Caliskan Mk, Sen Bh, Ozinel Ma. Treatment Of Extraoral Sinus Tracts From Traumatized Teeth With Apical Periodontitis. *Endod Dent Traumatol.* 1995; 11(3):115-20
- [8] Barrowman Ra, Rahimi M, Evans Md, Chandu A, Parashos P. Cutaneous Sinus Tracts Of Dental Origin. *Med J Aust.* 2007; 186(5):264-5.
- [9] Tidwell E, Jenkins Jd, Ellis Cd, Hutson B, Cederberg Ra. Cutaneous Odontogenic Sinus Tract To The Chin: A Case Report. *Int Endod J.*1997; 30(5):352-5.
- [10] Winstock D. Four Cases Of External Facial Sinuses Of Dental Origin. *Proc R Soc Med.* 1959;52:749-51.
- [11] Kaban Lb. Draining Skin Lesions Of Dental Origin: The Path Of Spread Of Chronic Odontogenic Infection. *Plast Reconstr Surg.* 1980; 66(5):711-7.
- [12] Mittal N, Gupta P. Management Of Extra Oral Sinus Cases: A Clinical Dilemma. *J Endod.* 2004;30(7):541-7.
- [13] Cioffi Ga, Terezhalmly Gt, Parlette Hl. Cutaneous Draining Sinus Tract: An Odontogenic Etiology. *J Am Acad Dermatol.*1986; (1):94-100. 14. Witherow H, Washan P, Blenkinsopp P. Midline Odontogenic Infections: A Continuing Diagnostic Problem. *Br J Plast Surg.* 2003; 56(2):173-5.15. Ahmed Chkoura, Dds; Wafaa Elwady, Dds; Bouchra Taleb, Dds. Surgical Management Of A Cutaneous Sinus Tract: A Case Report And Review Of The Literature. *The Journal Of Contemporary Dental Practice.* 2010;01
- [14] How To Cite This Article: Lyall Bis, Kaur J, Aggarwal I, Malhotra D, Negi M. Surgical Management Of Extra-Oral Mandibular Cutaneously Pus Draining Sinus Tract In A 13 Years Old Girl- A Case Report. *Ann. Int. Med. Den. Res.*