

## Diagnosis of Tuberculosis in Hydrocele fluid.

Dr. Sharon Christina<sup>1\*</sup>, Dr. Raveendran Praveena<sup>2</sup>, Dr. Mymoonah Risha<sup>3</sup>

<sup>1</sup> MD Postgraduate, Department of Microbiology, Sree Balaji Medical College and Hospital, Bharath Institute of Higher Education, Chennai, India.

<sup>2</sup> Professor of Microbiology, Department of Microbiology, Sree Balaji Medical College and Hospital, Bharath Institute of Higher Education, Chennai, India.

<sup>3</sup> Senior resident, Department of Microbiology, Sree Balaji Medical College and Hospital, Bharath Institute of Higher Education, Chennai, India.

---

### Abstract:

#### Background:

**Case Presentation:** Tuberculosis (TB) affecting hydrocele fluid is not common. A case of a 48-year-old male with a painless, progressively enlarging scrotal swelling over six months. Despite lacking typical TB symptoms, hydrocele fluid analysis revealed acid-fast bacilli (AFB) and a positive tuberculin skin test. diagnosis was confirmed by AFB staining and fluid analysis. Treatment with standard anti-tubercular therapy (ATT) resulted in rapid clinical improvement.

**Conclusion:** This case underscores the importance of considering TB in the differential diagnosis of hydrocele, to guide prompt treatment and prevent complications.

**Keywords:** Tuberculosis, Acid-fast bacilli, Hydrocele, Anti-tubercular therapy.

---

Date of Submission: 26-06-2024

Date of Acceptance: 04-07-2024

---

### I. Introduction:

Tuberculosis continues to be a major global public health concern. According to the World Health Organization (WHO), over 10 million people contract active tuberculosis each year, leading to 1.6 million deaths annually due to the disease(1). Pulmonary tuberculosis (TB) represents the predominant form of TB disease, whereas extra-pulmonary TB (EP-TB) accounts for only 10–15% of cases. Among EP-TB cases in India, lymph nodes are the most frequently affected site. Genital TB, including testicular TB, is uncommon overall, with testicular TB specifically constituting 3% of genital TB cases(2).

Hydrocele refers to an abnormal accumulation of serous fluid between the two layers of the tunica vaginalis surrounding the testis. This condition can be either congenital, present from birth, or acquired later in life(3). In children, isolated epididymal TB lesions are more common and likely spread through the bloodstream. Adults typically develop tuberculous epididymo-orchitis from direct spread via the urinary tract. Direct extension causes testicular involvement. Infertility can result from blocked vas deferens on both sides(4). It is crucial for practitioners to consider the diagnosis of isolated genital tuberculosis promptly. Delay in diagnosis and treatment can lead to infertility and the potential spread of tuberculosis (5).

### II. Case Report:

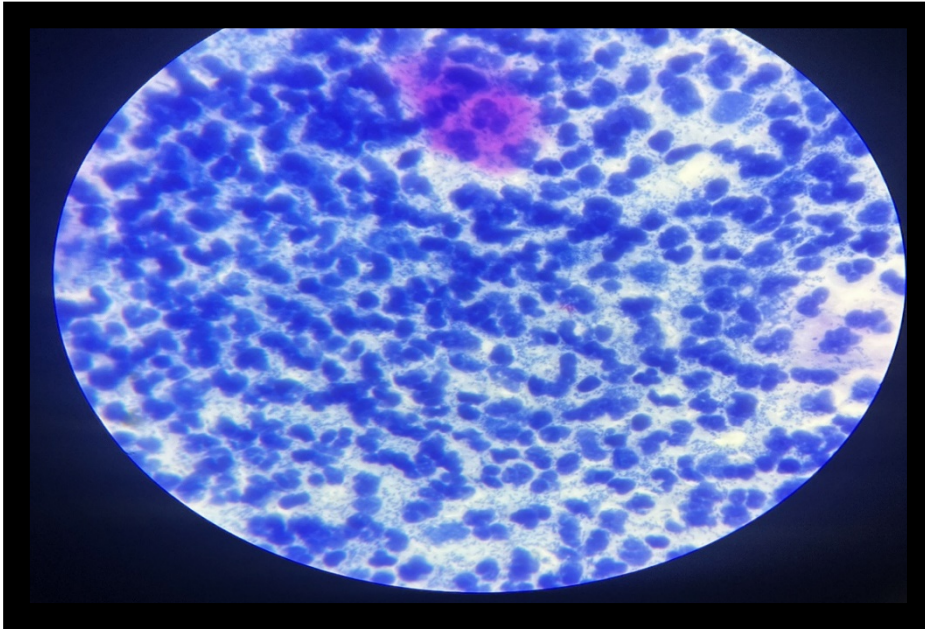
A 48-year-old male farmer from a rural area, presented with a six-month history of painless, progressive swelling of the scrotum, with mild discomfort. The patient had no notable past history.

On inspection the scrotum was enlarged, presenting as a smooth swelling approximately 10cm×8cm × 4 cm in size. The overlying skin was free of redness or signs of inflammation. The swelling was soft and fluctuant on palpation, with well-defined borders and non-reducibility upon gentle pressure. The swelling was non-tender. A transillumination test showed the presence of fluid consistent with a hydrocele.

A scrotal and testicular ultrasound showed a well-defined, vascular, non-calcified hypoechoic lesion, set against a background of several minor hypoechoic foci. The epididymis was large, hypoechoic, and hypervascular.

Routine blood investigations showed normal ranges: total count: 7580 cells/mm<sup>3</sup>, hemoglobin: 14 g/dL, fasting blood sugar: 96 mg/dL, and creatinine: 0.6 mg/dL. The Tuberculin skin test was positive.

Fluid was aspirated for analysis from the scrotal sac. It appeared to be straw-colored non-purulent fluid, with elevated protein levels and numerous lymphocytes. Acid-Fast Bacilli (AFB) staining of the fluid by Ziehl–Neelsen staining was positive Fig 1.



**FIG:1** A positive Acid-Fast Bacilli (AFB) staining by Ziehl–Neelsen staining indicates the presence of acid-fast bacteria in the fluid sample.

In Lowenstein-Jensen Medium the growth of *Mycobacterium tuberculosis* was seen after 3-6 weeks of incubation. The presence of MTB 64 antigen was detected in the aspirated hydrocele fluid, confirming the presence of active *Mycobacterium tuberculosis* infection. Histopathological Examination of the Tunica Vaginalis: Granulomatous inflammation with caseating necrosis, a hallmark of TB infection.

The patient was started on anti-tuberculosis therapy (ATT) with a standard four-drug regimen: Rifampicin (600mg), Isoniazid(300mg), Pyrazinamide(35mg), and Ethambutol(25mg) for two months, followed by Rifampicin and Isoniazid for an additional four months. Analgesics was given for discomfort and scrotal support was provided. Significant reduction in scrotal swelling and resolution of discomfort was noted within two months of initiating ATT, and complete resolution of hydrocele with no recurrence was observed at the six-month follow-up.

### **III. Discussion:**

Tuberculous hydrocele is a rare manifestation of extrapulmonary TB. It is crucial to consider TB in the differential diagnosis of chronic hydrocele, especially in endemic regions. Delayed diagnosis and treatment can lead to complications such as infertility and the potential spread of the infection. Early intervention with appropriate anti-tubercular therapy can result in favorable outcomes, as demonstrated in this case. The presence of AFB in aspirated fluid, the detection of MTB 64 antigen, and granulomatous inflammation with caseating necrosis in biopsy specimens are key diagnostic features. The MTB 64 antigen test, in particular, provides a rapid and reliable confirmation of active TB infection, facilitating timely and targeted treatment.

#### **IV. Conclusion:**

This case highlights the importance of considering tuberculosis in the differential diagnosis of chronic hydrocele, especially in endemic regions. Early diagnosis and appropriate treatment are crucial for favorable outcomes in tuberculous hydrocele.

#### **References:**

- [1]. Ben Lahlou Y, Laanibi Z, Malihy Z, Benaissa E, Maleb A, Elktaibi A, et al. A hydrocele revealing epididymal tuberculosis. *Access Microbiology* [Internet]. 2024 [cited 2024 Jun 27]; Available from: <https://www.microbiologyresearch.org/content/journal/acmi/10.1099/acmi.0.000781.v2>
- [2]. Das A, Batabyal S, Bhattacharjee S, Sengupta A. A rare case of isolated testicular tuberculosis and review of literature. *J Family Med Prim Care*. 2016;5(2):468–70.
- [3]. Huzaifa M, Moreno MA. Hydrocele. In: *StatPearls* [Internet]. Treasure Island (FL): StatPearls Publishing; 2024 [cited 2024 Jun 27]. Available from: <http://www.ncbi.nlm.nih.gov/books/NBK559125/>
- [4]. *Tuberculosis of the Genitourinary System: Practice Essentials, Pathophysiology and Etiology, Epidemiology*. 2023 Aug 17 [cited 2024 Jun 27]; Available from: <https://emedicine.medscape.com/article/450651-overview>
- [5]. Issaoui ZB, Kharbach Y, Khallouk A. Isolated Epididymal Tuberculosis: A Challenging Diagnosis. *Integrative Journal of Medical Sciences* [Internet]. 2024 May 30 [cited 2024 Jun 27];11. Available from: <https://www.mbmjpress.com/index.php/ijms/article/view/732>