

# Evaluation of knowledge, attitude and practice regarding positron emission tomography- A Questionnaire based Cross sectional survey

Dr. Kavitha. M<sup>1</sup>, Dr. Sarumathi. T<sup>2</sup>, Dr. Devi. S<sup>3</sup>, Dr. Guruswathy. R<sup>4</sup>,  
Dr. Vigneshwaran. J<sup>5</sup>, Dr. Pragatheeswari. R<sup>6</sup>

<sup>1</sup> Professor, Department of Oral Medicine and Radiology, Madha Dental College and Hospital. Kundrathur, Chennai-69, India

<sup>2</sup> Professor and Head of department of Oral Medicine and Radiology, Madha Dental College and Hospital. Kundrathur, Chennai-69, India

<sup>3</sup> Post graduate student (corresponding author), Department of Oral Medicine and Radiology, Madha Dental College and Hospital. Kundrathur, Chennai-69, India

<sup>4</sup> Post graduate student, Department of Oral Medicine and Radiology, Madha Dental College and Hospital. Kundrathur, Chennai-69, India

<sup>5</sup> Post graduate student, Department of Oral Medicine and Radiology, Madha Dental College and Hospital. Kundrathur, Chennai-69, India

<sup>6</sup> Post graduate student, Department of Oral Medicine and Radiology, Madha Dental College and Hospital. Kundrathur, Chennai-69, India

---

## Abstract

*Background and Objectives:* Positron emission tomography (PET) scan is a radionuclide imaging technique with implications in diagnostic and therapeutic oncology. Due to the complexity in the technique and cost factor, this technique has not been popular among the general and specialty dental practitioners. This survey study utilizes the Likert item to evaluate the intensity of response toward the technical and practical aspects of PET scan in dentistry.

## Material and methodology

A questionnaire based cross sectional survey was done with 250 respondents, the respondents were either postgraduate or faculties volunteers of various dental college. Questions were framed in English language, divided into three sections, the questions were analyzed and standardized by two faculty experienced in imaging sciences. An online questionnaire was developed to analyze the knowledge, attitude and practice regarding PET scan, viewing protocols and contouring techniques practiced. Most questions required single best response selected from multiple choice.

## Results

The result obtained in the present study shows the scoring for few questions pertaining to the knowledge of PET scan was far optimal level in our study compared to attitude and practice regarding PET Scan. In the present study the KAP analysis about the evaluation of PET Scan among dental students and faculties revealed that the overall impression of the respondents for knowledge in the survey was above the optimum level. This study shows that lack of knowledge about dental imaging models and hence dental curriculum has to be updated with advanced imaging techniques. Thus, it is necessary to include evidence-based teaching and training about the application of advanced imaging techniques in dental practice to improve the future of dentistry.

## Keywords

Anatomical and metabolic imaging, fluorodeoxyglucose, hot-spot

Date of Submission: 27-06-2024

Date of Acceptance: 05-07-2024

---

## **I. Introduction**

Positron emission tomography is a molecular imaging technique with a wide range of clinical and research application that produces a three-dimensional image of part of body, reveal metabolic and biochemical function of tissues and organs. <sup>(1,2)</sup> The PET scan uses a radioactive tracer (fluorodeoxyglucose) to show both normal and abnormal metabolic activity. A PET scan can often detect the atypical metabolism of the tracer in diseases before the disease shows up on other imaging tests, such as computerized tomography (CT) and magnetic resonance imaging (MRI). It is widely used in dentistry, in diagnosis to evaluate and treat cancer in head and neck region. Hence, dentists must be aware of its importance and role in this field. <sup>(3,4,5)</sup> This study was done with knowledge, attitude, practice (KAP) questionnaire to evaluate the knowledge among dentists and dental faculties about PET scan. <sup>1</sup>

## **II. Material and methodology**

This is a questionnaire based cross sectional survey was done with 250 respondents, the respondents were either postgraduate or faculties volunteers of various dental colleges in and around Chennai city. Questions were framed in English language, divided into three sections, the questions were analyzed and standardized by two faculties well experienced in imaging sciences. An online questionnaire was developed to analyze the knowledge, attitude and practice regarding PET scan, viewing protocols and contouring techniques practiced. Most questions required single best response selected from multiple choices.

### **Inclusion criteria**

1. Post graduate dental students
2. Dental faculty & Clinicians

### **Exclusion criteria**

1. Undergraduate dental students
2. CRIs

This questionnaire is divided into three sections (i.e. Knowledge, attitude and practice)  
Kindly choose the option of your choice

### **Know10ledge**

1. What is the full form of PET?
  - a) Positive emission tomography
  - b) Positron emission tomography
2. Does PET used X rays?
  - a) Yes
  - b) No
3. Is PET scan an evolution for diagnosis in dentistry?
  - a) Yes
  - b) No
4. If yes, what does a PET scan reveal?

- a) Site of organ/tissue
  - b) Shape of organ/tissue
  - c)Function of organ/tissue
5. What is the commonly used radionuclide?
- a) Xenon
  - b)18-fluorodeoxyglucose
  - c)Argon
  - d)Nitrogen

**Attitude**

6. What is Hotspot?
- a) Area of increased uptake of radiopharmaceutical agent
  - b) Area of highest temperature in PET machine
7. What is gamma camera?
- a) Uses gamma rays to capture images
  - b) Scintillation detector used in PETs
8. PET Scan is commonly used in dentistry?
- a) Agree
  - b) Strongly agree
  - c) Disagree
  - d) Not aware
9. PET scan is helpful in detecting anatomical, biochemical and metabolic activity of tumour?
- a) Agree
  - b) Strongly agree
  - C)Disagree
  - d) Not aware
10. PET scan can determine extent, location and number of metastases?
- a) Agree
  - b) Strongly agree
  - c) Disagree
  - d) Not aware

**Practice**

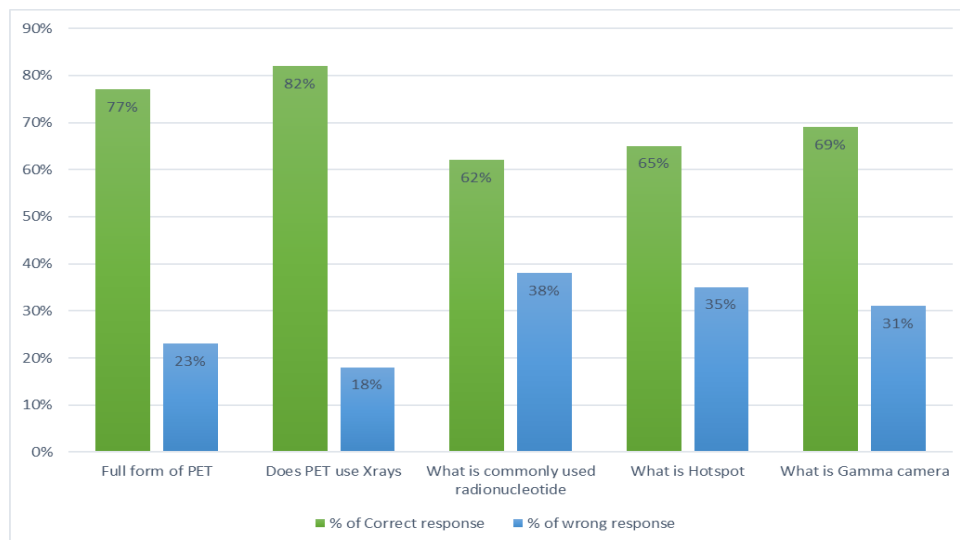
11. Can PET scan be advised for pregnant women?
- a) Agree
  - b) Strongly agree
  - c) Disagree
  - d) Not aware
12. PET scan is an economical diagnostic aid?
- a) Yes
  - b) NO
13. PET scan with CT is better identifying tumour?
- a) Yes
  - b) NO
14. PET scan helps to differentiate benign and malignant tumours?
- a) Yes
  - b) No

### III. RESULTS

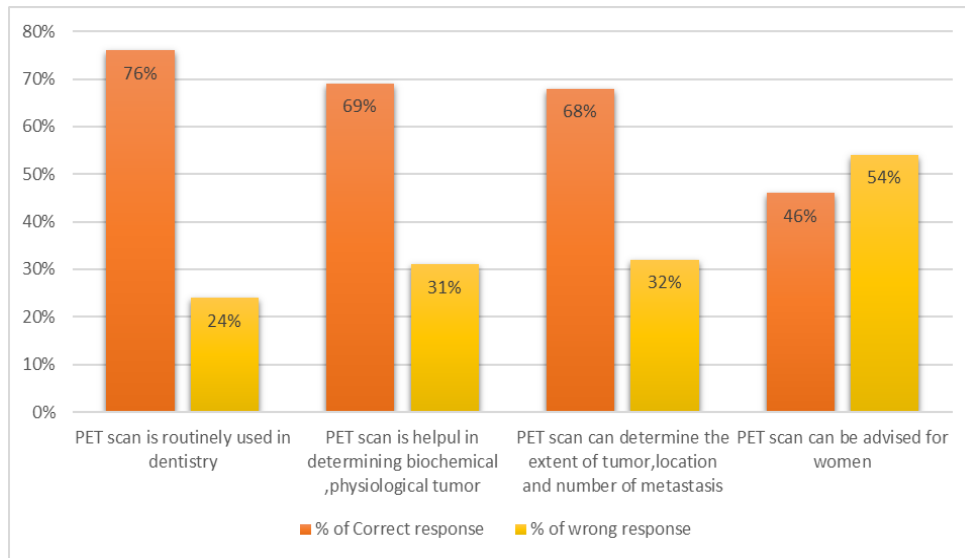
In our survey of 250 respondents, 200 responded positively to the questionnaire. This indicated drop out percentage of 15%. This study provides insight pertaining to various aspects of PET scan as perceived by dental professionals. However, the scoring for few questions pertaining to the knowledge of PET scan was far below optimal level in our study. A PET scan is not routinely advised by dentists in accordance to respondents in our study scored the maximum for strong disagreement on the question. However, PET scan has been advised by dentists for assessing distant metastasis.

On the evaluation of knowledge, there was an overwhelming correct response of 77.2% by the respondents for the question on “full form of PET” which stands for “Positron emission tomography.” Role of PET scan in dentistry was correctly responded by 80.2%.PET scan reveal functions of organ/tissue correctly responded by 76.4%. Radionucleotide used in PET scan was correctly responded by 61.6%. PET scan can determine location, extent and number of metastases was strongly agreed by 68%. Most of the respondents were correctly responded what is hotspot in 65.2% where others were clueless. However, PET scan advised for pregnant women was most of respondents gave wrong response approximately 54%.PET is better than identifying tumour than CT was correctly responded by 90% of the respondents. [Table 1]. The objective of evaluating “attitude” in this study was to elicit the intensity of response by the subjects toward various aspects of PET scan. However, the respondents failed to make the correct choice between single photon emission CT (SPECT) and PET-CT. Claustrophobia is a main disadvantage of PET scan was correctly responded by 85.2%.

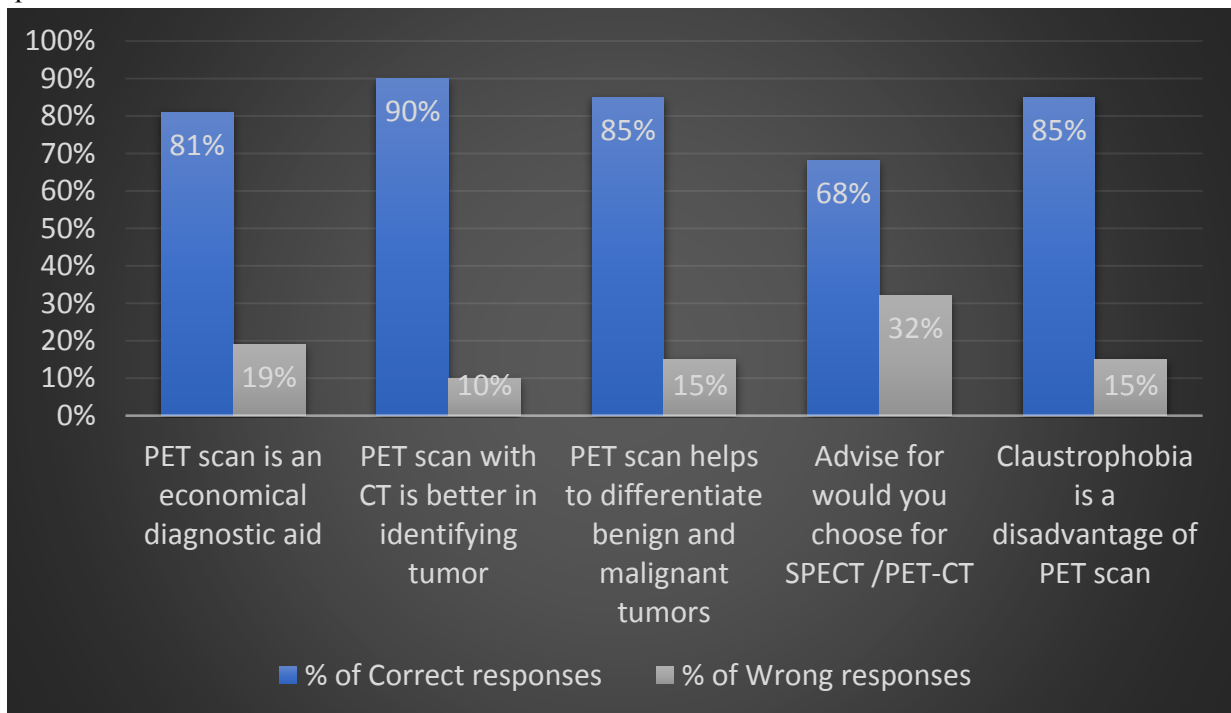
The bar graph representing the percentage of correct and wrong responses for Knowledge of KAP questionnaire



The bar graph representing the percentage of correct and wrong responses for Attitude of KAP questionnaire



A bargraph representing the percentage of correct and wrong responses for practice of KAP questionnaire



#### **IV. DISCUSSION**

There was an overwhelming correct response of 77.2% by the respondents for the question on "full form of PET", which correlate with Santhosh et al (2015). In our survey, respondents gave strong agreement that PET scan is in evolution for diagnosis in dentistry but in contrast to Nagaraj et al 2015. According to our study, 76.4% gave correct response which correlate to Jaganathan et al 2002 who confirms that PET imaging is unique in that it shows the functioning of organs and tissues, while other imaging technique such as X-ray and CT shows structure. It also provides information about metabolic activities of tumour and reveals metabolic activity that may occur with treatment. In our study, 61.6% gave correct response 18-FDG which correlate with Suzuki et al 2012 suggested that pretreatment with FDG-PET is able to provide both non-invasive and effective information for identifying a high or low risk group of oral cancer patient with distant metastasis, 11.2% gave a response of Xenon, 12.4% gave a response of Argon, 14.8% gave a response of Nitrogen. In our survey, respondents had strong agreement with Hotspot but in contrast to Nagaraj et al in 2015. <sup>(6,7,8)</sup>

#### **V. CONCLUSION**

In the present study the KAP analysis about the evaluation of PET Scan among dental students and faculties revealed that the overall impression of the respondents for knowledge in the survey was above the optimum level. This study shows that lack of knowledge about dental imaging models and hence dental curriculum has to be updated with knowledge on advanced imaging techniques. Thus, it is necessary to include evidence-based teaching and training about the application of advanced imaging techniques in dental practice to improve the future of dentistry. <sup>(9,10)</sup>

#### **REFERENCES**

- [1]. Townsend DW. Multimodality imaging of structure and function. *Phys Med Biol*, 2008; 53: R1-R39.
- [2]. Bischof Delaloye A, Carrio I, Cuocolo A et al. FDG PET and PET/CT: EANM procedure guidelines for tumour PET imaging: Version 1.0. *Eur J Nucl Med mol imaging*. 2010;37: 181-200.
- [3]. Beyer T, Antoch G, Mueller S et al, Acquisition protocol considerations for combined PET/CT imaging. *J Nucl Med*. 2004;45(suppl 1): 25S-35S.
- [4]. Hausegger K, Reinprecht P, Kau T, et al. Clinical experience with a commercially available negative oral contrast medium in PET/CT. *Rofo*. 2005; 177:796-799.
- [5]. Bither F, Dawood M, Stegger L L, et al. List mode-driven cardiac and respiratory gating in PET. *J Nucl Med*. 2009; 59: 674-681.
- [6]. Lee H, Tajmir S, Lee J, Zissen M, Yeshiwas BA, Alkansasab TK, Choy G, Do S, Fully Automated Deep Learning System for Bone Age Assessment. *J Digit Imaging* 2017; 30:427-41.

- [7]. Czemin J, Allen – Auerbach M, Schelbert H. Improvements in cancer staging with PET/CT: literature-based evidence as of September 2006. *J Nucl Med.* 2007;48 (suppl 10: 78S-88S.
- [8]. Manfreda KL, Bosnjak M, Berzhek J et al. Web surveys versus other survey modes: a meta-analysis comparing response rates. *Int J Market Res.* 2008;5079-104.
- [9]. Rangarajan V, Purandare NC, Sharma AR, Shah S. PET/CT: Current status in India. *Indian J Radial Imaging.* 2008; 18:290-294.
- [10]. Biersack HJ. PET-CT: Comments on the white paper [letter]. *Eur J Nucl Med Mol Imaging.* 2008; 35:1576.