

Anatomical Variations of Paranasal Sinuses on Computed Tomography: An Observational Study

Dr. Masthan Salapakshi^{*1}, Dr. Dr. B. E. Panil Kumar², Dr. Anil Kumar³

Postgraduate^{*1}, Professor & HOD² Assistant Professor³

Department of Radiology, Santhiram Medical College, Andhra Pradesh, India^{1,2}

Dept. of ENT³: Santhiram Medical College, Andhra Pradesh, India

Abstract:

Background: Sinonasal anatomic variants are commonly seen on sinus computed tomography (CT) scans. The most common ones are infraorbital ethmoidal (Haller) cells, Agger nasi cells, cells, nasal septal deviation, sphenoidal (Onodi) and concha bullosa. Agger nasi cells are anterior ethmoidal air cells. In view of conflicting results of the presence or absence of associations of anatomical variants with chronic rhinosinusitis, the current study was undertaken.

Objectives:

1. To investigate the prevalence of anatomic variants of sinonasal cavities
2. To assess the relation to sinonasal mucosal disease

Materials and Methods: The study was done on 100 patients. This Observational study was done in the Department of Radiodiagnosis at Santhiram Medical College, Nandyal, Andhra Pradesh India. Male and females aged above 20 years with clinical features suspecting of rhinosinusitis were included. 50 patients were cases with confirmed chronic rhinosinusitis in CT scan and 50 patients were controls with no evidence of chronic rhinosinusitis in CT scan. Prevalence and types of anatomical variants were assessed.

Results: There is no significant difference in the mean age or gender of cases and controls. The prevalence of anatomical variations among 100 patients was 44%. 38% of cases and 6% of controls had anatomical variations. There is a significant association between the presence of anatomical variations and chronic rhinosinusitis. The most common anatomical variation is nasal septal deviation. Unilateral anatomical variations are more common compared to bilateral anatomical variations.

Conclusion: Routine screening of patients presenting with suspected rhinosinusitis symptoms with CT scan helps to identify various anatomic variants and thus helpful to plan surgery accordingly to minimize damage to adjacent structures.

Keywords: Paranasal sinuses, Anatomical variations, Computed tomography, Rhinosinusitis, Prevalence

Date of Submission: 27-06-2024

Date of Acceptance: 05-07-2024

I. INTRODUCTION

Sinonasal anatomic variants are commonly seen on sinus computed tomography (CT) scans. The most common ones are infraorbital ethmoidal (Haller) cells, Agger nasi cells, cells, nasal septal deviation, sphenoidal (Onodi) and concha bullosa. Agger nasi cells are anterior ethmoidal air cells. They are located anterior, and inferior to frontal recess.¹ Haller cells are ethmoidal cells which extend downward under medial floor of orbit near and above maxillary sinus ostium lateral to infundibulum.² Onodi cells are posterior ethmoidal cells which extend laterally, posteriorly to sphenoid sinus.³

Nasal septal deviation is any bending of septal contour on CT scans and is present in more than 50% of the patients.⁴ Concha bullosa is pneumatization of middle turbinate involving inferior bulbous portion.⁵

Pneumatization of lamina of middle turbinate and pneumatization of the superior turbinates occurs fairly frequently.⁶⁻⁷ Less common anatomic variants include pneumatization of uncinate process, supraorbital cells and pneumatized crista galli.⁸⁻⁹

Some of these anatomic variants were reported to be associated with chronic rhinosinusitis, causing inflammation by obstructing pathways of drainage from sinuses.¹⁰

One study showed that large ethmoidal bullae are correlated with maxillary sinusitis¹¹, and another study¹² showed an association between infraorbital ethmoidal cells, paradoxically bent turbinate's, and chronic rhinosinusitis.

There is significant association between presence of sinus mucosal disease and nasal septal deviation (NSD), Haller cells, bilateral concha bullosa, and hypertrophic ethmoidal bullae.¹³

There are also some studies which did not show a significant relation between anatomic variants and rhinosinusitis. In view of conflicting results, the current study was undertaken.¹⁴⁻¹⁶

Moreover, it has been reported that failure to recognize certain anatomic variants like Onodi cells, pneumatization of anterior clinoid processes, Haller cells, pneumatization of dorsum sellae, and dehiscence of the lamina papyracea can cause complications during surgery due to proximity of nerves, blood vessels, brain, and orbits.

Objectives:

To investigate the prevalence of anatomic variants of sinonasal cavities
To assess the relation to sinonasal mucosal disease.

II. MATERIAL AND METHODS

Study site: Department of Radiodiagnosis, Santhiram Medical College, Nandyal.

Study duration: six months: December 2023 to May 2024

Sample size: 100

Type of study: Interventional study

Ethical considerations:

Informed consent was taken from every participant.

Inclusion criteria:

- Patients present with complaints of nasal obstruction, rhinorrhea, facial pain, headache, nose bleeds, or with previous history of PNS problems.
- Patients who provided informed consent.

Exclusion criteria:

- Pregnant or lactating women.
- Patients who do not give written and informed consent.

Methodology:

After taking informed consent from patients or from their relatives/legally acceptable representatives, all parameters were assessed. Patients who referred to the department of radiology from ENT for getting CT scan of paranasal sinuses were considered the source of study population.

Groups:

Cases – 50 in number- patients with chronic rhinosinusitis in CT scan

Controls- 50 in number- patients without chronic rhinosinusitis in CT scan.

Prevalence and types of anatomical anomalies were assessed among all patients.

Statistical analysis:

Data were analyzed using SPSS 23.3 software. Mean, SD, percentages, and frequencies were used.

Students T test is used to compare numerical parameters between cases and controls and chi square test to know associations.

P value below 0.05 is considered significant statistically.

III. RESULTS

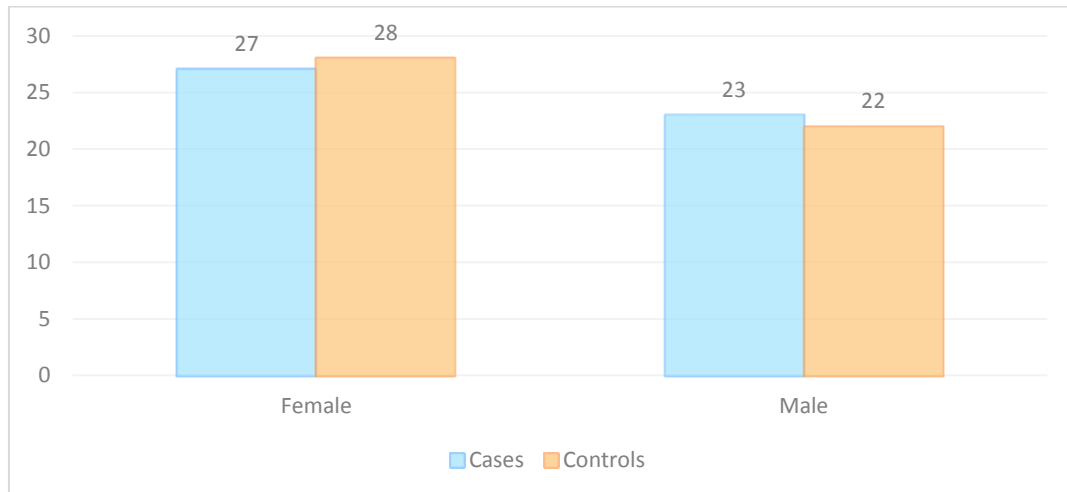
Mean age:

There is no significant difference in mean age of cases or controls.

Mean age			
Group	No of patients	Mean	Std Dev
Case	50.0000	38.7	12.47
Controls	50.0000	39.4	12.27

Table 1: Mean age of cases and controls (p=0.80 as per T test)

Gender: Overall 55% of patients were females. There is no significant difference in gender distribution of cases or controls.



Graph 1: Gender of patients

Chief complaint:

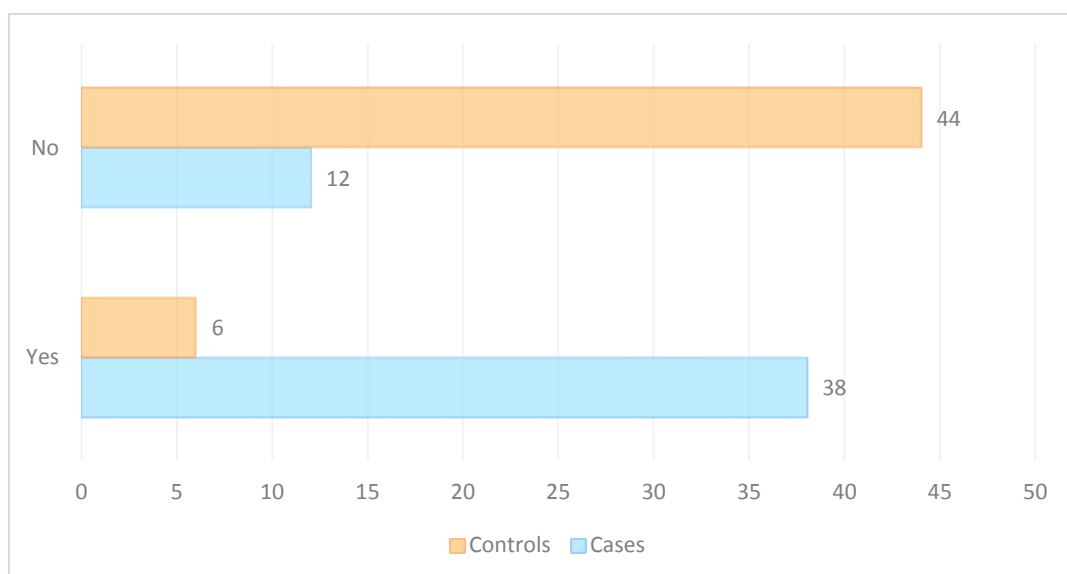
Most of the cases were presented with sinus pain and postnasal drip. Most of the controls presented with sneezing as chief complaint.

Chief complaint	Cases	Controls
Postnasal drip	8%	4%
Sinus pain	32%	4%
Sneezing	4%	32%
Headache	4%	6%
Others	2%	4%

Table 2: Chief complaint among cases and controls

Prevalence of anatomical variants:

Anatomical variants are more commonly seen among cases compared to controls. Overall prevalence was 44% out of which, 38% of anatomical variants are seen among cases ($p=0.0001$ as per chi square test). Anatomical variations are more commonly seen among cases compared to controls. This implies that anatomical variations are associated with the presence of chronic rhinosinusitis.



Graph 2: Prevalence of anatomical variants among cases and controls

Types of anatomical variants overall:

Nasal septal deviation is found to be the common anatomical variant, followed by Agger nasi and extension of sphenoid sinuses into posterior nasal septum.

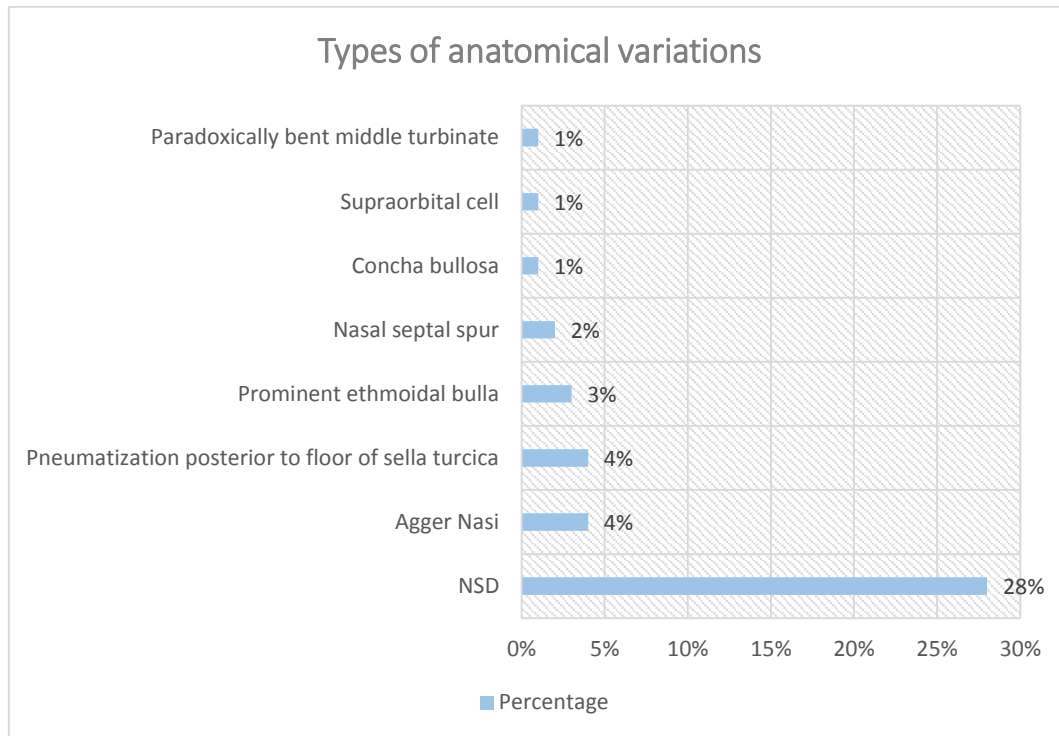
Nasal septal spur alone is seen in 2% of patients.

NSD alone is seen among 28% of patients overall.

Pneumatization posterior to sella turtica alone is seen among 4% of patients.

Agger nasi alone is seen in 4% of patients.

Prominent ethmoid bullae alone is seen in 3% of patients.



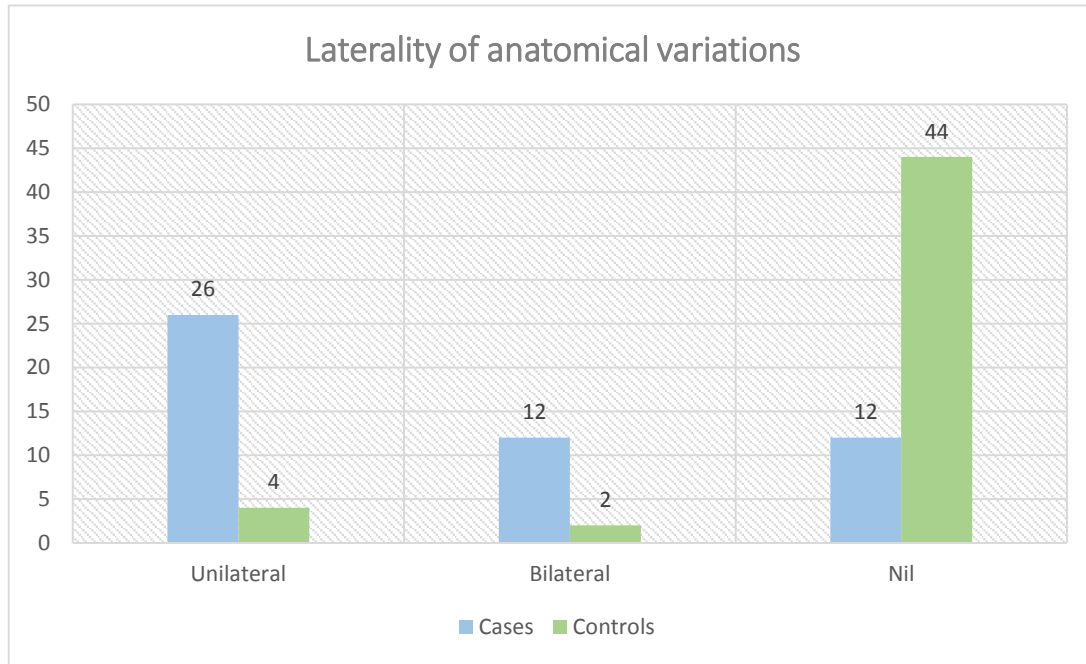
Graph 3: Types of anatomical variations

Laterality of anatomical variations:

Most of the patients had unilateral anatomical variations.

Overall 14% of patients had bilateral anatomical variations.

12 cases and 2 controls had bilateral anatomical variations.



Graph 4: Laterality of anatomical variations

Association of NSD with presence of chronic rhinosinusitis:

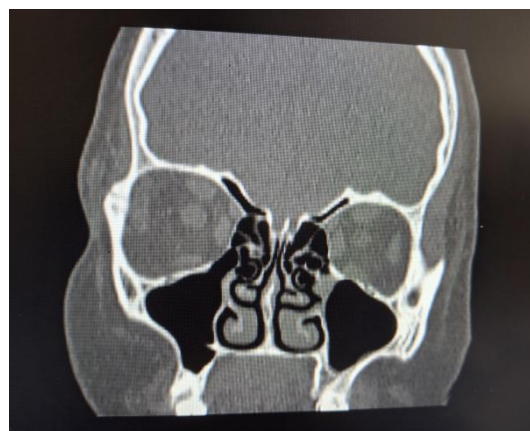There is a significant association between the presence of nasal septal deviation and chronic rhinosinusitis. It was more commonly seen among cases compared to controls.

	CASES	CONTROLS	<i>Marginal Row Totals</i>
NSD YES	22 (14)	6 (14)	28
NSD NO	28 (36)	44 (36)	72
<i>Marginal Column Totals</i>	50	50	100

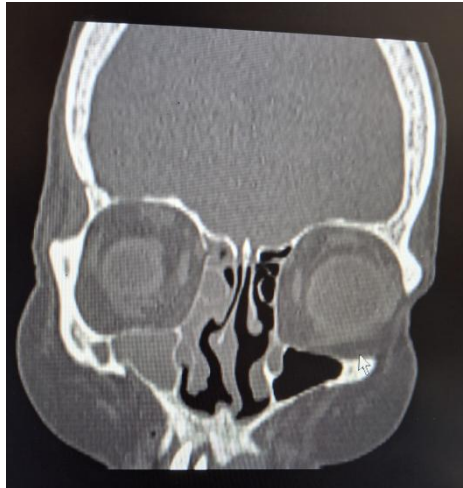The chi-square statistic is 12.684. The p-value is .000366. Significant at $p < .05$

Table 3: Association of NSD with chronic rhinosinusitis

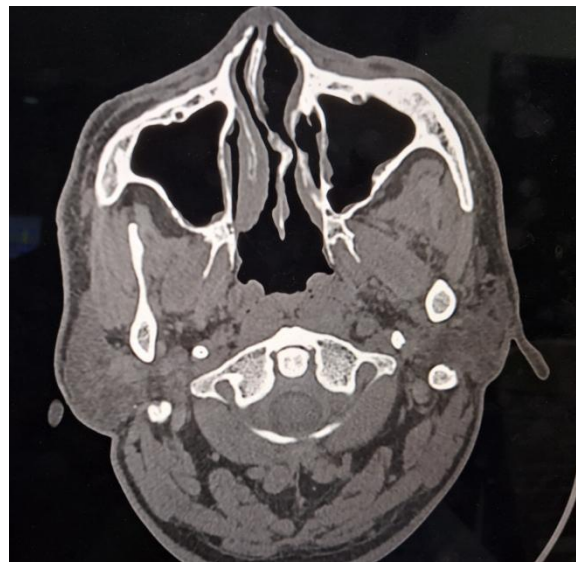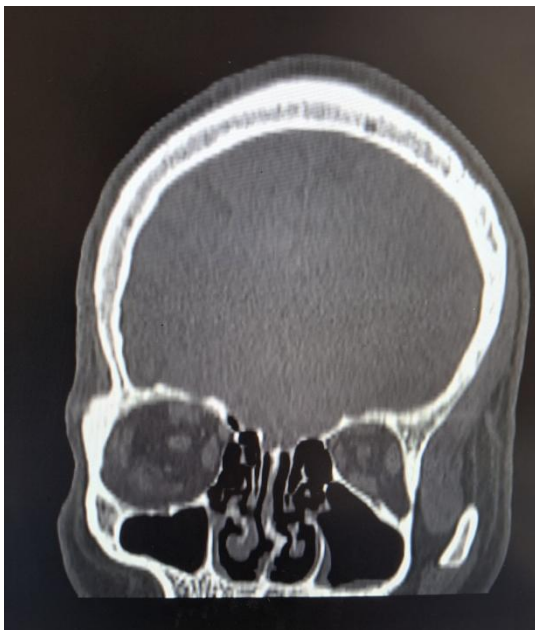FINDINGS IN THE CURRENT STUDY



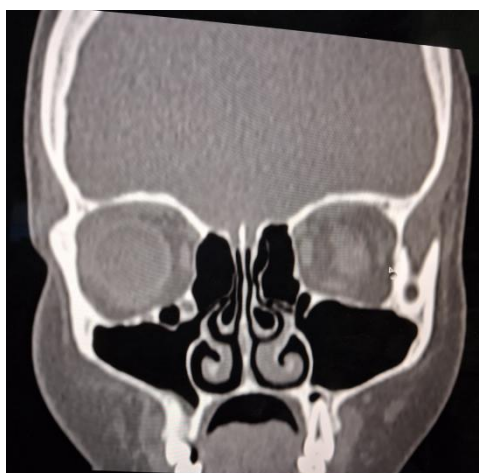Paradoxical curvature of middle turbinates



'S' shaped DNS



DNS with bony spur to left side



Concha bullosa on both sides

IV. DISCUSSION

There is no significant difference in the mean age or gender of cases and controls. The prevalence of anatomical variations among 100 patients was 44%. 38% of cases and 6% of controls had anatomical variations. There is a significant association between the presence of anatomical variations and chronic rhinosinusitis. The most common anatomical variation is nasal septal deviation. Unilateral anatomical variations are more common compared to bilateral anatomical variations. There is significant association between presence of deviated nasal septum and chronic rhinosinusitis.

Arslan et al did a study on 200 patients with chronic sinusitis. They determined the prevalence of anatomic variants. Supraorbital recess was found in 6% of cases, concha bullosa was seen among 30%, sphenomaxillary plate among 17% of patients, infra-orbital ethmoid cells in 6%, sphenoid cells in 12%, pneumatization of anterior clinoid process among 6% of patients, carotid artery bulging into sphenoid sinus was seen among 8% of patients, pneumatization of uncinat process was seen among 2% of patients, paradoxical curvature of the middle turbinate among 3% of patients, and septal deviation in 36%. difference in level between the ethmoid roof and nasal vault was 8 mm on the right side and 9.5 mm on the left side.¹⁷

In the study of **Devraja et al.**¹⁸ the most prevalent findings included DNS, CB, and pneumatized PB, seen among 83.4%, 49%, and 47% of patients. Rates of HC, OC, pneumatized septum, pneumatized CG were 39%, 23%, 27%, 43%, respectively. Maxillary sinus opacification correlated with DNS and CB, but not with tooth root protrusion into the sinus.

V. CONCLUSION

The prevalence of anatomical variations of sinonasal cavities are high. Routine screening of patients presenting with suspected rhinosinusitis symptoms with CT scan helps to identify various anatomic variants and thus helpful to plan surgery accordingly to minimize damage to adjacent structures.

The study is self-sponsored.

There were no conflicts of interest.

REFERENCES

- [1]. Hamid O, El Fiky L, Hassan O, Kotb A, El Fiky S. Anatomic variations of the sphenoid sinus and their impact on trans-sphenoid pituitary surgery. *Skull Base*. 2008;18:9–15.
- [2]. Mathew R, Omami G, Hand A, et al. Cone beam CT analysis of Haller cells: prevalence and clinical significance. *Dentomaxillofac Radiol*. 2013;42:20130055.
- [3]. Kantarci M, Karasen RM, Alper F, et al. Remarkable anatomic variations in paranasal sinus region and their clinical importance. *Eur J Radiol*. 2004;50:296–302.
- [4]. Stallman JS, Lobo JN, Som PM. The incidence of concha bullosa and its relationship to nasal septal deviation and paranasal sinus disease. *AJNR Am J Neuroradiol*. 2004;25:1613–1618.
- [5]. Beale TJ, Madani G, Morley SJ. Imaging of the paranasal sinuses and nasal cavity: normal anatomy and clinically relevant anatomical variants. *Semin Ultrasound CT MR*. 2009;30:2–16.
- [6]. Braun H, Stammberger H. Pneumatization of turbinates. *Laryngoscope*. 2003;113:668–672.
- [7]. Kanowitz SJ, Nusbaum AO, Jacobs JB, et al. Superior turbinate pneumatization in patients with chronic rhinosinusitis: prevalence on paranasal sinus CT. *Ear Nose Throat J*. 2008;87:578–579.
- [8]. Som PM, Park EE, Naidich TP, et al. Crista galli pneumatization is an extension of the adjacent frontal sinuses. *AJNR Am J Neuroradiol*. 2009;30:31–33.
- [9]. Comer BT, Kincaid NW, Smith NJ, et al. Frontal sinus septations predict the presence of supraorbital ethmoid cells. *Laryngoscope*. 2013;123:2090–2093.
- [10]. Alkire BC, Bhattacharyya N. An assessment of sinonasal anatomic variants potentially associated with recurrent acute rhinosinusitis. *Laryngoscope*. 2010;120:631–634.
- [11]. Sivasli E, Sirikçi A, Bayazıt YA, et al. Anatomic variations of the paranasal sinus area in pediatric patients with chronic sinusitis. *Surg Radiol Anat*. 2003;24:400–405.
- [12]. Azila A, Irfan M, Rohaizan Y, et al. The prevalence of anatomical variations in osteomeatal unit in patients with chronic rhinosinusitis. *Med J Malaysia*. 2011;66:191–194.
- [13]. Fadda GL, Rosso S, Aversa S, et al. Multiparametric statistical correlations between paranasal sinus anatomic variations and chronic rhinosinusitis. *Acta Otorhinolaryngol Ital*. 2012;32:244–251.
- [14]. Stallman JS, Lobo JN, Som PM. The incidence of concha bullosa and its relationship to nasal septal deviation and paranasal sinus disease. *AJNR Am J Neuroradiol*. 2004;25:1613–1618.
- [15]. Eweiss AZ, Khalil HS. The prevalence of frontal cells and their relation to frontal sinusitis: a radiological study of the frontal recess area. *ISRN Otolaryngol*. 2013;2013:687582.
- [16]. Mathew R, Omami G, Hand A, et al. Cone beam CT analysis of Haller cells: prevalence and clinical significance. *Dentomaxillofac Radiol*. 2013;42:20130055.
- [17]. Arslan H, Aydınlioğlu A, Bozkurt M, Egeli E. Anatomic variations of the paranasal sinuses: CT examination for endoscopic sinus surgery. *Auris Nasus Larynx*. 1999;26(1):39–48. Available from: [http://dx.doi.org/10.1016/s0385-8146\(98\)00024-8](http://dx.doi.org/10.1016/s0385-8146(98)00024-8).
- [18]. Devaraja K, Doreswamy SM, Pujary K, et al. Anatomical Variations of the Nose and Paranasal Sinuses: A Computed Tomographic Study. *Indian J Otolaryngol Head Neck Surg*. 2019;71(Suppl 3):2231–2240. <https://doi.org/10.1007/s12070-019-01716-9>.