

Alcohol As A Treatment For Thyroid Cysts

Pr. J. Issouani (A), Dr. H. Srifi (B), Dr. L. Louday, Pr. Y. ERRHALI (B),
Pr. AA. Guerboub (B)

(A) Endocrinology-Dialectology Departement In Mohammed V Military Hospital , University Hassan II,
Casablanca.

(B) Endocrinology-Dialectology Departement In Mohammed V Military Hospital , University Mohamed V
Souissi, Rabat

Date of Submission: 08-07-2024

Date of Acceptance: 18-07-2024

I. Introduction :

Thyroid cysts are mostly benign lesions that can produce compressive or cosmetic symptoms depending on the size and location and are characterized by their fluid content. A new minimally invasive ultrasound-guided technique known as ethanol injection therapy (Alcohol) has been proposed as a safe and effective conservative alternative to open surgery, with significant improvement in symptoms and quality of life. (1,2)

Ethanol ablation for the treatment of thyroid cysts has been well documented in the literature as a safe and effective treatment option. In this article, we share our experience with ethanol treatment of thyroid cysts.

II. Material And Methods :

A series of 13 patients presenting a cervical nodule or nodular goiter with a compressive cystic component and treated in the endocrinology department of the Mohammed V military hospital in Rabat, were prospectively included in the study.

A case was considered for alcoholism if it met all of the following criteria: (1) age > 18 years; (2) normal thyroid status; (3) no major comorbidities; (4) no history of neck irradiation; (5) cystic or predominantly cystic (>80% cystic component) thyroid nodule recurrent after the first simple drainage; (6) a benign cytopathological study and (7) compressive symptoms. All patients have been followed for at least 6 months.

Alcoholization By Ethanol:

An ultrasound examination was performed on each patient by an experienced endocrinologist-sonographer using a 10--18 MHz linear probe (ESAOTE). The morphological evaluation included the description of the thyroid echostructure and the measurement of the diameters and ultrasound characteristics of each nodule detected. Fine needle aspiration (FNA) was performed in all cases to obtain cytological samples and exclude malignancy and also to drain the fluid contents of the cyst (3,4). Patients were offered alcohol treatment if the cyst recurred with reappearance of compressive symptoms or cosmetic complaints after the first drainage and if the cytological analysis of the aspiration fluid was benign and if the patient preferred not to undergo thyroid surgery afterward. an explanation of the procedure.

All alcohol procedures were performed by the same operator, the positions of the patient and operator were similar to those adopted during the fine needle puncture procedure, with the patient lying supine with the neck in hyperextension (5).

After the Sterilization of the skin, and under ultrasound control, a 21 gauge needle (0.5--0.8 mm) mounted on a 20 ml syringe was used to empty the cyst contents.

Subsequently, 96% ethanol was injected gradually, with slow movement of the needle to reach most of the inner surface of the cyst capsule. The patient was instructed to report any sensation of pain. The quantity of ethanol injected was approximately 30% of the volume of liquid extracted, with a maximum of 3 ml. The needle tip was continuously monitored during the procedure to ensure that it remained in the cyst (6). Ethanol was not re-extracted and patients were discharged after 15--20 minutes observation

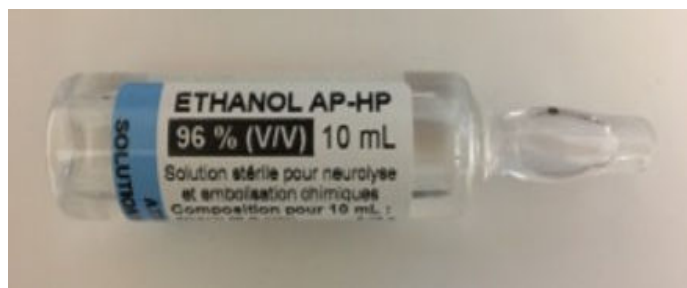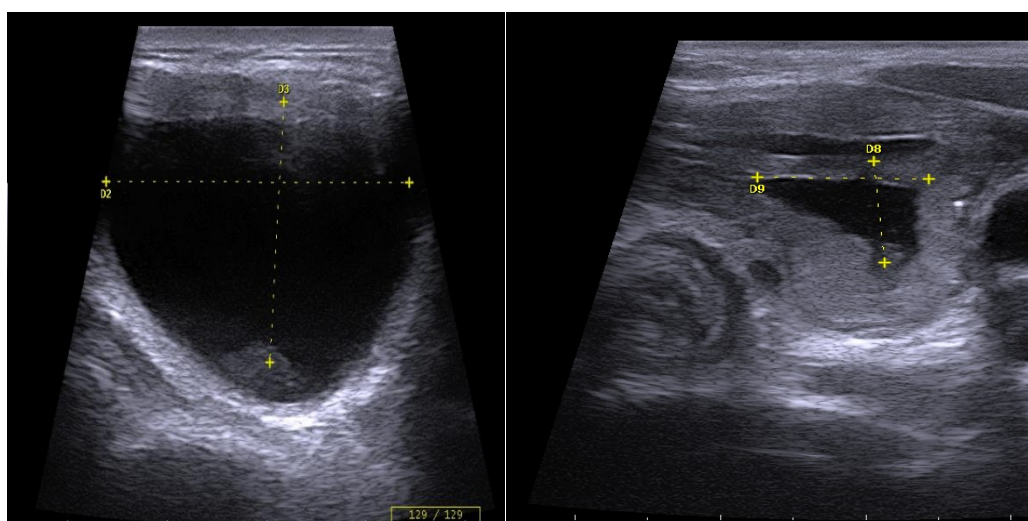


Figure 1: 10 ml ampoule of AP-HP 96% ethanol for parenteral use.

Follow-Up

Patients were followed monthly for three months and every three months thereafter. An ultrasound was performed at each appointment with an evaluation of the characteristics and volume of the residual lesion.

In case of recurrence confirmed by ultrasound, a new alcoholization was carried out with the same protocol, this procedure was repeated until a permanent and significant reduction of the cyst, defined as complete resorption or a reduction of at least 50% by compared to the initial value with a significant reduction in symptoms (7.8).



Patient 1: Thyroid cyst before alcohol use

Patient 1: Thyroid cyst after evacuation and alcohol use

Figure 2 (Patient 1): thyroid cyst before and after alcohol use

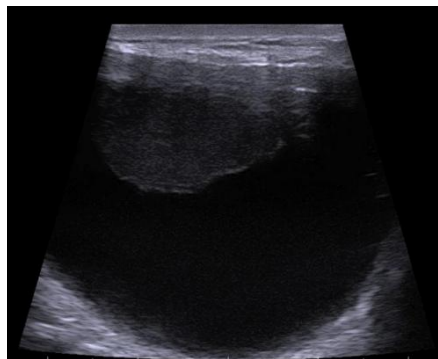
III. Results

In our series of 13 patients, three cases (23%) presented a recurrence of thyroid cyst after drainage, alcoholization and collection of samples for cytological evaluation.

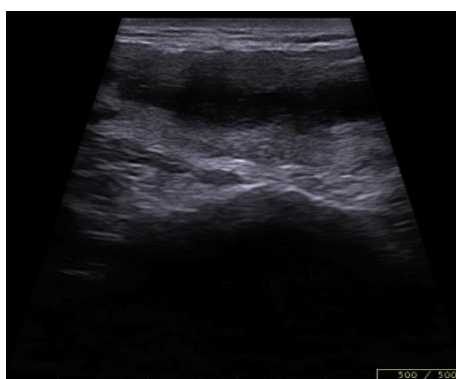A total of 13 subjects with symptomatic thyroid cysts (16 - 54 years; 84% female) were included in the protocol. The mean TSH was within the normal range (2.0 ± 1.4 mU/L) and positive antithyroperoxidase and/or anti-thyroglobulin antibodies were detected in 14% of patients. The symptoms most frequently reported by patients were compressive (85%) and anesthetic (70%), symptoms and sore throat (28%).

The intensity of symptoms was “mild” in 28% of patients, “moderate” in 40% and “intense” in 32%. Regarding cyst type, 60% were pure fluid lesions with a capsule, 20% were septate cysts, and 20% were mixed but predominantly cystic nodules. Cytological studies of the samples obtained by fine needle aspiration cytology from the cystic nodules were benign (hemorrhagic-cystic lesion, colloid or non-malignant lesion) in all cases.

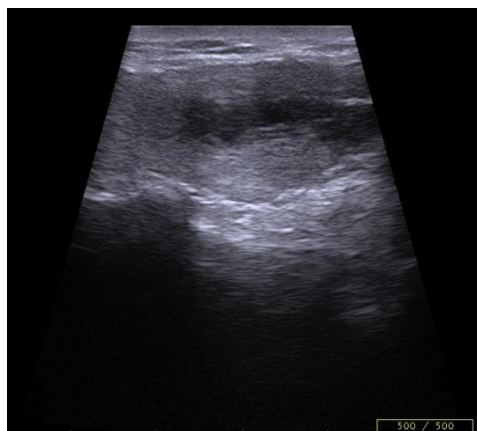
The mean maximum cyst diameter before drainage was 3.1 ± 1.1 cm with a calculated median initial volume of 14.2 (5.1---18.3) ml. Median total volume removed from the cyst in all procedures performed in a patient was 15.0 (8.2---37.0) ml.



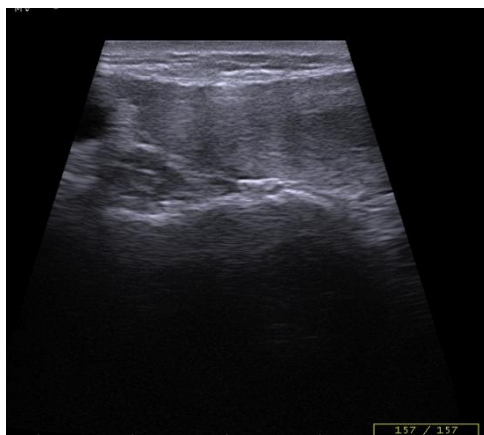
Patient 1 : Thyroidien Cyst Day 1



Patient 1 : Thyroidien Cyst Day 7 Post Alcolisation



Patient 1 : Thyroidien Cyst Day 30 Post Alcolisation



Patient 1 : Thyroidien Cyst Day 90 Post Alcolisation

Figure 3 : Thyroidien Cyst À Day1, Day7, Day30, Day90 Post Alcolisation

IV. Discussion

The results presented in this article clearly demonstrate that alcoholization with ethanol is a safe procedure with long-term effectiveness in cases of symptomatic benign thyroid cysts that allows a significant reduction in cyst volume and complete disappearance of symptoms in virtually all cases. All patients without significant complications.

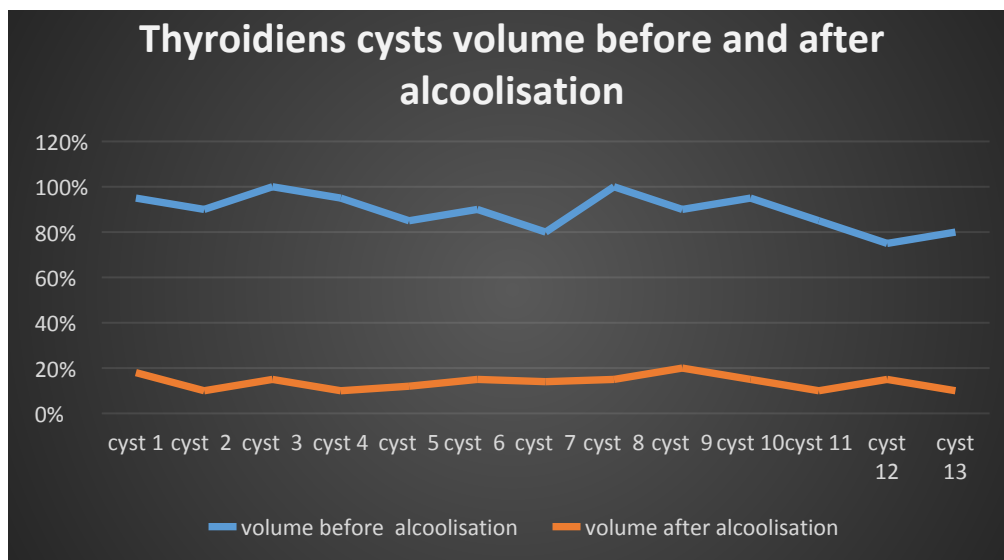


Figure 4: Evolution Of The Volume Of Thyroid Cysts Treated By Percutaneous Injection Of Ethanol.

V. Conclusion:

Ethanol alcoholization is a safe and well-tolerated first-line treatment for symptomatic thyroid cysts with long-term effectiveness, our experience allows us to offer ethanol alcoholization as a safe and effective alternative to surgery in the management of thyroid cysts.

References :

- [1] Gharib H, Hegedüs L, Pacella CM, Baek JH, Papini E. Nonsurgical, Image-Guided, Minimally Invasive Therapy For Thyroid Nodules. *J Clin Endocrinol Metab.* 2013;98:3949---57, [Http://Dx.Doi.Org/10.1210/Jc.2013-1806](http://dx.doi.org/10.1210/jc.2013-1806) [Clinical Review].
- [2] Reverter JL, Alonso N, Avila M, Lucas A, Mauricio D, Puig-Domingo M. Evaluation Of Efficacy, Safety, Pain Perception And Health-Related Quality Of Life Of Percutaneous Ethanol Injection As First-Line Treatment In Symptomatic Thyroid Cysts. *BMC Endocr Disord.* 2015;15:73, [Http://Dx.Doi.Org/10.1186/S12902-015-0069-3](http://dx.doi.org/10.1186/S12902-015-0069-3).
- [3] Monzani F, Lippi F, Goletti O, Del Guerra P, Caraccio N, Lippolis, PV, Et Al. Percutaneous Aspiration And Ethanol Sclerotherapy For Thyroid Cysts. *J Clin Endocrinol Metab.* 1994;78:800---2, [Http://Dx.Doi.Org/10.1210/Jcem.78.3.8126160](http://dx.doi.org/10.1210/jcem.78.3.8126160).
- [4] Cho YS, Lee HK, Ahn IM, Lim SM, Kim DH, Choi CG, Et Al. Sonographically Guided Ethanol Sclerotherapy For Benign Thyroid Cysts: Results In 22, Patients. *AJR Am J Roentgenol.* 2000;174:213---6, [Http://Dx.Doi.Org/10.2214/Ajr.174.1.1740213](http://dx.doi.org/10.2214/Ajr.174.1.1740213).
- [5] Guglielmi R, Pacella CM, Bianchini, Bizzarri G, Rinaldi R, Graziano FMA, Et Al. Percutaneous Ethanol Injection Treatment In Benign Thyroid Lesions: Role And Efficacy. *Thyroid.* 2004;14:125---31, [Http://Dx.Doi.Org/10.1089/105072504322880364](http://dx.doi.org/10.1089/105072504322880364).
- [6] Valcavi R, Frasoldati A. Ultrasound-Guided Percutaneous Ethanol Injection Therapy In Thyroid Cystic Nodules. *Endocr Pract.* 2004;10:269---75, [Http://Dx.Doi.Org/10.4158/EP.10.3.269](http://dx.doi.org/10.4158/EP.10.3.269).
- [7] Gharib H, Hegedüs L, Pacella CM, Baek JH, Papini E. Nonsurgical, Image-Guided, Minimally Invasive Therapy For Thyroid Nodules. *J Clin Endocrinol Metab.* 2013;98:3949---57, [Http://Dx.Doi.Org/10.1210/Jc.2013-1806](http://dx.doi.org/10.1210/jc.2013-1806) [Clinical Review].
- [8] Reverter JL, Alonso N, Avila M, Lucas A, Mauricio D, Puig-Domingo M. Evaluation Of Efficacy, Safety, Pain Perception And Health-Related Quality Of Life Of Percuta-241 11, 2023.