

Surgical Repositioning Of Traumatically Intruded Permanent Maxillary Central Incisor: A Case Report

Ashwija Shetty¹, Champa C², Srirekha A³, Hajira Anjum Sultana⁴,
Kameshwari R A⁵, Keerthan Bhat V⁶.

¹(Professor, Department Of Conservative Dentistry And Endodontics, The Oxford Dental College, India)

²(Professor, Department Of Conservative Dentistry And Endodontics, The Oxford Dental College, India)

³(Professor And Head, Department Of Conservative Dentistry And Endodontics, The Oxford Dental College, India)

⁴(Postgraduate, Department Of Conservative Dentistry And Endodontics, The Oxford Dental College, India)

⁵(Postgraduate, Department Of Conservative Dentistry And Endodontics, The Oxford Dental College, India)

⁶(Postgraduate, Department Of Conservative Dentistry And Endodontics, The Oxford Dental College, India)

Abstract

Intrusive luxation, although rare in permanent teeth, is considered a highly concerning dental injury due to its potential for significant damage to the periodontal ligament, pulp and alveolar bone. The optimal treatment approach for intrusive luxation in permanent teeth remains a topic of debate. This report presents a case of severe intrusive luxation of permanent maxillary central incisor in a 37-year-old female. The intruded tooth was surgically repositioned and splint with a 0.7 mm stainless steel orthodontic wire and composite from canine to canine on the labial surface. Definitive root canal treatment was accomplished at a later appointment. Splint was removed a month later. Clinical and radiographic examination 3 months after the surgical repositioning revealed satisfactory apical and periodontal healing.

Key Word: Intrusion, permanent incisor, surgical repositioning

Date of Submission: 05-08-2024

Date of Acceptance: 15-08-2024

I. Introduction

Intrusive luxation is a rare but challenging dental injury that requires prompt and careful consideration. Intrusive luxation accounts for only 0.5%– 2% of all traumatic injuries in permanent teeth and 5%–12% of dental luxations.^{1,2} When faced with this type of dental emergency, the care of the affected tooth poses a significant challenge, as the treatment plan must be based on a thorough evaluation of various factors.

Intrusive luxation is a type of dental trauma that results in the axial displacement of a tooth into the alveolar bone.³ Intrusion of permanent anterior teeth can cause serious damage to the tooth and/or surrounding tissues. While mild intrusions can heal with periodontal regeneration, common healing outcomes include root resorption, ankylosis, marginal bone loss, pulp canal obliteration and pulp necrosis.⁴

The course of treatment and prognosis for intrusive dental trauma depends on several factors, including; age, dentition type, root development, time and severity of trauma.⁵ The treatment of traumatic injuries in permanent teeth may include monitoring for spontaneous eruption if the amount of intrusion is less than 3 mm in teeth with open apex. For moderate intrusions (3-7 mm), orthodontic repositioning can be considered and in severe cases (more than 7 mm) orthodontic or surgical repositioning may be necessary.⁶

Following trauma, teeth with open apices exhibit a higher likelihood of maintaining pulpal vitality after intervention compared to those with closed apices, where pulp necrosis becomes a more probable outcome. Periapical tissues frequently demonstrate signs of infection and ankylosis-related resorption. This complication, ankylosis, can manifest even after a 5–10 years period. Prompt management of all traumatic dental injuries is crucial for patient comfort and minimizing wound healing complications.⁶

This report describes the management of a severe traumatic intrusion of a maxillary permanent central incisor treated with surgical repositioning.

II. Case Report

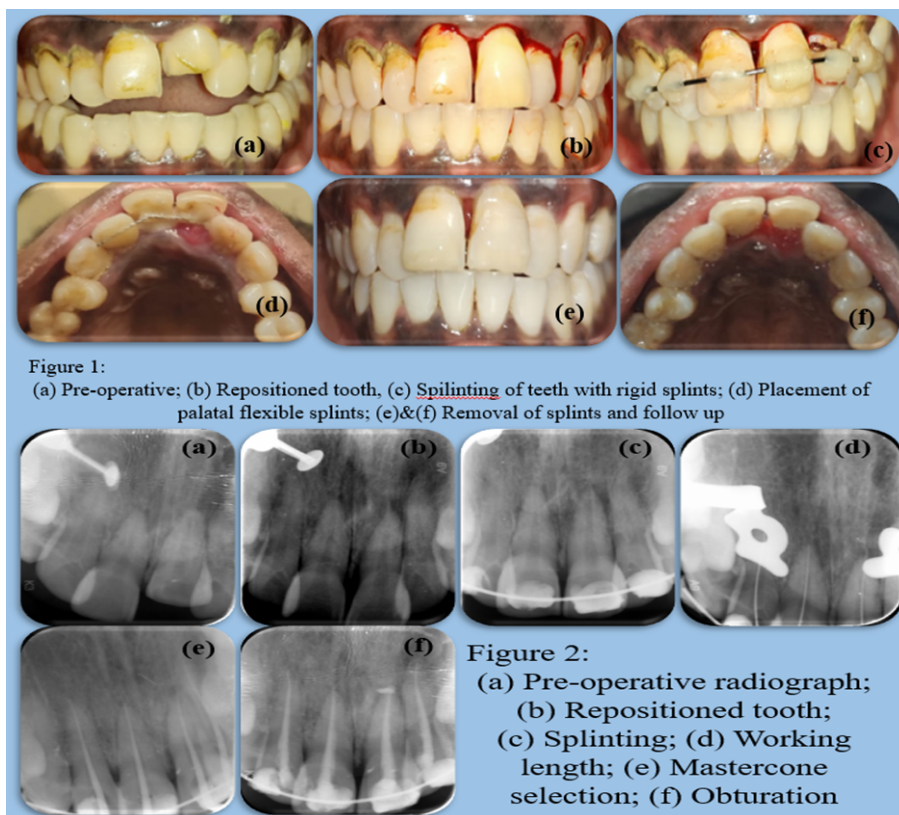
A 37-year-old female patient reported to the Department of Conservative Dentistry and Endodontics complaining of pain in her upper front tooth region since a day. Patient gave a history of trauma a day ago in the same region following a fall. Clinical examination, revealed that the injury had resulted in 7 mm intrusion of

permanent maxillary left central incisor [figure 1(a) & figure 2(a)]. No other injuries were noted in the alveolar bone, surrounding teeth or soft tissues. The tooth showed grade 2 mobility.

Due to the severity of intrusion and completed root development, surgical repositioning of left central incisor was planned. After administering local anaesthesia (Lignocaine and Epinephrine 1:80,000), the intruded tooth was luxated gently with an elevator to minimize cell damage to the periodontal ligament and the cementum. The intruded tooth was repositioned with dental extraction forceps [figure 1(b) & figure 2(b)] and splinted with 0.7 mm stainless steel orthodontic wire and composite resin from canine to canine on the labial surface [figure 1(c) & figure 2(c)]. The patient was prescribed antibiotics (amoxicillin 500 mg, three times a day for five days), analgesics and a mouth rinse (0.2% chlorhexidine gluconate two times a day for seven days). She was warned to avoid biting from her anterior teeth. The patient was recalled after a week.

In the subsequent visit, the healing was evaluated and pulp sensibility was assessed with cold test. The teeth 11,12 and 22 showed delayed response; whereas the tooth 21 showed no response. Hence, root canal treatment was initiated irt 11,12,21 and 22 under rubber dam isolation, following administration of local anaesthesia. Working length was determined with apex locator and confirmed with digital radiographs [figure 2(d)]. The canals were cleaned and shaped to a size 25/6% along with copious irrigation with 2.5% sodium hypochlorite and normal saline. The canals were dressed with an intracanal medicament of calcium hydroxide and access cavity was sealed with temporary restoration. The patient was recalled after 1 week. In the following visit, mastercone was selected [figure 2(e)] and the canals were obturated with single cone obturation using gutta percha and bioceramic sealer (Angelus Bio-C sealer) [figure 2(f)].

At the 4-week follow-up appointment, healing was assessed. The access cavities were restored with composite resin and the rigid splints were removed. Because the tooth still had grade 1 mobility, flexible splints made with braided orthodontic ligature wire and composite resin were placed palatally from the right lateral incisor to the left lateral incisor [figure 1(d), figure 2(g)]. The patient was recalled after 15 days, healing was assessed and the splints were removed [figure 1 (e & f)]. The tooth was not tender to percussion and did not demonstrate any mobility. At the 3-month recall, the tooth was stable and asymptomatic. [figure 2(h)]



III. Discussion

The key factors that determine the treatment outcome in intrusion injuries are i) the stage of root development of the affected tooth, ii) the degree of intrusion, iii) the time interval between the trauma and the treatment.

When treating permanent intruded teeth, three modalities are commonly used: spontaneous eruption, orthodontic extrusion and surgical repositioning. For moderate intrusions (3-7 mm), re-positioning through

surgery or orthodontics is recommended, while severe intrusions (greater than 7 mm) typically require surgical repositioning. The critical period for treating intrusion injuries is the first 2-3 weeks.⁶ Studies have shown that if root canal treatment is not initiated during this time frame, external root resorption may occur. Also, surgical extrusion enables rapid positioning of the tooth.⁷⁻¹⁰ Hence, surgical re-positioning was considered as the treatment in the present case report as the intrusion caused by the trauma was 7 mm.

Literature states that the incidence of pulp necrosis in teeth with closed root apices is reported to be 96%. Initial pulp sensibility tests following trauma may be non-responsive, potentially reflecting a temporary suppression of pulpal response rather than confirmed necrosis. Hence, the sensibility test was carried out in the following visit and root canal treatment was initiated promptly to prevent inflammatory root resorption.¹¹ When calcium hydroxide is applied as a medicament into the canal after trauma, it helps to prevent internal resorptions and infection-related root resorption.¹² Hence, we employed calcium hydroxide in the intermediate sessions to benefit from its antibacterial property.

The prognosis of intrusion cases is majorly dependent on the post-operative care taken. Splinting is considered as a viable option to allow the healing required during the initial stages of the post-operative period. Keeping the splint duration short helps prevent ankylosis. Since grade 2 mobility was seen in the present case report, stainless steel-composite splints were considered. Berude et al. conducted a study comparing periodontal healing in teeth with no splint, semi-rigid splint, or rigid splint and found no significant difference among these three types.^{13,14} Since the follow-up examination revealed grade I mobility of the teeth, flexible splints were applied. These splints were chosen specifically because they stabilize the teeth within the socket while still allowing for controlled functional movement, which can stimulate the healing of the surrounding periodontal tissues.¹⁵

The surgical technique for managing intruded teeth offers several advantages. Firstly, it allows easy repositioning, restoring the original anatomical alignment for optimal healing of adjacent tissues. Additionally, it provides sufficient space for endodontic access. However, there are potential drawbacks, including inadvertent ex-articulation during repositioning and the risk of additional damage to the periodontal ligament, which may increase the likelihood of ankylosis. Minimizing these risks depends on the operator's skill and caution.

IV. Conclusions

Rehabilitation of internal luxation is quite challenging due to the degree of penetration caused by the trauma. In the present case report, surgical re-positioning proved to be successful without any additional risk. However, long term follow up is crucial for the prognosis of the treatment.

References

- [1] Andreasen Jo, Bakland Lk, Andreasen Fm. Traumatic Intrusion Of Permanent Teeth. Part 2. A Clinical Study Of The Effect Of Preinjury And Injury Factors, Such As Sex, Age, Stage Of Root Development, Tooth Location, And Extent Of Injury Including Number Of Intruded Teeth On 140 Intruded Permanent Teeth. *Dent Traumatol.* 2006;22:90-8
- [2] De Alencar Ah, Lustosa-Pereira A, De Sousa Ha, Figueiredo Jh. Intrusive Luxation: A Case Report. *Dent Traumatol.* 2007;23:307-12
- [3] Silva Hg, Costa Vpp, Goettems Ml. Prognosis Of Primary Teeth Following Intrusive Luxation According To The Degree Of Intrusion: A Retrospective Cohort Study. *Dent Traumatol.* 2022;38(1):34-40.
- [4] Alqadi Sf, Alekhmimi Rk, Felemban Df, Almuzaini Sa, Bafail As, Zain-Alabdeen Eh. Management Of Severe Traumatic Intrusion Of The Permanent Upper Central Incisor: A Case Report. *Egypt. Dent. J.* 2024;70(2):1091-8.
- [5] Güngör Hc, Cengiz Sb, Altay N. Immediate Surgical Repositioning Following Intrusive Luxation: A Case Report And Review Of The Literature. *Dent Traumatol* 2006;22(6):340-4.
- [6] Belevcikli M, Altan A, Altan H. Surgical Extrusion Of Anterior Teeth With Intrusion Traumatic Injury: A Report Of Two Cases. *Eur Endod J* 2020;3:295-9.
- [7] Kinirons Mj. Uk National Clinical Guidelines In Paediatric Dentistry: Treatment Of Traumatically Intruded Permanent Incisor Teeth In Children. *Int J Paediatr Dent* 1998; 8:165-8.
- [8] Faria G, Silva Ra, Fiori-Júnior M, Nelson-Filho P. Re-Eruption Of Traumatically Intruded Mature Permanent Incisor: Case Report. *Dent Traumatol* 2004;20(4):229-32.
- [9] Oulis C, Vadiakas G, Siskos G. Management Of Intrusive Luxation Injuries. *Endod Dent Traumatol* 1996; 12(3):113-9.
- [10] Shivayogi Mh, Anand Ls, Dayanand Ds. Management Of Traumatically Intruded Permanent Incisors. *J Indian Soc Pedod Prev Dent* 2007;25 Suppl:S13-6.
- [11] Diangelis Aj, Andreasen Jo, Ebeleseder Ka, Kenny Dj, Trope M, Sigurdsson A, Et Al. International Association Of Dental Traumatology. International Association Of Dental Traumatology Guidelines For The Management Of Traumatic Dental Injuries: 1. Fractures And Luxations Of Permanent Teeth. *Dent Traumatol.* 2012;28(1):2-12.
- [12] Mohammadi Z, Dummer Pm. Properties And Applications Of Calcium Hydroxide In Endodontics And Dental Traumatology. *Int Endod J.* 2011;44(8):697-730.
- [13] Berude Ja, Hicks Ml, Sauber Jj, Li Sh. Resorption After Physiological And Rigid Splinting Of Replanted Permanent Incisors In Monkeys. *J Endod.* 1988;14(12):592-600.
- [14] Ebeleseder Ka, Santler G, Glockner K, Hulla H, Pertl C, Quehenberger F. An Analysis Of 58 Traumatically Intruded And Surgically Extruded Permanent Teeth. *Endod Dent Traumatol.* 2000;16(1):34-9.
- [15] Kahler B, Heithersay Gs. An Evidence-Based Appraisal Of Splinting Luxated, Avulsed And Root-Fractured Teeth. *Dent Traumatol.* 2008;24(1):2-10

