

Full mouth rehabilitation of a patient with Restorative Space Issues and loss of VDO by replacing maxillary arch with fixed prosthesis opposing a flexible removable partial denture in mandibular arch: A case report

Dr. Shyamolima Hazarika¹, Dr. Kaushik Kumar Pandey², Dr. Asra Ahmed³,
Dr. Sana Sanober⁴, Dr Moazzam Kidwai⁵

1. Post Graduate Student, Department of Prosthodontics, Career Institute of Dental Sciences and Hospital, Lucknow, Uttar Pradesh, India

2. Professor, Department of Prosthodontics, Career Institute of Dental Sciences and Hospital, Lucknow, Uttar Pradesh, India

3. Post Graduate Student, Department of Prosthodontics, Career Institute of Dental Sciences and Hospital, Lucknow, Uttar Pradesh, India

4. Post Graduate Student, Career Institute of Dental Sciences and Hospital, Lucknow, Uttar Pradesh, India

5. Post Graduate Student, Department of Prosthodontics, Career Institute of Dental Sciences and Hospital, Lucknow, Uttar Pradesh, India

ABSTRACT

Primary objective of full mouth rehabilitation is the restoring the teeth to optimal physiological and functional balance. Planning a comprehensive course of treatment for a number of missing teeth can be difficult, particularly when the vertical dimension (VD) of the occlusion is reduced. In this case report the sequential methodical interdisciplinary approach employed to treat multiple missing teeth with a loss of VD is described. The patient receives a temporary prosthesis by increasing the vertical dimension. A definitive reconstruction using a fixed prosthesis in the maxillary arch and mandibular ant region and a flexible partial denture in the mandibular arch was carried out following validation of the newly established restorative vertical dimension. A dentist can improve a patient's quality of life by providing functional harmony and aesthetic comfort through appropriate diagnosis and treatment planning.

Date of Submission: 27-08-2024

Date of Acceptance: 05-09-2024

I. INTRODUCTION

Restoring teeth in a physiological and functionally harmonious manner is the aim of **full mouth restoration**. In cases of reduced vertical dimension (VD) of occlusion, comprehensive treatment planning becomes especially challenging for multiple missing teeth. It involves a number of prosthodontic considerations such as analysis of the existing occlusion and occlusal plane; availability of freeway space; size and location of edentulous areas; number, position and condition of the teeth in each arch; the need for altering the vertical dimensions and restoration of function and esthetics¹.

The term "restorative space" describes the amount of space required, both horizontally and vertically, between the crest of the residual ridge and the occluding surface of the teeth in order to fabricate fixed or removable restorations without sacrificing their strength or appearance. Before beginning prosthetic treatment, it is important to carefully evaluate the amount of available restorative space².

Patients with progressive tooth wear, where compensatory eruption of teeth and alveolar processes occurs to maintain occlusal contact and prevent loss of the vertical dimension of occlusion (VDO), exhibit reduced restorative space. Most of the times, patient without tooth wear also exhibits reduction in restorative plane which can be due to prolonged edentulous span which results in inclined occlusion plane^{3,4}. Accurate clinical and radiographic examinations, careful determination of VDO and systematic treatment planning using a diagnostic wax-up is key to predictable and successful treatment for patients with restorative space issues².

This clinical report describes the esthetic and functional rehabilitation of a patient with vertical loss due multiple missing teeth with reduced restorative space. Here full mouth rehabilitation was accomplished successfully, by combining the concept of fixed prosthodontics and removable prosthodontics.

Case report

A 45 year old female patient reported to department of prosthodontics ,career post graduate institute of dental sciences with chief complaint difficulty in chewing food due to multiple missing teeth.Patient was apparently asymptomatic 1 year back, then she visited to the dentist 1 year back for the extraction irt 16,34,35,36,37,46,47 due to lost of periodontal support and dental caries.The patient gave no significant medical history.

On extra oral examination, TMJ showed no deviation from normal movement and no clicking sound. Lymph nodes appeared normal on palpation. Patient had convex facial profile with decreased lower facial height.

On intra oral examination, it was observed that patient had fair oral hygiene.Missing teeth were 16,34,35,36,37,46,47 . There were root pieces with respect to 12 and 45[fig 1].Occlusal caries was noted irt 47. It was found that grade III mobility was seen irt 31,32,41,42. This was a diagnosed case of partially edentulous maxillary and mandibular arch with loss of vertical dimension with multiple missing teeth and high well rounded ridge over edentulous mandibular arch.

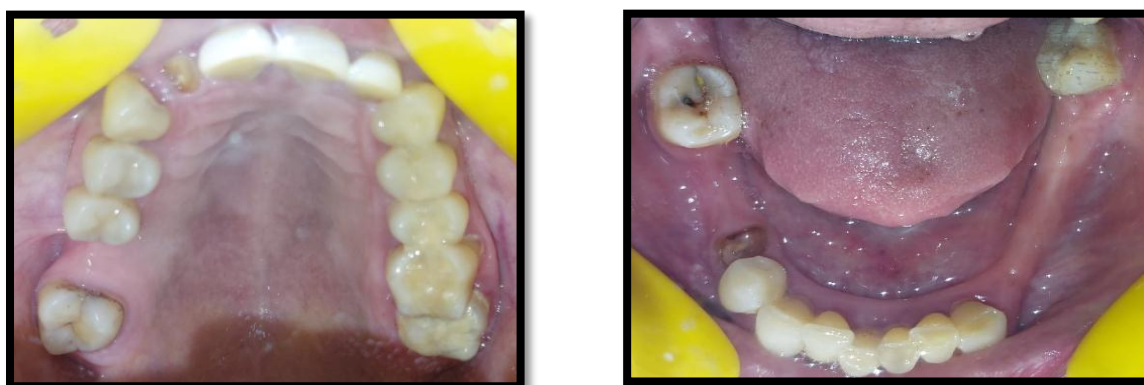

Fig 1

Patient was informed about the need for few extraction, crown lengthening and replacement of the teeth. Various treatment options like removable partial denture, cast partial denture, implant supported removable prosthesis and implant supported fixed prosthesis were explained to the patient and the advantages and disadvantages were discussed. Patient was not willing for implant supported fixed or removable prosthesis and opted for a fixed prosthesis in maxillary arch opposing flexible denture in mandibular arch.

For the maxillary arch, extraction of 12, surgical crown lengthening with 13,11,21,22,23,24,25 ,32 and followed by esthetic correction of remaining teeth with crowns and fixed dental prosthesis. In the mandibular arch, extraction of 31,32,41,42,surgical crown lengthening of 33,43,44 and followed by esthetic correction of 31,32,33,41,42,43,44 with fabrication of fixed dental prosthesis. For mandibular posterior region flexible removable partial denture was planned ,as the patient was not willing for implant supported fixed or removale prosthesis because of her weak economical background so the option of implant installation was excluded and the removable cast partial denture option was also excluded as she felt that the framework would be heavy.

Procedure

1.Preliminary impression were made with irreversible hydrocolloid poured with dental stone and diagnostic cast were fabricated.[Figure 2 & 3]

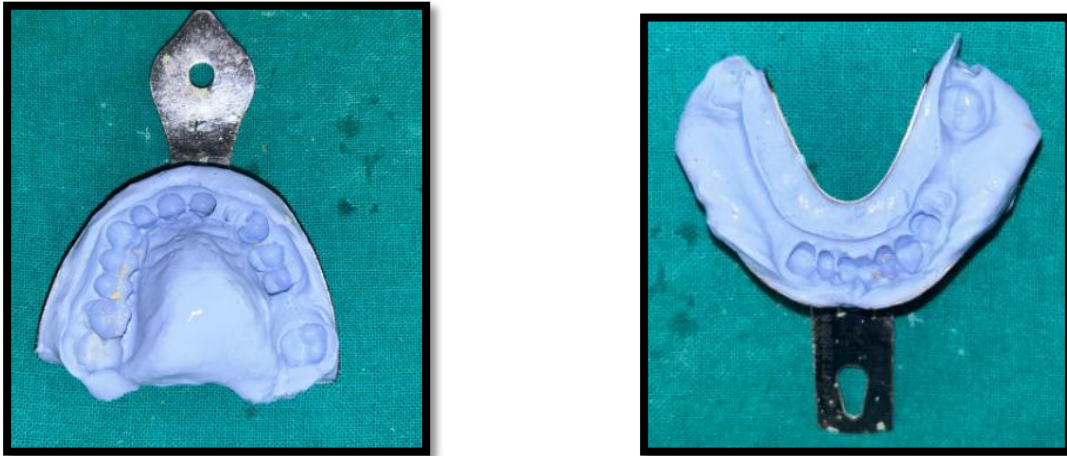

Figure 2

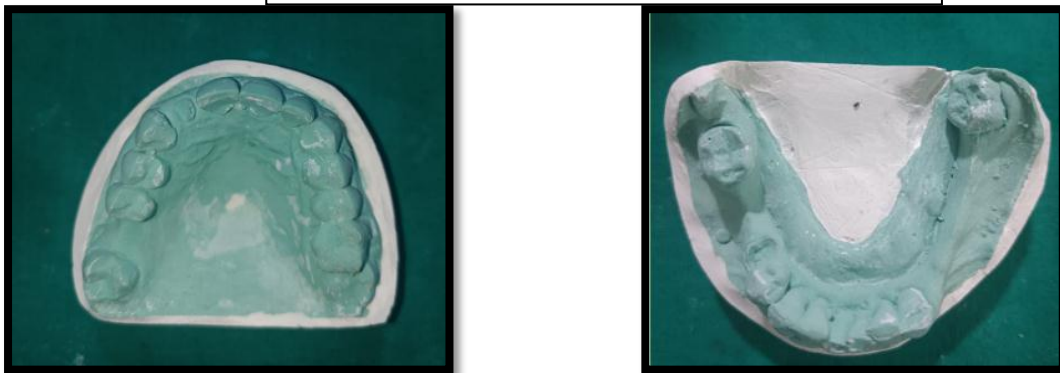


Figure 3

2. Maxillary cast was mounted on semi adjustable arcon articulator (Hanau wide vue) via face-bow transfer and a tentative jaw relation was made in centric relation and mandibular cast is mounted on articulator. (Figure 4).



Figure 4

3.A diagnostic wax-up of the full-mouth restoration was carried out at the 2 mm increased vertical dimension for both anterior and posterior teeth.(Figure 5)



Figure 5

4.Tooth preparation was done (Figure 6)

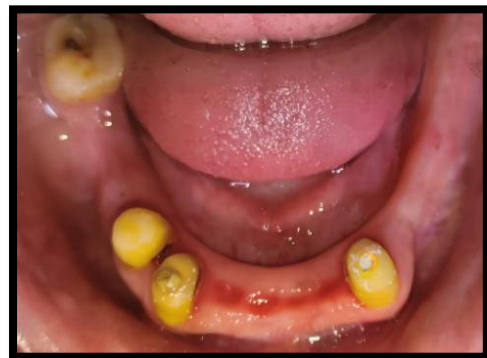
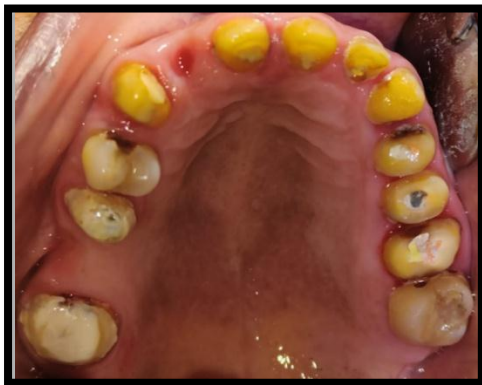
Figure 6

5.Surgical crown lengthening was done irt 11,13,21,22,23,24,25(Figure 7)

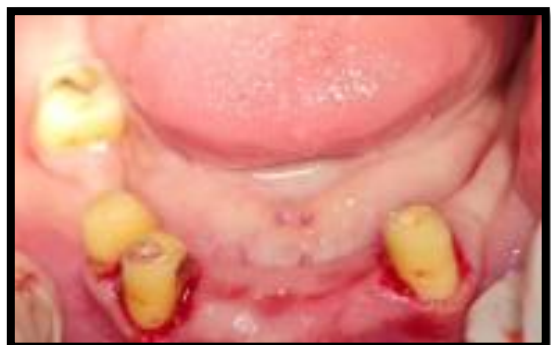
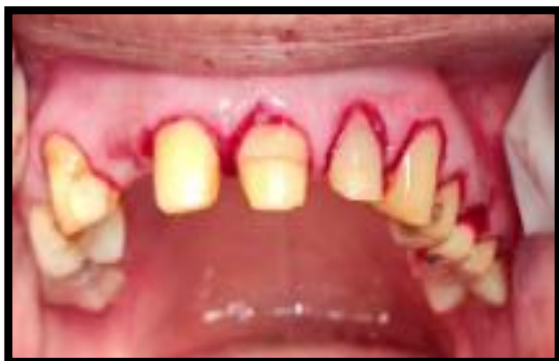
Figure 7

6. Temporary restoration was made cemented with temporary cement (FREEGENOL TEMPORARY PACK; GC Corp., Tokyo, Japan), on planned restorative vertical dimension and was evaluated intraorally for esthetics, phonetics, function and comfort. 2 weeks later, patients comfort and TMJ joint was evaluated for tenderness or clicking. Patient was comfortable with the new restorative vertical dimension.(Figure 8)

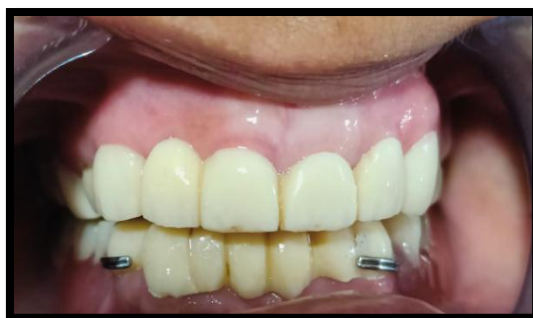

Figure 8

7. Temporary Crown removal was done and final impression was made for upper arch and lower arch using poly (vinyl siloxane) impression material and casts were poured in die stone. (Figure 9).

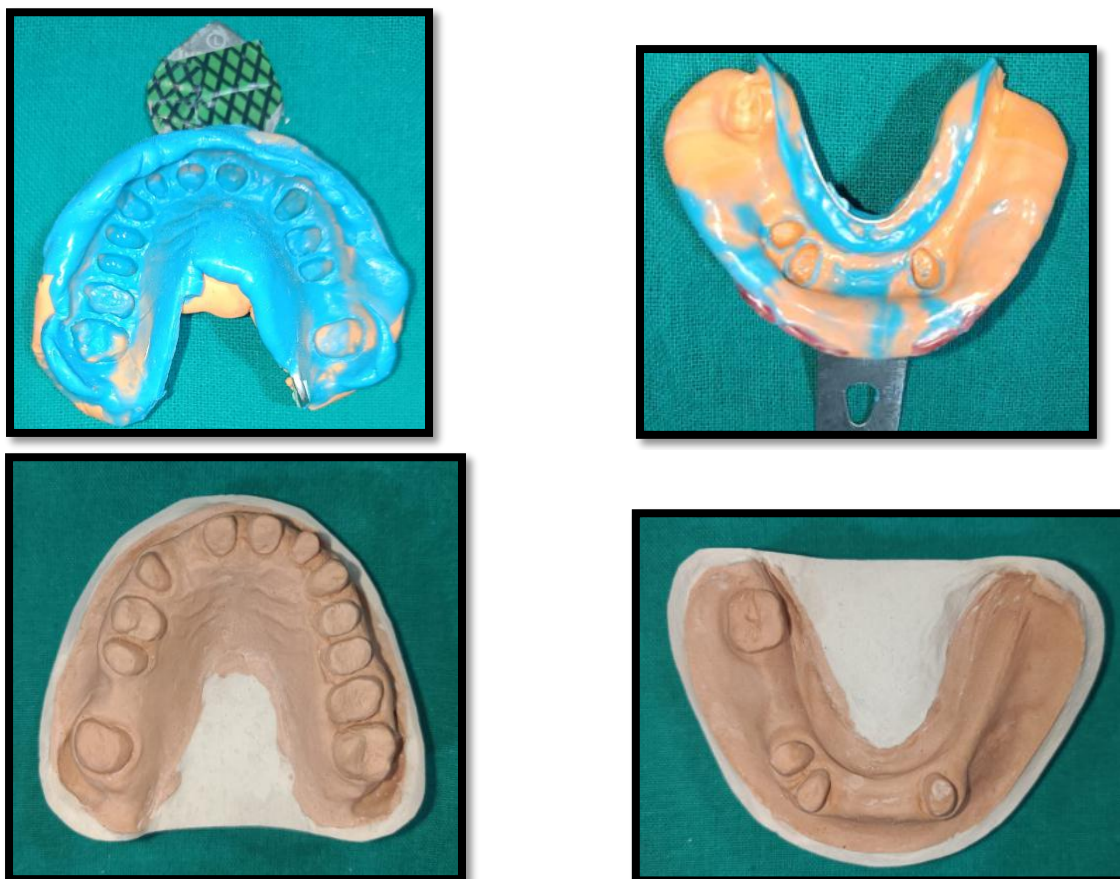


Figure 9

8. An orientation relation with a face-bow record was taken to mount maxillary cast on a Whip-mix articulator and made an interocclusal record to mount mandibular cast with previously established restorative vertical dimension in centric relation[figure 10a,10 b,10c]. A protrusive record was taken to adjust condylar guidance and lateral inclination value was obtained using formula $L = H/8 + 12$.

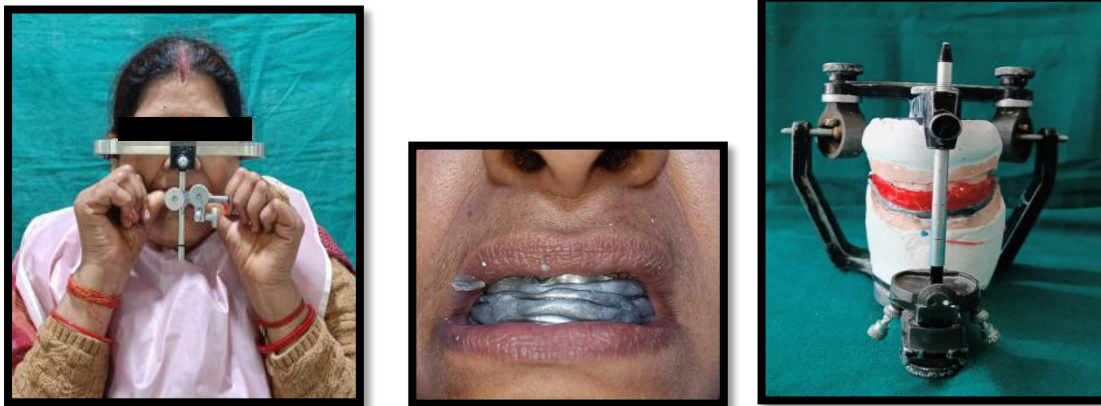


Figure 10a, 10 b, 10 c

9.A wax mock-up was done for maxillary arch and mandibular arch in established vertical and centric record (figure 11).

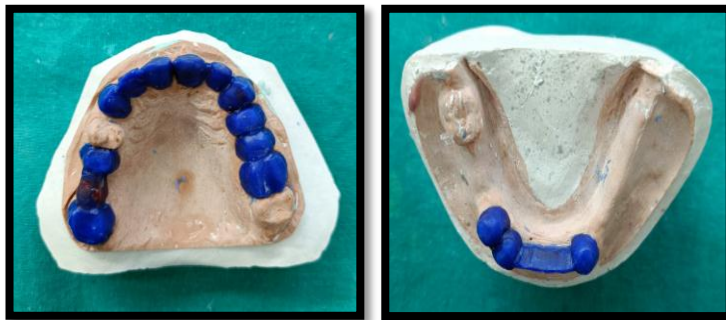

Figure 11

10. All the wax patterns were cast and metal copings were tried in the patients mouth and a bite was taken with bite registration wax for the porcelain build up.(Figure 12)

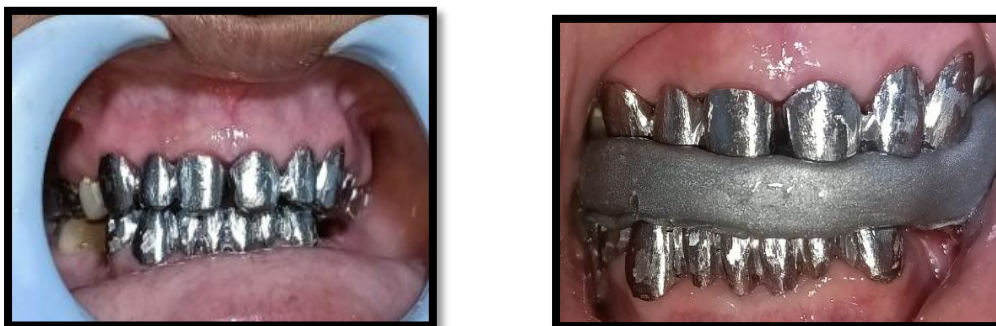


Figure 12

11.During the bisque trial stage of PFM prosthesis, impression was made with irreversible hydrocolloid ,later on performe border mounding with pick up impression for the fabrication of interim flexible prosthesis in the mandibular posterior region.(Figure 13)

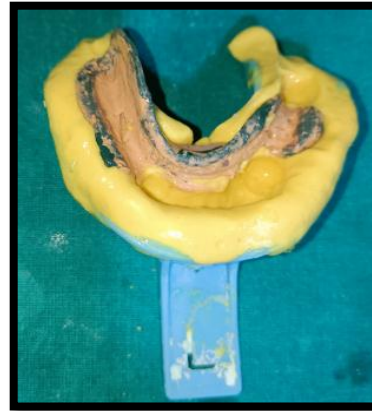
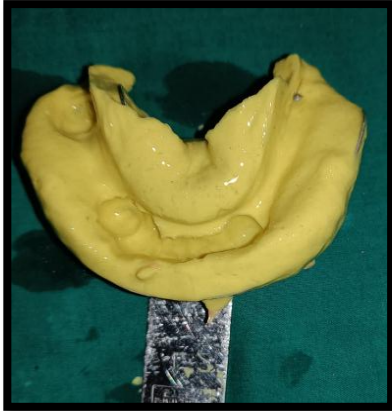
Figure 13

12. Definite restorations with PFM crowns exhibiting a vital and natural appearance with proper contour and shade were fabricated. Permanent cementation was done with GIC type I luting cement and a bite is taken for the fabrication of flexible removable partial denture.(Figure 14)

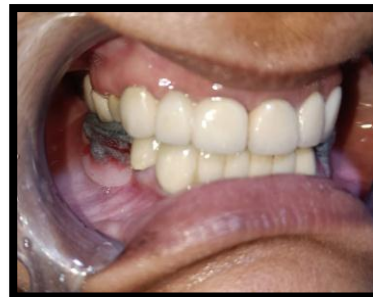
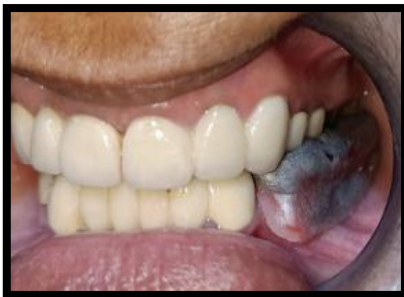
Figure 14

13. After successfully try in ,flexible removable partial denture was delivered to the patient. Patient was recalled for follow-up after a week and then one month followed by once in a six month.(Figure 15)

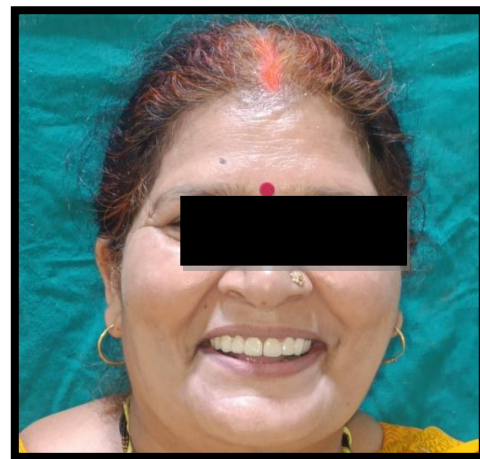
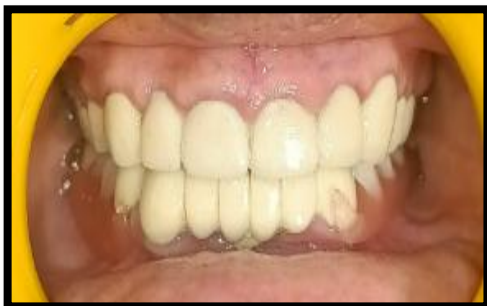
Figure 15

II. Discussion

The case report presented in this article describes a patient with multiple missing teeth and decreased VDO with restorative space issue. Predictable and effective treatment for patients with decreased VDO and restorative space issues depends on precise clinical and radiographic examinations, meticulous VDO determination, and methodical treatment planning using a diagnostic wax-up.

The reduction of VDO in the present case might be because of the long neglect of the edentulousness. Some of the key points to be considered during comprehensive evaluation of VDO is the nature of posterior teeth support available, phonetic evaluation, evaluation of Vertical Dimension at Rest (VDR) and facial appearance. Loss of *posterior teeth support* resulting from missing, tipped, rotated, and broken down teeth results in loss of VDO. This, in turn, places undue stress on the anterior segment which eventually becomes mobile or wears excessively⁶. It was planned to rehabilitation of maxillary and mandibular arch with raised the VDO upto 2 mm. According to Carlsson, increase in vertical dimension within physiologic limits will not have hazardous effects on the masticatory apparatus of the patient⁵. The validation of VDO was also made possible by the transitional prosthesis that was manufactured on the suggested vertical dimension.

As the patient cannot afford dental implants, the treatment plan was executed on a simplified and efficient rehabilitation technique so that low-cost rehabilitation can be done with great possibility of longevity for mandibular posterior region. The patient and the clinician determine how long a prosthesis will last. When it comes to fixed prostheses, the clinician's choice of material and impression technique, along with proper crown preparation, are crucial⁶. Prosthetic life can be further extended by a meticulous follow-up regimen that includes appropriate clinical and radiographic examination, as well as a personalized preventative protocol prescription for the patient⁷.

III. Conclusion

To achieve successful functional and aesthetic outcomes, full mouth rehabilitation necessitates the appropriate application of interdisciplinary concepts. In order to fulfill the biologic, restorative, functional, and aesthetic requirements, the diagnosis and treatment plan should determine whether the VD needs to be altered. Dentists can enhance patients' quality of life with well-planned treatments.

References

- [1]. Dua P, Singh JP, Aghi A. Aesthetic and functional rehabilitation of a case of mutilated dentition and loss of vertical dimensions. *The Journal of Indian Prosthodontic Society* 2011;11(3):189.
- [2]. Basutkar N, Alamoudi RK, Alharbi RM. Full Mouth Rehabilitation of a Patient with Restorative Space Issues-A Case Report. *Asian Journal of Pharmaceutical Research and Health Care*. 2020 Jun 22;12(2):1-7.
- [3]. Sicher H. *Oral Anatomy*, Ed 5. St. Louis. The C.V. Mosby co.; 1949. P. 270.
- [4]. Berry D, Poole D. Attrition: Possible mechanisms of compensation. *J. Oral Rehabil.* 1976; 30: 201-06. <https://doi.org/10.1111/j.1365-2842.1976.tb00945.x>. PMID: 1068232.
- [5]. Carlsson GE, Ingervall B, Kocak G. Effect of increasing vertical dimension on the masticatory system in subjects with natural teeth. *J Prosthet Dent* 1979;41(3):284-9.
- [6]. Bell AM, Kurzeja R, Gamberg MG. Ceramometal, crowns, bridges. Focus on failures. *Dent Clin North Am* 1985;29(4):763-778.
- [7]. Johansson A, Johansson AK, Omar R, Carlsson GE. Rehabilitation of the worn dentition. *Journal of oral rehabilitation* 2008;35(7):548-66.