

# **From The Archives: Reviving The Richmond Crown For Anterior Tooth Restoration- A Case Report**

**Dr Simran Sharma<sup>1</sup>, Dr Manu Bansal<sup>2</sup>, Dr P. Akashraj<sup>3</sup>**

<sup>1</sup>(Post Graduate Student, Department Of Conservative Dentistry & Endodontics, Jaipur Dental College, India)

<sup>2</sup>(Professor, Department Of Conservative Dentistry & Endodontics, Jaipur Dental College, India)

<sup>3</sup>(Post Graduate Student, Department Of Prosthodontics, Crown And Bridge, Jaipur Dental College, India)

---

Date of Submission: 01-09-2024

Date of Acceptance: 09-09-2024

---

## **I. Introduction**

Combining post-endodontic restoration with aesthetic rehabilitation has always been challenging. For a long time, the Richmond crown has been used in conjunction with post and core assembly when the remaining tooth structure is too fragile to support a sizable prosthetic crown. In such cases achieving retention from the root is of paramount importance, a concept which actually originally dates back to more than two centuries ago. <sup>(1)</sup> Common challenges encountered while dealing with restoration of structurally compromised teeth includes fracture of the remaining structure, perforations, encroachment of biologic width etc. Therefore, treatment options should be explored with an informed plan. The Richmond crown, an integrated approach that combines the crown and post into a single unit, offers both retention and aesthetics, making it a reliable solution for managing such cases. The post ensures the stability of the prosthetic crown, and is constructed on a supportive core. The core provides a foundation for the crown, while relying on the post for its secure retention. Contemporary post-core systems typically consist of two - three components (post, core, and crown). However, it is interesting to note that these systems have essentially evolved from the original Richmond crown which was a single unit system with core that had Porcelain fired on the crown attached to it, first introduced in 1878. <sup>(2)</sup> This paper discusses the role of the Richmond crown in restoring anterior teeth with reduced structural integrity, illustrated through this case report.

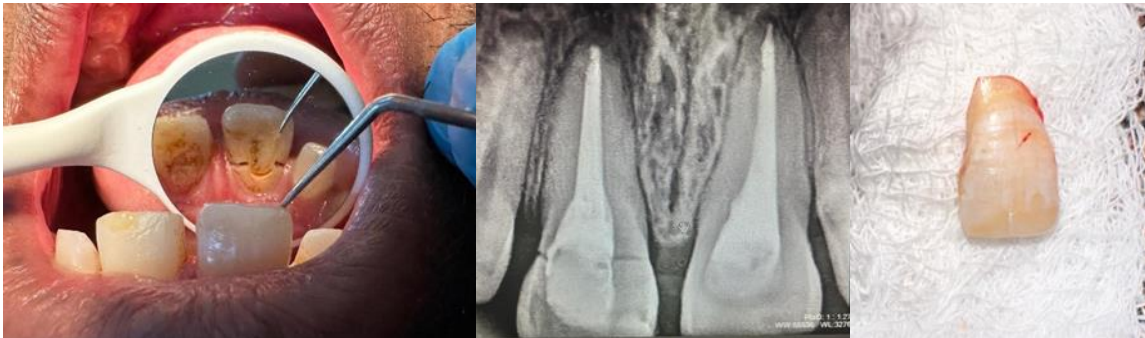
## **II. Case Report**

A 24-year-old male patient presented to the Department of Conservative Dentistry and Endodontics for restoration of his fractured right central incisor. The patient illustrated the history of endodontic treatment done in his maxillary central incisors 3 months back. He then suffered from trauma to his maxillary right central incisor 1 month prior to reporting to our department. Intraoral examination revealed an Ellis Class IV fracture of maxillary central incisor, with fracture line visible palatally at its cervical third. (Figure 1) with mobile fractured fragment. The same was confirmed by a radiograph later. (Figure 2) The patient also had generalised spacing between teeth with a pronounced midline diastema. Functional occlusal examination revealed decreased overjet. Treatment options that were explained to him included removal of mobile fractured fragment followed by gingivectomy for crown lengthening and restoration with either Richmond-style post and core fabrication or composite resin-based fibre post and core construction. Out of these two potential treatment options, the Richmond crown was preferred over the fibre post due to its superior strength. The presence of a large midline diastema and cervically damaged and fractured tooth structure made fibre post with composite buildup less favourable because of concerns about strength and aesthetics.

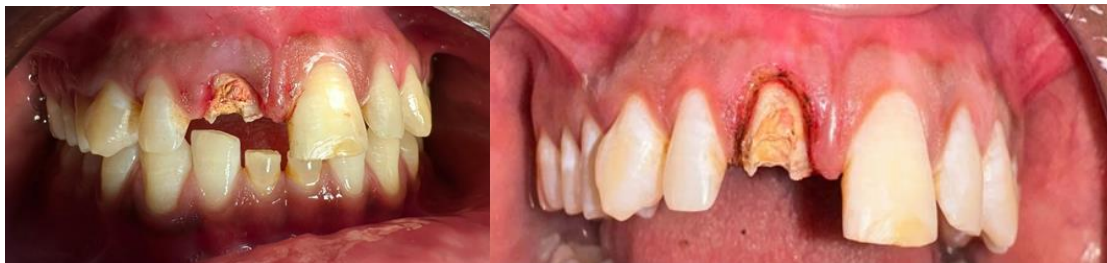7 days after removal of fractured mobile fragment of maxillary right central incisor (Figure 3 and Figure 4), crown lengthening was done by laser gingivectomy (Figure 5). Patient was recalled after 15 days of healing period and the healing was acceptable. Excess gutta percha was removed from access cavity and gross crown preparation was performed on the coronal tooth structure to create a ferrule effect circumferentially. With the help of Peeso reamers (Mani, Japan), the GP was removed to create a post space. (Figure 6). The post space preparation concluded with the circumferential filing of canal walls with H files to smoothen them and ensure there are no irregularities or undercuts in the canal. An anti-rotational notch was created near the opening within the canal to help in achieving retention and stability of the post and to prevent effect of any torque on it. Chamfer finish line was given palatally and shoulder finish line was prepared labially. The ferrule effect on the labial and palatal side was provided by the finish line of the final crown since the crown structure was less. After this, green inlay wax (GC Japan) was used to make an impression or the wax pattern of the post space (Figure 7 and Figure 8). While making the impression of the post space, care was taken to replicate the same inclination of root. While fabricating

*From The Archives: Reviving The Richmond Crown For Anterior Tooth Restoration- A Case Report*

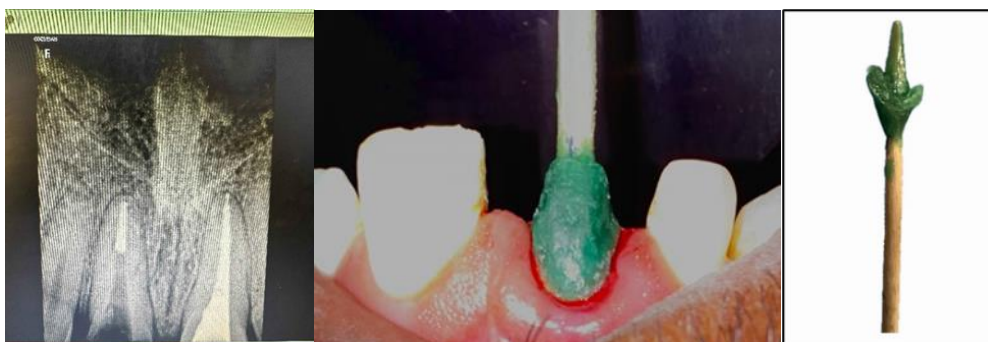the core over it, care was taken to align it such that it is in harmony with the adjacent teeth's inclination. The resulting pattern was cast in Ni-Cr alloy, (figure 9) after which a metal try-in was performed to assess its fit in the tooth. During the trial of the cast post, it was made sure to maintain adequate thickness on its labial aspect to accommodate porcelain labially for the most aesthetic outcomes. For the final impression, after applying tray adhesive to the core of the cast post, it was just placed inside the post space and light body impression material (GC Flexceed) was injected around the prepared tooth, followed by loading of putty impression material (GC Flexceed) on the stock tray. Following the one stage putty was technique, a pickup impression with the cast post was made. (Figure 10). The impression was poured in die stone and master cast was obtained. Porcelain shades (A2 incisally, A3.5 cervically with ivory stains for characterisation) were selected using Vita Classic Shade Guide and the selected shades of porcelain were layered and fired onto the core. (Figure 11 and Figure 12). After checking for the fit and aesthetics, the Richmond crown was glazed and was ready for cementation.



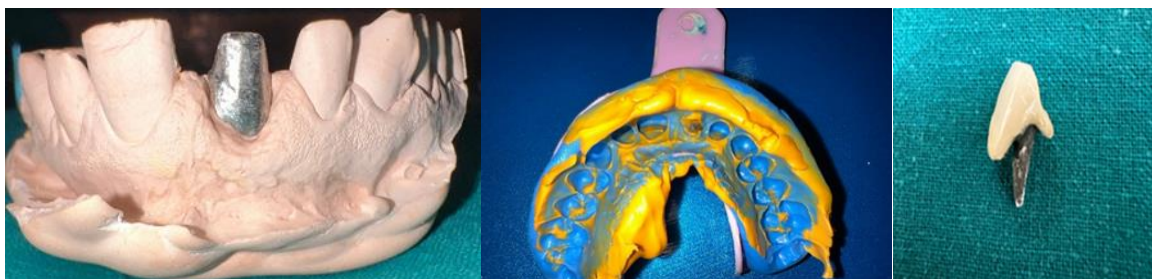
**FIG-1,2,3**



**FIG-4,5**



**FIG-6,7,8**



**FIG-9,10,11**

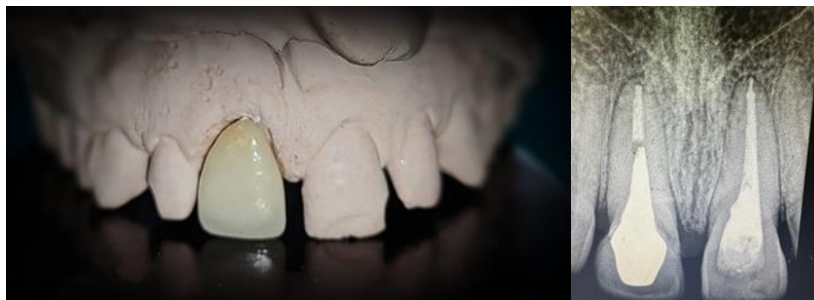

FIG-12,13

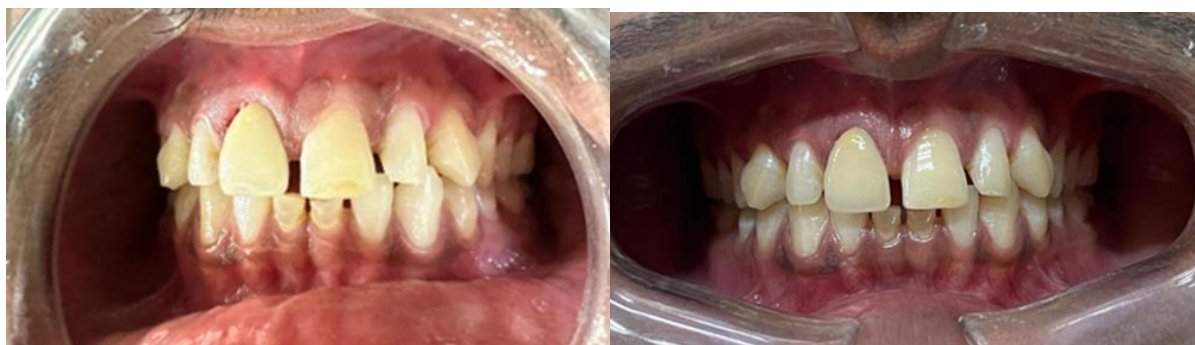

FIG-14,15

The Richmond crown was cemented using Luting GIC (type 1) (GC, Gold Label, luting and lining GIC) (Figure 13 and Figure 14). The patient was kept on a close follow-up for the next six months, and to our satisfaction we did not encounter any root fracture, post loosening, or secondary caries seen. (Figure 15)

### III. Discussion

Special procedures are required for restoring a tooth when a large portion of the crown has been compromised, whether due to caries, previous root canal treatments, or faulty restorations. <sup>(3,4)</sup> In these situations, specific procedures are necessary to further expose the clinical crown to increase the crown length so it can interfere the arc of rotation under oblique forces and prevent dislodgements. The post and core procedure along with crown lengthening procedures sometimes, is the most commonly used approach for such cases.

Introduced in 1878, the Richmond crown was an early solution for such cases, based on a design developed by Clark in the mid-1800s. The original Richmond crown of that time used a screw to secure the crown to the threaded tube within the root and was actually designed to retain a bridge. This method was similar to how porcelain and metal facings were attached for complete dentures. <sup>(1)</sup> The Richmond crown transcends the conventional post and core systems by presenting a unique, integrated approach. It is a bespoke, castable restoration where the post and crown are seamlessly fused into a single, meticulously crafted unit. This innovative design ensures both structural support and aesthetic harmony, achieved through a unified casting process. <sup>(5,6)</sup>

Our case was an ideal case for Richmond Crown as there was minimal coronal tooth structure remaining cervically, along with the midline diastema with a smaller overjet. The design's ability to provide exceptional cervical reinforcement compared to other restorations made it our preferred choice. <sup>(7,8)</sup> Therefore, considering all factors, the Richmond crown is strongly encouraged for rehabilitation of this patient's maxillary central incisor.

The Richmond crown is designed for severely decayed or extensively damaged single teeth with minimal residual coronal tooth structure and is particularly suitable for cases with steep incisal guidance, such as deep bites and limited overjet. Moreover, in a deep bite, the dislodging force (from the mandibular incisal edge) is positioned close to or beneath the restoration's margin, which makes it easier for the crown to become dislodged. In these situations, when the mandibular incisal edge contacts the palatal surface of the maxillary teeth for a longer time, the horizontal forces exerted on the restoration complex are intensified, both in the magnitude and duration, due to the shorter distance between the tooth's centre of rotation and the point of contact. The Richmond crown removes the core-crown-cement interface, thereby reducing or eliminating the risk of cement failure under this prolonged tensile stress. In separate systems, varying thermal expansion rates can disrupt the bonds within the tooth-post-core-cement-crown assembly at any interface. Additionally, masticatory forces can flex the post, potentially stressing the post-core interface and causing core separation due to the post's permanent deformation. Hence by minimizing the number of interfaces in this post and core assembly, a one-unit restoration creates a monoblock effect, enhancing overall stability and durability. <sup>(6)</sup>

To enhance mechanical resistance and retention form, a 360-degree ferrule collar is included along with an anti-rotational notch. The Richmond crown has several benefits: it is custom-fitted to the root configuration, alleviates pressure at the cervical margin, delivers strong support, allows ample space for ceramic firing, and ensures sufficient clearance at the incisal edge.<sup>(9)</sup> However, the Richmond crown also has some drawbacks like it requires more time and multiple patient appointments, is more costly, and modulus of elasticity that is ten times greater than that of dentin, is less retentive compared to parallel-sided posts, and acts as a wedge when transferring occlusal loads. If the ceramic component fractures, it can be challenging to remove, potentially leading to tooth fracture. Before recommending tooth extraction for a severely damaged tooth, it's crucial to analyse the forces acting on that tooth, including anterior guidance and occlusal forces.<sup>(7)</sup> Typically, anterior teeth do not experience significant compressive or tensile forces and can be effectively restored for an extended period using options such as a Richmond crown.<sup>(10,11)</sup>

#### **IV. Conclusion**

In this case report, we explore the aesthetic rehabilitation of the structurally compromised maxillary central incisor, emphasizing the use of Richmond crown as a viable alternative to contemporary implant trends. Despite the prevalence of implants, the Richmond crown—a technique first introduced in 1878—proves to be a valuable option even after 140 years. This approach highlights the importance of a clinician's role in evaluating each case individually and selecting the most appropriate method to restore both function and appearance. While modern implants are widely used, they are not the sole solution, and conservative alternatives like the Richmond crown should always be considered. By incorporating both traditional and innovative techniques, clinicians can provide the best possible care and outcomes for their patients.

#### **References**

- [1] Smith Ct, Schuman Nj, Wasson W. Biomechanical Criteria For Evaluating Prefabricated Post-And-Core Systems: A Guide For The Restorative Dentist. *Quintessence Int.* 1998; 29:305-312
- [2] Smith Ct, Schuman N. Prefabricated Post-And-Core Systems: An Overview. *Compend Contin Educ Dent.* 1998; 19:1013-1020.
- [3] Saraswat A, Nagpal A, Paul R, Pratap R. Esthetic And Functional Rehabilitation Of Maxillary Anterior Teeth By Richmond Crown: A Case Report. *Heals Int J Comm Health Med Res.* 2019; 5:68–71
- [4] Antariksha Dod, Anil Kumar K. Managing Fractured Central Incisor With Richmond Crown –A Case Report *J. Of Applied Dental And Medical Sciences* Nlm Id: 101671413 Issn:2454-2288 Volume 2 Issue 1 January - March 2016
- [5] Dr. Parul Pandey, 2016. “Managing Fractured Incisor With Richmond Crown- A Case Report”, *International Journal Of Current Research*, 8, (11), 41770-41774.
- [6] Abdullah Mf, Almalki Aa. Treatment Of Endodontically Treated Molar With Richmond Crown-A Case Report. *Pakistan Oral & Dental Journal* Vol 35, No. 2 (June 2015)
- [7] Khan F, Mishra Sk. Restoration Of Anterior Esthetics With Richmond Crown. *Blde Univ J Health Sci.* 2017; 2:109–11.
- [8] Sachin M, Manisha M. Successful Rehabilitation Of Anterior Crowns With Richmond Crown:Case Series. *J Dent Probl Solut.* 2017; 4:40–3. Doi:10.17352/2394-8418.000046.
- [9] Fernandes As, Dessai Gs. Factors Affecting The Fracture Resistance Of Post-Core Reconstructed Teeth: A Review. *Int J Prosthodont.* 2001;14(4):355–63.
- [10] Yadav Chakravarthy, Swetha Chamarthy. “Richmond Crown – For Restoration Of Badly Mutilated Posterior Teeth: A Case Report”. *Journal Of Evidence Based Medicine And Healthcare*; Volume 2, Issue 30, July 27, 2015; Page: 4500- 4507
- [11] Vinothkumar Et Al. Cad/Cam Fabricated Single-Unit All Ceramic Post–Core–Crown Restoration. *Journal Of Conservative Dentistry*:Jan-Mar 2011(14-1).