

Cerebral Coenurosis in a Boer x Hair Goat: Certain Hematological, Biochemical and Pathological Findings

Burcak Aslan Celik¹, Serkan Yildirim², Ozgur Yasar Celik^{3*},
Kivanc Irak⁴, Gulsah Akgul³

¹Department of Parasitology, Siirt University Faculty of Veterinary Medicine, Siirt, Turkey

²Department of Pathology, Ataturk University Faculty of Veterinary Medicine, Siirt, Turkey

³Department of Internal Medicine, Siirt University Faculty of Veterinary Medicine, Siirt, Turkey

⁴Department of Biochemistry, Siirt University Faculty of Veterinary Medicine, Siirt, Turkey

*Corresponding author: Ozgur Yasar Celik

Abstract: Coenurosis is a zoonotic disease of sheep and goats caused by *Coenurus cerebralis*, the larval form of *Taenia multiceps*. In addition to the neurological symptoms like the rotation of the animals around themselves, ataxia, bruxism, and incoordination, the diseased animals also suffer from atrophied brains, and osteomalacia and thinning of the skull bones. Most cases end with death in a couple of weeks. In this study, the relationship of a coenurosis case encountered in a Boer x Hair Goat crossbreed goat with certain hematological, biochemical, and clinicopathological findings were investigated. In the clinical inspections, the diseased animal displayed inanimation, lack of appetite, incoordination, and rotation behavior around itself, along with leaning of the head against the wall and bruxism. The necropsy revealed *coenurus cerebralis* cysts located at the cerebral hemisphere inside the brain. WBC and MCHC values were higher than the reference values, while Hgb and Hct percentages were lower than reference values. RBC and MCV values were within the reference limits. ALT, AST activities and Tp, Alb, Glu, Na, K, Cl, and Chol values were all within reference limits as well. As a result, the *Coenurus cerebralis* infestation, which is a significant problem for animal breeding in our country, was shown to have caused the typical clinicopathological results in a Boer x Hair crossbreed goat by forming cysts in the cerebral hemisphere, and that biochemical and hematological findings could be important in terms of diagnosis and prognosis of the disease.

Keywords: Boer x Hair Goat, *coenurus cerebralis*, blood parameters

Date of Submission: 10-12-2018

Date of acceptance: 25-12-2018

I. Introduction

Coenurosis is a zoonotic disease of sheep and goats that is caused by *Coenurus cerebralis*, the larval form of *Taenia multiceps*^{1,2,3}. While *Taenia multiceps* lives in the small intestines of dogs and other canids^{2,3}, its larval form (metacestode, or coenurus) affects the central nervous system, particularly the brain of sheep and goats². The larva is reported to develop and cause posterior paralysis in sheep, goats, pigs, deer, equides, camels, and rarely in cattle and humans^{4,5,6,7}. The symptoms vary based on the location and size of the cyst and the pressure it applies to the brain³. Due to the pressure applied by the *Coenurus cerebralis* to the brain, the animal leans its head towards the cyst and rotates around itself. In addition to the neurological symptoms like rotation around themselves, ataxia, bruxism, and incoordination, the diseased animals also suffer from atrophied brains, and osteomalacia and thinning of the skull bones^{1,3,5,8}. Most cases end up with death in a couple of weeks⁹. The most important laboratory findings of the animals infested with the parasite are reported to be changes in the hematological and biochemical parameters¹⁰.

In this study, the relationship of the coenurosis case encountered in a Boer x Hair Goat crossbreed goat with certain hematological, biochemical, and clinicopathological findings were investigated.

II. Materials and Methods

Study area:

Siirt province (Figure 1) lies in the semi-arid climate region. The average highest and lowest temperatures are between 36.9 °C and 18.9 °C in summer and there are water shortages during the summer¹¹.

Animal material:

All applicable international, national, and/or institutional guidelines for animal testing, animal care and use of animals were followed by the authors.

The animal material of the study consists of a single female Boer x Hair Goat crossbreed goat of the age of 2, raised in the province of Siirt (Fig. 2A, 2B). Before the slaughter, the clinical inspection of the goat was carried off, and its head was sent to the pathology labs afterward. Samples were collected from the brain hemisphere in which the parasites were settled, and the surrounding tissue. The tissue samples were fixed in 10% buffered formalin and were buried in paraffin blocks and 4µm section slices were taken. All section slices were dyed with hematoxylin-eosin and inspected under light microscope.

Blood samples:

Blood samples were collected from the jugular vein of the animal into EDTA tubes for hematological inspections. White Blood Cell (WBC), Red Blood Cell (RBC), Hemoglobin (Hgb), Hematocrit (Hct), Mean Cell Volume (MCV), and Mean Corpuscular Hemoglobin Concentration (MCHC) values of the blood samples were measured using a Mindray BC2800 fully-automated blood measurement device. Blood samples collected for biochemical analyses were centrifuged at 3000 rpm for 10 minutes and the serum were transferred to Eppendorf tubes and stored at -20 °C until they were used. Alanine aminotransferase (ALT), Aspartate aminotransferase (AST), Total protein (Tp), Albumin (Alb), Glucose (Glu), Sodium (Na), Potassium (K), Chlor (Cl) and Cholesterol (Chol) analysis of the serum samples were conducted using an ADVIA 1800 Chemistry System Autoanalyzer.

III. Results

Clinical Findings:

In the clinical inspections, the diseased animal displayed lack of apatite, incoordination, and rotation behavior around itself, along with leaning of the head against the wall and bruxism. Clinical examination findings are given in Table 1.

Table 1. Some clinical parameters in boer x hair goat naturally infected with *Coenurus cerebralis*.

Parameters	Values	Reference (12)
Respiration/min.	50	20-30
Heart rate/min.	120	70-120
Temperature °C	39	38.5-39.5

Post-mortem examination findings:

In the necropsy, the *Coenurus cerebralis* cysts settled in the cerebral hemisphere of the brain were detected (Figures 3,4). These cysts were observed to be generally superficial in position in the brain tissue, with fluctuant consist

ency, and filled with numerous white protoscolex. Microscopically, in the histopathological inspection of the cysts collected from the brain, wide lichefaction necrosis areas were identified in parts with the *Coenurus* cyst. Dense lymphoplasmacytic mononuclear cell infiltrations and numerous large body cells of foreign origins were identified around this necrotic body. Similarly, perivascular mononuclear cell infiltrations and hyperemia were observed in the veins of the area.

Hematological findings:

The results of the hematological parameters are given in Table 2. According to Table 2, WBC and MCHC values were higher than the reference values, Hgb and Hct percentages were lower than reference values, while RBC and MCV values were within the reference limits.

Table 2. Some hematological parameters in boer x hair goat naturally infected with *Coenurus cerebralis*.

Parameters	Values	Reference (12)
WBC (x10 ⁹ /L)	26.60	4-13
RBC (x10 ¹² /L)	10.79	8-18
HGB (g/dL)	6.60	8-12
HCT (%)	17.20	22-38
MCV (fl)	16	16-25
MCHC (g/dL)	38.3	30-36

Biochemical findings:

The results of biochemical parameters are given in Table 3. Evaluation of Table 3 reveals that ALT, AST activities and Tp, Alb, Glu, Na, K, Cl and Chol levels of the goat infested with *Coenurus cerebralis* are all within the reference limits.

Table 3. Some biochemical parameters in boer x hair goat naturally infected with *Coenurus cerebralis*.

Parameters	Values	Reference (13)
Na	146	142-155
K	4.50	3.50-6.70
CL	110	100-125
TP (g/dL)	6.50	6-7
ALT (U/L)	25	24-83
AST (U/L)	179	167-513
ALB (g/dL)	2.70	2.70-3.90
GLUO (mg/dL)	60	50-75
CHOL (mg/dL)	63	55-200

IV. Discussion

Coenurosis is reported to have been seen in goats¹⁴, sheep^{3,7,15,16}, calves⁵, and cattle^{8,17,18} in Turkey. The researchers Araştırcılar^{1,3,5,8} report that the animal rotates around itself due to the pressure applied to the brain by the *Coenurus cerebralis* cyst, and symptoms like ataxia, bruxism, and incoordination emerge. In this study, neurological findings similar to those of the researchers were found in forms of bruxism, leaning the head to a wall, and rotation around itself.

In a study conducted by Amin *et al.* (2013), the body temperature, heart rate, and respiratory count were all determined to be within the reference limits. The body temperature and heart rates in our study were also found within the normal reference limits.

The most important laboratory findings of the animals infested with the parasite are reported to be the changes in the hematological and biochemical parameters¹⁰. Hematologically, RBC count decrease, Hct percentage drop, reduction in Hgb concentration, and increase in the eosinophile count are reported as possible findings^{15,20,21}.

In a study which evaluated certain hematological parameters in sheep infested with *Coenurus cerebralis*, erythrocyte, hemoglobin, hematocrit, MCH and MCHC values of the infested animals were found to be lower compared to the control group, while their leucocyte count nearly doubled and MCV value stayed the same¹⁵. In their study conducted on sheep with Coenurosis, Toos *et al.* (2004) report a significant decrease in hemoglobin, erythrocyte and hematocrit values, and an increase in MCHC and MCV values. In our study, the increase in WBC and MCHC values, and the decrease in Hgb and Hct values are in line with the findings of the researchers^{15,22}. Leucocytosis may be the result of eosinophilia and monocytosis due to the parasitic infestation²³.

Numerous studies exist on the biochemical changes on animals infested with *Coenurus cerebralis*^{24,25,26}. In a study by Dönmez *et al.* (2007) in which the biochemical parameters of animals infested with *Coenurus cerebralis* was inspected, it was reported no significant difference was found between the control group and infested animals group in terms of ALT, AST, albumin, and total protein percentages, while the glucose level of the infested animals was higher. In another study conducted on sheep infested with *Coenurus cerebralis*, a significant decrease in total protein and albumin levels compared to control group was reported, in addition to a significant increase in ALT, AST, and cholesterol levels²².

Uslu *et al.* (2011) report that the albumin, total protein, urea, total cholesterol, triglyceride, ALT, AST, CK and ALP levels of sheep naturally infested with *Coenurus cerebralis* and control group animals were similar. In our study, the Na, K, Cl, TP, ALT, AST, Alb, Gluo and Chol values of the animal infested with *Coenurus cerebralis* were found to be within the reference limits reported for the goats as well. Changes or similarities in biochemical parameters might depend on the density of the parasitic infestation, and whether the parasites have the generalized effects that could cause significant alterations²⁵.

It has been reported that the coenurus cysts could localize in various locations in goats^{27,28,29}. In a study, Achenef *et al.* (1999) report that in 96% of the the cases cysts were located in the cerebral hemisphere, while in 4% they were located in the cerebellum, while Sharma *et al.* (1998) report that coenurus cyst has settled in the abdominal cavity, and Gharagozlou *et al.* (2003) reported that coenurus cysts settled in subcutaneous tissues, skeletal muscles, thoracic cavity, and lung parenchyma. In research conducted on coenurosis in Turkey, cysts are mostly reported to settle in the parieto-occipital³⁰, frontal and temporal¹, regions of the brain, and in the cerebellum^{3,5,6,8,17}, while histopathological inspections report that cysts are surrounded by fibrovascular connective tissues.

In our study, the *Coenurus cerebralis* cysts were found inside the cerebral hemisphere of the brain, similar to the findings reported by the researchers^{3,5,8,17,27}.

V. Conclusion

As a result, the *Coenurus cerebralis* infestation, which is a significant problem for animal breeding in our country, was shown to have caused the typical clinicopathological results in a Boer x Hair crossbreed goat

by forming cysts in the cerebral hemisphere, and that biochemical and hematological findings could be important in terms of diagnosis and prognosis of the disease.

Acknowledgements

The study has been orally presented in the 3rd International Conference on Engineering and Natural Sciences (ICENS). 3-7 May 2017, Budapest, Hungary.

Conflicts of interest

The authors declare that they have no conflict of interest

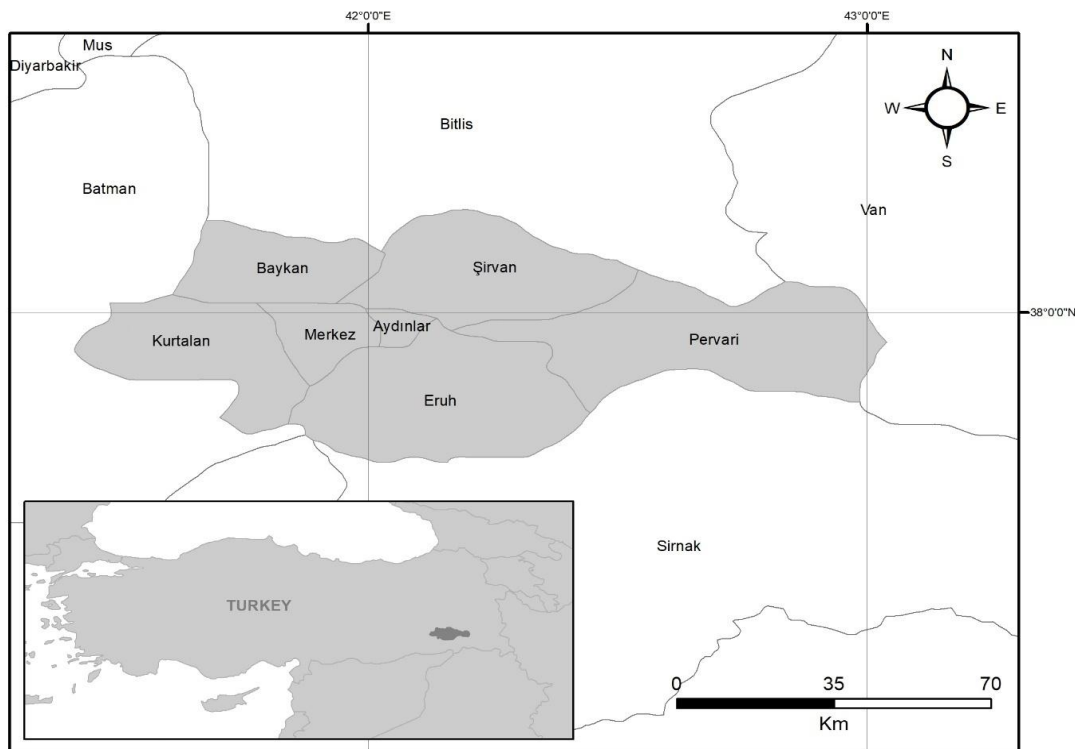


Figure 1: The map of the Siirt province, in which the study was performed



Figure 2. Boer x Hair Goat Crossbreed infested with *Coenurus cerebralis*

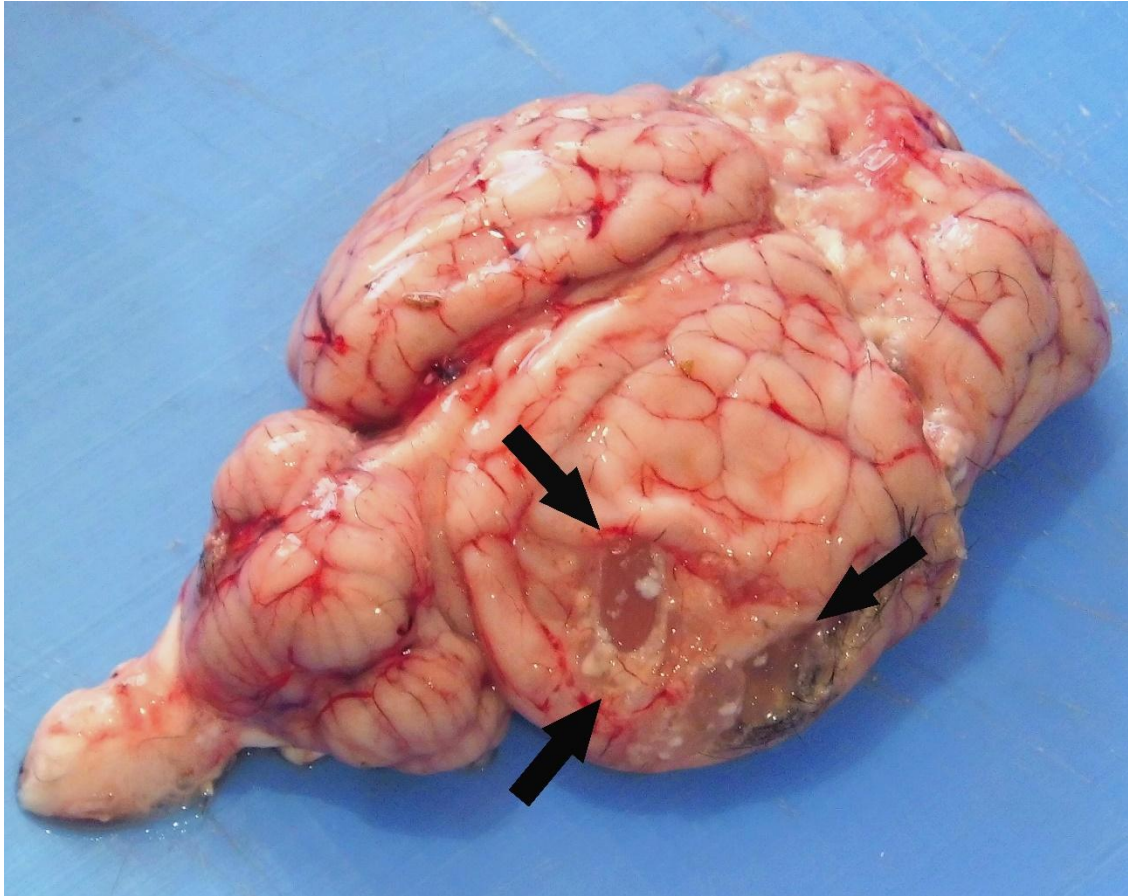


Figure 3. Coenurus cerebralis cyst in the temporal and occipital lobe of the brain hemisphere (arrows).

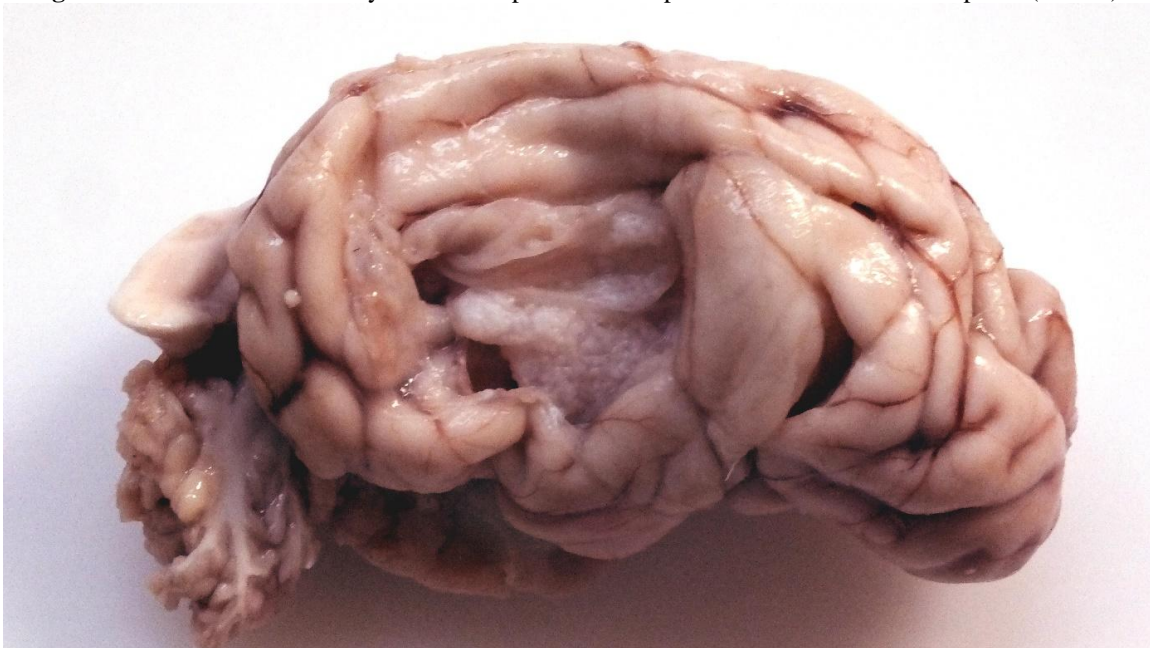


Figure 4. Coenurus cerebralis cyst in the temporal and occipital lobe of the brain hemisphere.

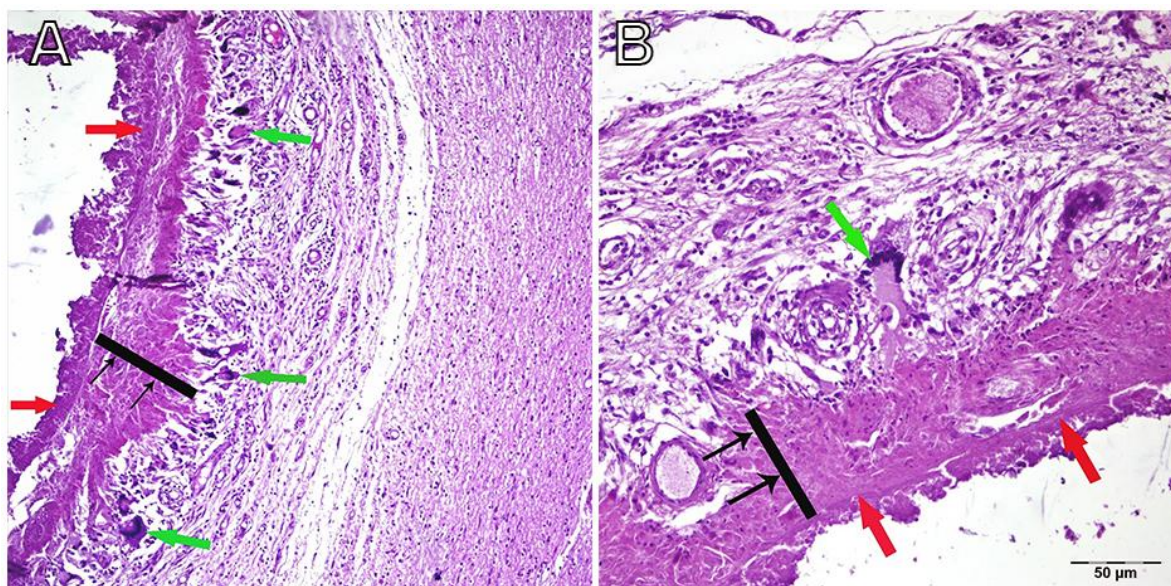


Figure 5. Coenurus cyst wall (red arrows), lichification necrosis area (black arrows), foreign large body cells (green arrow), perivascular mononuclear cell infiltration in the brain, Bar: 100µm

References

- [1]. Güçlü, F., Uslu, U., and Özdemir, Ö. Bilateral Bone Perforation Caused by *Coenurus cerebralis* in a Sheep: Case Report *Türkiye Parazitoloj. Derg.* 2006; 30 (4), 282-284.
- [2]. Nourani, H., and Kheirabadi, K. Cerebral coenurosis in a goat: pathological findings and literature review. *Comparative Clinical Pathology.* 2009; 18 (1), 85-87.
- [3]. Yılmaz, R., Özyıldız, Z., and Yumuşak, N. Pathomorphological Findings of *Coenurus cerebralis* in Sheep. *Harran Üniv Vet Fak Derg.* 2014; 3 (2), 73-77.
- [4]. Bussell, K., Kinder, A., and Scott, P. Posterior paralysis in a lamb caused by a *Coenurus cerebralis* cyst in the lumbar spinal cord. *Veterinary Record.* 1997; 140, 560.
- [5]. Ozkan, C., Yıldırım, S., and Kaya, A. Clinical coenurosis (*Coenurus cerebralis*) and associated pathological findings in a calf. *Pak Vet J.* 2011; 31 (3), 263-266.
- [6]. Tavassoli, M., Malekifard, F., Soleimanzadeh, A., and Tajik, H. Prevalence of *Coenurus cerebralis* in sheep in Northwest of Iran. *Veterinary Research Forum.* 2011; 2 (4), 274-276.
- [7]. Uslu, U., and Guclu, F. Prevalence of *Coenurus cerebralis* in sheep in Turkey. *Medycyna Weterynaryjna.* 2007; 63 (6), 678-680.
- [8]. Gökçe, E., Beytut, E., Taşçı, G., Uzlu, E., Kırmızıgül, A., and Erdoğan, H. An Outbreak of Coenurosis in A Cattle Farm. *Kafkas Univ Vet Fak Derg.* 2013; 19, A199-A202.
- [9]. Scala, A., and Varcasia, A. Updates on morphobiology, epidemiology and molecular characterization of coenurosis in sheep. *Parassitologia.* 2006; 48 (1-2), 61-63.
- [10]. Yüksek, N., Altuğ, N., and Gül, A. Koyunlarda endoparazit enfeksiyonlarında triklabendazol-levamisol kombinasyonunun tedavi etkinliği. *Yüzüncü Yıl Üniversitesi Veteriner Fakültesi Dergisi.* 2007; 18 (1), 19-24.
- [11]. Meteoroloji. (2018). Turkish State Meteorological Service. Retrieved from <https://goo.gl/ud7dDBK>
- [12]. Batmaz, H. (2013). *Koyun ve Keçilerin İç Hastalıkları* (Vol. 1). Istanbul: Nobel Tıp Kitabevi.
- [13]. Altıntaş, A., and Fidancı, U. Evcil hayvanlarda ve insanda kanın biyokimyasal normal değerleri. *AU Vet Fak Derg.* 1993; 40 (2), 173-186.
- [14]. Oge, H., Oge, S., Gonenc, B., Ozbakis, G., and Asti, C. Coenurosis in the lumbar region of a goat: a case report. *Veterinarni Medicina.* 2012; 57 (6), 308-313.
- [15]. Dönmez, N., Uslu, U., and Atalay, B. Some haematological Parameters in Sheep infested with *coenurus cerebralis* and *oestrus ovis*. *Vet.Bil.Derg.* 2006; 23 (3-4), 75-77.
- [16]. Gıcık, Y., Kara, M., and Arslan, M. Prevalence of *Coenurus cerebralis* in sheep in Kars Province, Turkey. *Bull Vet Inst Pulawy.* 2007; 51, 379-382.
- [17]. Avcioglu, H., Kapakin, K., and Yildirim, A. Clinical, morphological and histopathological features of bovine coenurosis. *Revue Méd. Vét.* 2012; 163 (6), 295-298.
- [18]. Avcioglu, H., Yildirim, A., Duzlu, O., Inci, A., Terim, K., and Balkaya, I. Prevalence and molecular characterization of bovine coenurosis from Eastern Anatolian region of Turkey. *Veterinary parasitology.* 2011; 176 (1), 59-64.
- [19]. Amin, M., Hashim, M., Hossain, M., and Al-Sultan, I. Coenurosis cerebralis infection (Gid disease) in Black Bengal goats; Effects on certain blood values after surgical treatment. *Journal of Advanced Biomedical & Pathobiology.* 2013; 3 (1), 1-7.
- [20]. Halliwell, R., and Gorman, N. (1989). *Veterinary Clinical Immunology* (1 ed.). Philadelphia: WB Saunders Company.
- [21]. Jain, N. (1986). *Schalm's Veterinary Hematology* (4 ed.). Philadelphia: Lea & Febiger.
- [22]. Toos, A., and Adib, E. Some biochemical studies on serum of sheep affected with *coenurus cerebralis*. *Veterinary Medical Journal (Giza).* 2004; 52 (1), 61-68.
- [23]. Coles, E. (1980). *Veterinary clinical pathology* (Vol. 3). Philadelphia, London: W.B. Saunders.
- [24]. Altıntaş, A., Çelik, S., Fidancı, U., Biyikoğlu, G., and Sahillioglu, H. MAO, Total Protein, Uric Acid and Orotic Acid Values of the Serum and CSF Samples and CSF Pressure in the Lambs Infected with *Coenurus Cerebralis*. *Turkish Journal of Veterinary And Animal Sciences.* 1997; 21 (1), 47-52.
- [25]. Dönmez, N., and Keskin, E. Some biochemical parameters in Sheep infested with *coenurus cerebralis* and *Oestrus ovis*. *Vet.Bil.Derg.* 2007; 23 (1), 107-109.

- [26]. Uslu, U., Akalin, P., Şahin, E., and Altunok, V. Some biochemical parameters in yearling sheep naturally infected with *Coenurus cerebralis*. *Fresenius environmental bulletin*. 2011; 20 (2), 411-414.
- [27]. Achenef, M., Markos, T., Feseha, G., Hibret, A., and Tembely, S. *Coenurus cerebralis* infection in Ethiopian highland sheep: incidence and observations on pathogenesis and clinical signs. *Tropical Animal Health and Production*. 1999; 31 (1), 15-24.
- [28]. Gharagozlou, M., Mobedi, I., and Akhavan, P. A pathological and parasitological study of *Coenurus Gaigeri* infestation of Goats from Iran. *Indian J Vet Pathol*. 2003; 27, 95-97.
- [29]. Sharma, D., Singh, N., and Tiwari, H. Prevalence and pathology of coenurosis in organized goat farms. *J Vet Parasitol*. 1998; 12, 30-32.
- [30]. Akkaya, H., and Vuruşaner, C. İstanbul'da kesilen koyunlarda ve danalarda *Coenurus cerebralis*. *Turkiye Parazitol Derg*. 1998; 22, 320-324.

Ozgur Yasar Celik." Cerebral Coenurosis in a Boer x Hair Goat: Certain Hematological, Biochemical and Pathological Findings. "IOSR Journal of Agriculture and Veterinary Science (IOSR-JAVS) 11.12 (2018): PP- 47-53.