

Anal sac disease and /or Hemorrhoids of a Police K9 Dog (A Case Report)

Kamal M. Alsaad , Ali Jarad , Mohanad H. Lafta

*Department of internal and preventive medicine, College of Veterinary Medicine, University of Basrah, Iraq.
Corresponding author Kamal M. Alsaad*

Abstract: A male, Mullinoise breed a police (K9) dog, 30 kg weight and of 4 years old, had been brought to the Veterinary Clinical Hospital, College of Veterinary Medicine, University of Basrah, Iraq, Anal sac disease or Hemorrhoids was suspected, Since, the diseased animal show signs of discomfort, specially when forced to set down, straining with difficult defecation, However, The animal drags his butts upward or arch its back, and bad odors or scents come from its anal area. The diseased dog tries lick its anus sometimes, Moreover on rectal examination by a finger, small bulging gland like mass located at the left and right side of the anus was detected and could be seen even from outside, Furthermore, the vital signs of the diseased dog show, body temperature (38.4C), the heart rate was 110/ min, respiratory rate of 33/ mint. In addition, examination of blood parameters indicates a slight increase of PCV value. Gentamycin 10%, 10mg /kgBW daily intramuscular for 3 days, in addition to a per rectum application of a mixture containing Lidocaine hydrochloride and Fluocinolone acetonide in a cream base, daily for 3 days, as well as a description of two teaspoonful of mineral oil daily for making little lubrication has been prescribed. It has been concluded that anal sac problems and /or Hemorrhoids in dogs could be a worse digestive issues need monitoring and follow-up for the sick animal.

Date of Submission: 06-02-2020

Date of Acceptance: 20-02-2020

I. Introduction

It has been mentioned that hemorrhoids are a group of veins located in the anus and lower part of the rectum, which become inflamed then swollen , caused by an increase of blood flow and pressure in the same area. This increased blood flow or pressure is rising from straining or pressure inside the rectum, constipation is a good example . Hemorrhoids can protrude either internally or externally, However, most veterinarians agreed that the dog's body is not set up like humans. Since it is, with a vertical digestive system, for the blood pressure to build there(1). However the real things that, really the animal could have problem with their anal sacs. Moreover, anal tumors, or a prolapsed rectum will be suspected instead. On the contrary , it has been postulated that the dogs can get hemorrhoids as a secondary symptom of another intestinal illness (2). Whether the truth is they can't get them at all or they can get them just not as a condition themselves is a question we must to worry about and discuss(3)

It has been documented that Hemorrhoids and anal sac disease might occur due to several causes such as , pain when defecating, pain when sitting, unprompted pain, anal itching, swelling around the anus, a lump in the rectum or anus and bleeding from the anus during defecation or not, with or without pain(4).

Diseased dogs may have blood when they defecate or blood on their butts, In addition, they will experience discomfort or pain when they go and they may act oddly try to defecate or even they be afraid to defecate. Nevertheless, diseased animal might lie down or sitting abnormally or, unusually, However, animals may scoot to relieve the itching(5).

II. Materials and Methods

Animal history and the present clinical and laboratory examinations of the diseased dog

A male, Mullinoise breed a police (K9) dog, 30 kg weight and of 4 years old, had been brought to the Veterinary Clinical Hospital, College of Veterinary Medicine, University of Basrah, Iraq, with an a patient history of discomfort , constipation for three days , defecation when occur with pain and straining, However, stool are stained with bright color blood. Partial loss of appetite. Furthermore, the animal has an history of complete deworming and vaccination programs.

On clinical examinations, the dog suffers from mild dehydration, slight tachycardia with body temperature (39.4C), In addition, the animal rises its butts upward and tries to lick the anal bend. Moreover, Finger palpation of the rectum(6), reveals small bulging gland like mass located at the left and right side of the anus with bad odor of the area .

Five milliliters of blood were collected for complete blood analysis. Automatic digital cell counter from Beckman USA are used .

III. Results

Anal sac disease or Hemorrhoids were suspected, As, the disease dog show signs of discomfort, especially when forced to set down, straining with difficult defecation Fig 1. The animal drags his butts upward or arch its back .Fig.2 , bad odors or scents comes from its anal area , animal tries to lick its anus sometimes, Moreover on rectal examination by a finger small bulging gland like mass located at the left and right side of the anus was detected and could be seen even from outside, Fig.3. Furthermore, the vital signs of the diseased dog show, body temperature (38.4C), the heart rate was 110/ min, respiratory rate of 33/ mint. Table 1. In addition, examination of blood parameters indicates a slight increase of PCV value. Table 2.



Fig 1: Straining with difficult defecation




Fig 2: Arching of the back

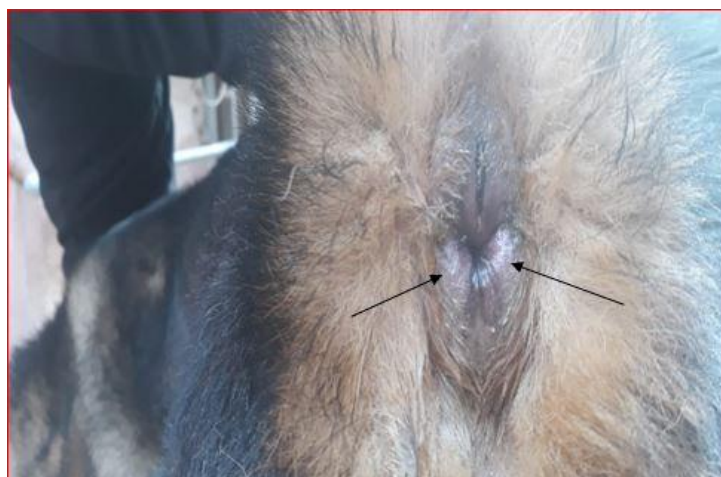

Fig 3: Small bulging gland like mass located at the left and right side of the anus

Table 1 : The vital signs of the diseased dog

Parameters	Diseased animal (dog)	The normal reference*
Body temperature / C	38.4	37.5-39.2
Heart rate / min	110	70-120
Respiratory rate/ min	33	15-30

**Ettinger and Feldman, 2005(1)*

Table 2: Hematological parameters of the diseased dog

Parameters	Diseased animal (dog)	The Normal Reference*
RBC x 10 ⁶	5.5	4.8-9.3
Hb g/dl	13.5	12.1-20.3
PCV %	59	37-55
TLC x 10 ³	9.3	4.0-15.5
Lymphocyte %	31	12-30
Neutrophils %	56	66-77
Eosinophils %	4	2-12
Monocytes %	9	3-10
Basophiles %	0	0.5-0.7
Total platelet counts x10 ³	245	170-400

**Ettinger and Feldman, 2005(1)*

IV. Discussion

It has been mentioned that the main clinical manifestations of anal sac problems and hemorrhoids are scooting, inflammation around the anus ,a potential abscess around the anus , licking the site, pain when defecating pain any time, a rupture causing blood and pus to come out, mostly same finding in this case (1)

Dogs have two anal sacs around the sides of their anus that produce scents. It's why they sniff each other's butts. Moreover, These glands were designed for dogs to mark their territory and they are supposed to be regularly expressed, naturally, when the dog goes poo, or manually. If that can't happen for some reason, the dog can develop serious problems, (7). It has been indicated that how a disease involving these sacs could easily have symptoms like as hemorrhoids. Furthermore, It can be even more confusing because digestive issues like diarrhea and straining to go poo can impact the anal sac's functioning, further making the problem appear to be dog hemorrhoids(8).On the other hand, Dogs can experience a rectal prolapsed, which causes a temporary or permanent protrusion from the anus that can look like hemorrhoids. It may only stick out before or during their defecation or it may be out all the time. The partial prolapsed requires medical treatment in about a day. Full prolapsed, where part of it sticks out all the time is a medical emergency(9). Furthermore, rectal prolapsed in dogs is often associated with straining to go poo or pee, so again, this reminds us of hemorrhoids. They can also get it after giving birth. The prolapsed itself should not be painful, but they may lick at it. It will start out pink, but as the condition worsens and circulation degrades, it will begin to turn darker in color(10).

Management and Treatment

A prescription of gentamycin 10% , 10mg /kgBW daily intramuscular for 3 days, in addition to per rectum application of a mixture containing Lidocaine hydrochloride and Fluocinolone acetonide in a creambase,

daily for 3 days has been made, as well as a description of two teaspoonful of mineral oil daily for lubrication was also prescribed.

The owner was advised to continue treatment. Moreover, Because the dog is having digestive issues, a diet higher in fiber may make them more regular, helping with any condition that become more worse by either straining or weak stools. Furthermore, a clean water must available, Since, water is also an important part of good digestion and therefore, regular, healthy stools.

The owner was also advised to get regular exercise for its diseased dog to promote better digestion and decreasing their chances for developing one of these conditions.

References

- [1]. Ettinger SJ, Feldman EC (2005) Text book of Veterinary Internal Medicine: Disease of Dog and Cat (6th edn). In: WB Saunders (Ed.), Philadelphia, USA
- [2]. Sherding RG (1996) Diseases of colon, rectum and anus, In Todd. R. Tams., Hand Book of Small Animal Gastroenterology. W. B. Saunders, Philedelphia, pp362-363 .
- [3]. Niebauer G (1993) Rectoanal diseases, In Bojrab, M. J, 4th ed. Current Techniques in Small Animal Surgery, Philedelphia, Lea and Febiger, pp 271-284
- [4]. Slatter D. (2003) Textbook of Small Animal Surgery, 3rd Ed. W.B. Saunders, Philadelphia
- [5]. Jattennavar PS, Kalmath GP (2010) Complete Rectal Prolapse In A Puppy – A Case Report. Indian J. Anim. Res. 44 (3) : 222 – 223.
- [6]. Slatter D. (2003) Textbook of Small Animal Surgery, 3rd Ed. W.B. Saunders, Philadelphia
- [7]. Evans H E, de Lahunta A (2013). Miller’s Anatomy of the Dog – E-Book. Elsevier Health Sciences. ISBN 978-0-323-26623-9.
- [8]. Petzler, Rex (2018) “All You Need to Know About Hemorrhoids in Dogs.” *PetPlus Blog*, www.blog.petplus.com/pet-plus-pups/all-you-need-to-know-about-hemorrhoids-in-dogs/#.
- [9]. Kumar P R, Neelima P (2015) Management Of Rectal Prolapse In German Shepherd Pup By Perianal Purse String Suture. Int. J. Agricul. Sci. 7(11).739-740.
- [10]. Simon M S, Shafiuzama M , Sooryadas S, ArunPrasad A, kumar RS (2009) Management Of Recurrent Rectal Prolapse In A Pup By Colopexy .Tamilnadu J. Vet. Ani. Sci. 5 (5) 276-278.

Kamal M.Alsaad. “Anal sac disease and /or Hemorrhoids of a Police K9 Dog (A Case Report).” *IOSR Journal of Agriculture and Veterinary Science (IOSR-JAVS)*, 13(2), 2020, pp. 05-08.