

Stage II Keratoconjunctivitis in a Goat: A Case report

*Faez Firdaus Jesse Abdullah^{1,3}, Nurul Syazwani Radzuan¹, Abdulnadir Tijjani^{2,5}, Lawan Adamu^{1,5}, Yusuf Abba^{2,5}, Konto Mohammed^{1,5}, Abdinasir Yusuf Osman^{1,2}, Noorashimah Roslim⁴, Dayang Norhaizam Awang⁴, Abdul Aziz Saharee¹, Mohammed Zamri Saad², Abdul Wahid Haron^{1,2}

¹Department of Veterinary Clinical Studies; ²Department of Veterinary Pathology and Microbiology; ³Research Centre for Ruminant Disease, ⁴University Veterinary Hospital, Faculty of Veterinary Medicine, Universiti Putra Malaysia, 43400 UPM Serdang, Selangor, Malaysia; ⁵Faculty of Veterinary Medicine, University of Maiduguri, PMB 1069, Borno State, Nigeria.

Abstract: A two year old Australian Feral male goat weighing 30 kg was presented to the large animal unit of Universiti Putra Malaysia Veterinary Hospital with the clinical signs of conjunctivitis and corneal ulceration with purulent ocular discharge. A sterile swab was taken from the eye for bacteriological culture and the culture yielded a mixed growth of *Pseudomonas aeruginosa* and *Moraxella caprae*. The condition was diagnosed as pink eye disease. The goat was administered 3ml of 20mg/kg oxytetracycline subconjunctival injection of 0.4ml, intravenous injection of 2.2mg/kg Flunixin meglumine (antipyretic) agent, topical application of terramycin eye ointment and infusion of 2L of 0.6% NaCl solution. The signs of conjunctivitis and corneal ulcers of the eye had substantially reduced five days post treatment. Quarantine of infected animals, good quality feeding and fly control was recommended as preventive measures.

Keywords: Pink eye, goat, *Moraxella caprae*, bacteriology

I. Introduction

Infectious Keratoconjunctivitis or commonly known as pink eye is a contagious bacterial disease of the eye. This infection will cause the inflammation of the tissue lining the eyelid, the cornea and conjunctiva ultimately causing ulceration which may progress to produce pain and worsen leading to temporary or permanent blindness (Jesse *et al.*, 2013). In sheep and goats, Keratoconjunctivitis may be associated with *Mycoplasma conjunctivae* and *Chlamydophila pecorum*. However, other aerobic bacteria can also lead to this condition, and these include *Pseudomonas* species and *Staphylococcus aureus* (Giacometti *et al.*, 2002). In cattle and sheep, *Listeria monocytogenes* has also been incriminated with keratitis resulting from direct inoculation of contaminated silage into the eye (Evans *et al.*, 2004). Important causative agent of pink eye in cattle is *Moraxella bovis* which is rarely involved in caprine Keratoconjunctivitis. A very closely related species, *Moraxella caprae* has been isolated from normal goats (Kodjo *et al.* 1995). According to Browning (2007), animals with conjunctivitis showed clinical signs such as eye discharge, red and swollen eyes, and formation of new blood vessels, cloudiness and ulceration. Pink eye is of major economic significance to livestock producers through decreased weight gain, decreased milk production, and treatment costs (Whittier *et al.*, 2009).

Case History

Two years old Australian Feral male goat weighing 30kg had reddish and opaque left eye was presented to Universiti Putra Malaysia Veterinary Hospital. The goat was managed intensively.

Upon physical examination, the goat was dehydrated; dull and depressed with rough hair coat and body condition score of 2/5 (Figure 1). The rectal temperature was high 40.9 °C indicative of pyrexia. Other vital parameters were within the normal range. Examination of the left eye revealed conjunctivitis, corneal ulceration and purulent discharges (Figure 2), while the right eye was normal (Figure 3).



Fig. 1: Shows goat with rough hair coat.

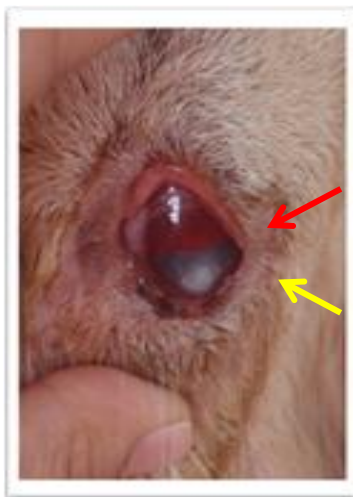

Fig. 2: Shows reddening of the conjunctiva (red arrow) and a corneal ulcer (yellow arrow) in the left eye.

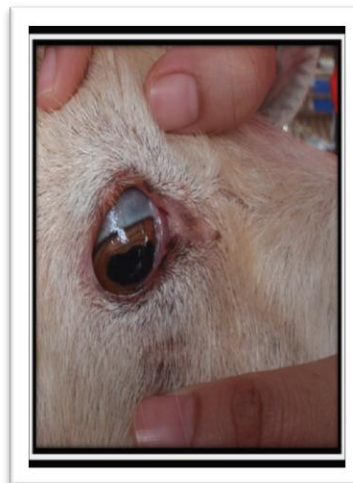


Fig.3: Shows a normal right eye.

Laboratory investigation

Asterile eye swab sample of the left eye was taken and sent to the Microbiology Laboratory, Faculty of Veterinary Medicine, Universiti Putra Malaysia for culture, isolation and identification. The laboratory investigation results revealed a mixed growth of *Pseudomonas aeruginosa* and *Moraxella caprae*.

Diagnosis

Based on the clinical signs of pyrexia, conjunctivitis, corneal ulcer, purulent ocular discharges and microbiology results, the case was diagnosed as pink eye (conjunctivitis).

Treatment

The goat was administered 3ml Oxytetracycline (20mg/kg) intramuscularly once, followed by a single dose of sub-conjunctival injection of 0.4ml oxytetracycline (20mg/kg) at the ventral conjunctival fornix to provide high localized antibiotic concentration at affected area. Terramycin eye ointment was prescribed to be applied topically three times daily (TID) for seven days. Flunixin meglumine was also given intravenously at the dosage of (2.2mg/kg) twice daily (BID) for three days, while a rehydration infusion of 2L of 0.9% Sodium Chloride was given intravenously.

Prognosis

The signs of conjunctivitis and corneal ulcer of the left eye has subsided on the fifth day of post treatment. Thus, the prognosis was good since the goat had showed positive response to the treatments given.

II. Discussion

Pink eye disease has been reported to progress through four stages according to severity. At stage 4, there is complete ulceration of the cornea, protrusion and sticking of the iris to the cornea with partial or complete blindness (Whittier *et al.*, 2009). The present case was diagnosed at the second stage of the disease since the ulcer (white spot) did not fully cover the cornea (figure 2). Stress has been reported as one of the predisposing factors to pink eye disease (Browning, 2007). In the present case report, the goat was said to have been transported from Australia and developed the condition two weeks on arrival into the farm. Transportation being one of the causes of stress could have precipitated the condition in the goat. Other predisposing factors include bright sunlight (Rathert, 2008) and dusty environment (Mathews, 2009). Poor hygiene condition in farms have been reported to be another predisposing factor to the disease, as this will attract flies which are mechanical vectors for the transmission of the causative agent (Drovers, 2011).

Both systemic and topical antibiotic treatments have been administered in the present case. Long acting oxytetracycline (20mg/kg) was administered intramuscularly as recommended (Whittier, 2009). Topical treatment has been reported to speed up the recovery process of the affected animal (Pugh and Baird, 2012). Terramycin eye ointment was prescribed to be applied topically three times daily. Subconjunctival injection has been reported to be effective if it remains localized (Mathews, 2009). In the present case 0.4ml of

oxytetracycline was injected at the subconjunctival region to provide high local concentration of the drug in the affected area. Early treatment of pinkeye is important, not only for a successful outcome of the individual animal affected, but also to stop the shedding of the bacteria in order to decrease the risk of transmission to other animals (Whittier, 2009). The prognosis in the present case was good since it was discovered early and treatment was promptly instituted.

III. Conclusion and recommendations

The chances for recovery are high if cases of pink eye are reported in time and immediate treatment instituted as reported in the present case. Quarantine of newly purchased animals, adequate quality feeding and fly control is recommended. In the present case the owner was advised to isolate the goat from the rest of the flock until full recovery is achieved.

Acknowledgement

The authors wish to acknowledge En Nazim Razali Kanini, En Mohd Jefri and Mr. Velloo of University Veterinary Hospital (UVH), and Faculty of Veterinary Medicine Universiti Putra Malaysia for their technical assistance.

References

- [1]. Browning, M. L. (2007). Keratoconjunctivitis (Pinkeye) in Goats. [Electronic version]. Extension Animal Scientist, Alabama A&M University, UNP-88.
- [2]. Drovers CattleNetwork news. (2011). Pinkeye and pinkeye prevention: Fly Control Resource Center retrieved October 24, 2013 from <http://www.cattlenetwork.com/cattle-resources/fly-control/Pinkeye-and-pinkeye-prevention-122872929.html>
- [3]. Faez Firdaus Jesse Abdullah, Lawan Adamu, Abdinasir Yusuf Osman, Abdul Wahid Haron and Abdul Aziz Saharee (2013). Clinical Management of stage III infectious bovine Keratoconjunctivitis associated with *Staphylococcus aureus* in a dairy cow: A case report. *Journal of Agriculture and Veterinary Science IOSR*, 4(4): 69-73.
- [4]. Gasparotto, S. W. (2009). Pinkeye in Goats. Retrieved October 29, 2013, from <http://www.tennesseeeatgoats.com/articles2/pinkeyeingoats.html>
- [5]. Giacometti, M., Janovsky, M., Belloy, L. and Frey, J. (2002). Infectious keratoconjunctivitis of ibex, chamois and other Caprinae. *Revue Scientifique et Technique (International Office of Epizootics)*, 21(2):335-345.
- [6]. Kodjo, A., Tonjum, T., Richard, Y., and Bovre., K. (1995). *Moraxella caprae* sp. nov., a New Member of the Classical *Moraxellae* with Very Close Affinity to *Moraxella bovis*. *Journal of Systemic Bacteriology*, 45(3), 467-471.
- [7]. Matthews, J. G. (2009). *Diseases of the Goat*. United Kingdom: Blackwell Publishing Ltd.
- [8]. Pugh D.G. and Baird A.N. (2012). *Sheep and goat medicine*. Missouri: Elsevier Saunders Inc
- [9]. Rathert, C.C. (2008). *Goat Diseases and Farm Herd- Health Safety*: University of South Carolina, Arnold School of Public Health.
- [10]. Whittier, W.D., Currin, N., and Currin, J. (2009). Pinkeye in Beef Cattle. Virginia Cooperative Extension, College of Agriculture and Life Sciences, Virginia Polytechnic Institute and State University, publication 400-750.