

## A Study of the Diode Laser Phototherapy for Enhancing Healing and Reduction of Microbial Count in Periodontal Pockets in A Saudi Population within Al-Taif

\*<sup>1</sup>Sherifa Mostafa M. Sabra

<sup>1</sup>(Corresponding Author, Consultant, Asst. Prof., Microbiology, Micro. Br., Biology Dept., Science College, Taif University, KSA)

---

**Abstract:** This search was carried out to clarify the effects of Diode Laser (DL) therapy on chronic periodontitis, by healing, reducing pockets depth and minimizing microbial counts. Patients (Pts) were 60 as study group (SG) and 15Pts as control group (CG), all were complained of chronic periodontitis. SG was received DL therapy and CG irrigation with normal saline. The treatment period had taken (10week): (phase1: Baseline) at 1<sup>st</sup> week, ( phase2: Treatment secessions) at 3<sup>rd</sup>, 5<sup>th</sup>, 7<sup>th</sup> and 9<sup>th</sup> week, and (phase3: Follow up) at 10<sup>th</sup> week. The mean prevalence of Clinical Dental Indices(CDI),which included PD were (6.6, 5.6, 4.5, 4.0, 3.6 and 3.1mm) and (6.6, 5.8, 4.8, 4.2, 3.9 and 3.5mm), PI were (2.7, 1.7, 1.2, 0.8, 0.4 and 0.2) and (2.7, 1.9, 1.4, 1.1, 0.9 ad 0.6), and BOP were (95, 66.7, 40, 25, 11.7 and 1.6%) and (96.7, 75, 63,3, 45, 31.7 and 25%) for SG and CG respectively. The mean prevalence of Colony Forming Units (CFUs)/ml were (500, 430, 335, 205, 80 and 15) and (500, 455, 400, 325, 255 and 165) for SG and CG respectively. DL irradiation had revealed anti-microbial effects and reduction of inflammation, which supported healing periodontal pockets through microbial elimination than old methods.

**Key words :** Diode Laser (DL), Chronic Periodontitis, Pockets, Microbial Counts, Patients (Pts), Clinical Dental Indices (CDI), Pocket Depths (PD), Plaque Index (PI), Bleeding on Probing (BOP), Colony Forming Units/ml (CFUs/ml).

---

### I. Introduction

Periodontitis is a microorganisms (MOs) related inflammatory disease causing destruction of tooth supporting tissues namely periodontal ligament and alveolar bone. Non-surgical treatment was based on the elimination of MOs deposits adhered to tooth surfaces, primarily by means of root scaling and planning. This method, together with dental plaque control is efficient in the treatment of periodontal diseases<sup>[1]</sup>. Er:YAG Laser can be used for soft tissue debridement, as an adjunct to mechanical debridement in access flap surgery. The adjunctive effects of DL in open flap debridement had been evaluated based on clinical and MOs parameters. There was a statistically significant difference in PI at baseline and at 2months in control and test groups. PI score became <1 at the 4<sup>th</sup> week post-operatively after the second lasing session suggesting maintenance of fair oral hygiene. BOP decreased significantly from baseline to 8weeks in test group rather than control group. Effectiveness of mechanical SRP+Laser Radiation (LR) in reducing signs of inflammation due to the effective removal of calculus and infected granulation tissue<sup>[2]</sup>. DL provides a non-antibiotic solution, anaerobic MOs had also been found in atherosclerotic plaques<sup>[3]</sup>. It is an excellent soft tissue laser because of its tissue coagulating and haemostatic properties, mode of antisepsis has several potential advantages over traditional biochemical antibiotics. A therapeutic dose can be delivered to a greater depth locally and leaves no residual concentration<sup>[4]</sup>. Most conventional methods used to treat the disease involve disruption of the biofilm by mechanical removal of sub-gingival plaque and sometimes, the adjuvant use of anti-microbial agents and mechanical surgical debridement of pocket and root surfaces damaged as a result of periodontal disease. An alternative approach would be to get rid of the putative MOs. Non-surgical therapy leads to resolution of inflammation, reduction bacterial load, and reduction probing pocket depth<sup>[5]</sup>. DL is considered selective eradication of bacteria, those making such claims must also consider that periodontitis is a mixed infection involving at least 30 or more MOs spp., of oral bacteria that formally belonged to the anaerobic genus need not be present in large numbers to dictate disease initiation or progression. *Porphyromonas gingivalis* is as a “keystone” member of the sub gingival microbial biofilm, it designation indicates that while this MOs resides in low numbers within the periodontal pocket it still has the ability to dictate host immune cell response<sup>[6]</sup>. DL has been evaluated its potential in relation to its biocompatibility and to its ability in reducing bacterial counts<sup>[7]</sup>. Instrumentation is not possible in inaccessible areas such as furcation, grooves, and concavities<sup>[8]</sup>. DL (1.4W/30s) did not cause any signs of thermal effects such as charring, necrosis or fusion on the root<sup>[9]</sup>. Er:YAG Laser was used for debridement during access flap surgery and noted promoted more new bone formation. The bactericidal effect of DL is evident from the reduction in the CFUs/ml of obligate anaerobes. It is anti-microbial in tissues because

of deeper penetration of Laser energy, it had role in anti-microbial and promoting formation of new attachment<sup>[10]</sup>. It has a wave length of 810nm or (910–980nm), does not interact with dental hard tissues, an excellent soft tissue surgical Laser, indicated for cutting and coagulating gingiva and oral mucosa and for soft tissue curettage or secular debridement. it also has a bactericidal effect<sup>[11]</sup>. Surgical therapy performed in cases with persistent inflammation, deeper pockets and intra-bony defects provides better accessibility to root surfaces as well as osseous defects. MOs persist in the mixed *spp.* plaque biofilm on tooth surfaces, adhere to and enter the epithelial cells, and are tissue invasive in nature<sup>[12]</sup>. DL therapy has attracted attention recently as a potential alternative or adjunct to conventional mechanical debridement. CO<sub>2</sub>, (Nd:YAG), DL and (Er:YAG) Laser have been used in the therapy of periodontal pocket for soft tissue management<sup>[13]</sup>. DL it is one of the cheaper high intensity Laser, machine used is small and light, portable Lasers, as a group, have inconsistently demonstrated the ability to reduce MOs. within a periodontal pocket<sup>[14]</sup>. A part of DL energy scatters and penetrates during irradiation into periodontal pockets. The attenuated Laser at a low energy level might then stimulate the cells of surrounding tissue resulting in reduction of inflammatory conditions in cell proliferation, increased flow of lymph improving the periodontal tissue attachment and possibly reducing postoperative pain<sup>[15]</sup>. There was a statistically significant reduction in the number of CFUs/ml of anaerobes MOs in SG compared with CG. The wave length of DL was absorbed by anaerobic peri pathogens. This led to vaporization of water and caused lysis of the cell wall of the bacteria, leading to cell death. It was effective against the tissue invasive peri pathogens caused by absorption of Laser energy up to 1-2mm in the deeper tissues<sup>[16]</sup>. It has been hypothesized that the charred layer that forms on the undersurface of the flap prevents the epithelial migration and promotes new attachment. Provided histological evidence of formation of new cement, periodontal ligament, and bone<sup>[17]</sup>. The choice of high-intensity DL was supported, primary interest was that laser could be effective and also safe<sup>[18]</sup>. MOs as *Porphyromonas*, *Prevotella*, and *Bacteriodes* constitute less than 20% of the total sub gingival microbial flora. If the possibility of selective eradication of bacteria by DL is considered, it must be put into consideration that periodontitis is a mixed infection involving MOs *spp.*<sup>[19]</sup>. Periodontal disease is a chronic inflammatory disease caused by a bacterial infection, hence the bactericidal and detoxifying effect of DL treatment is advantageous in periodontal therapy, has bactericidal effectiveness<sup>[20]</sup>. It affects equally extracellular and intracellular pigmented pathogens, has the potential to breach the protective mechanisms of biofilms<sup>[21]</sup>. Soft tissue DL and Nd:YAG have the potential for curettage of pocket wall and disinfection of periodontal pockets<sup>[22]</sup>. A significant suppression of *Actinomyces comitans*, an invasive bacterium that is associated with aggressive forms of periodontal disease that are not readily treated with conventional SRP. It's also invades the adjacent soft tissues, making it difficult to be removed by mechanical periodontal instrument alone<sup>[23]</sup>. Sub gingival DL therapy, that relatively low numbers of highly pathogenic anaerobic MOs, make it difficult to totally eradicate. Yet marketing statements continue to be made regarding “pocket sterilization” and assertions that DL and Laser wave lengths selectively destroy if the possibility of selective eradication of bacteria by DL is considered, those making such claims must also consider that periodontitis is a mixed infection involving at least 30 or more MOs *spp.* How the wavelength of the various DLs are related to selective destruction of black/brown-pigment-producing bacteria<sup>[24]</sup>. Positive results both dental clinical as well as microbial using the same type of DL<sup>[25]</sup>. The reduction of pocket depth was significantly greater in the Laser group at 4-8 weeks after Lasing. DL is an excellent soft tissue and available in smaller cost-effective units. The radiation of DL shows greater absorption and less penetration, especially in blood-rich tissue. The wavelength of DL is absorbed by the haemoglobin, which leads to tissue coagulation and formation of charred layer. DL leads to thermo coagulation of blood vessels, which is responsible for its haemostatic effect<sup>[26]</sup>. It's are very effective for soft tissue applications including incision, haemostasis and coagulation<sup>[27]</sup>. It advantages, include a bloodless operating field, minimal swelling and scarring, and much less or no postsurgical pain. When DL surgical procedures are carried out, the surface produced heals favorably as an open wound, without need for sutures or surgical dressings. Its verified the lethal effect of DL radiation on MOs. associated with periodontitis<sup>[28]</sup>.

**The aim:** Evaluation the usage of DL therapy effect on Pts as recent irradiation treatment through measuring the CDI which included (PD, PI and BOP) and the reducing of MOs count as CFUs/ml. Followed up the healing processes during treatment period of Pts, which had complained from chronic periodontitis, else by comparing the results between the research working groups (SG and CG).

## II. Materials and Methods

- **Preparation program:** This study had been conducted at Taif area, in year 2014, in private dental clinics. A total number were of Pts=75, aged were (22-47yrs.), all were selected and they had complained of chronic periodontitis. Private clinics owners, Dentists and Pts had been signed a consent form, that for research work on condition of without any memorization of personal information's. Pts were divided into SG=60 Pts and CG=15 Pts. Treatment period had been continued for 10 weeks, it had been included phase1 (Baseline): were contained the 1<sup>st</sup> week, phase2 (Treatment secessions): 3<sup>rd</sup>, 5<sup>th</sup>, 7<sup>th</sup> and 9<sup>th</sup> week and phase3 (Follow up): 10<sup>th</sup> week. During phase1 all Pts had been received non-surgical periodontal treatment, included scaling, root

planning and coronal polishing (SRP) and at the initial of treatment period all Pts had been received Oral Hygiene Instruction (OHI) and supra and sub-gingival ultrasonic scaling of all teeth. Two weeks after scaling, SG were received both (SRP+DL), in 4consecutive sessions with two weeks apart, while CG were received saline irrigation only. CDI parameters had been measured and microbial specimens had been collected for each Pts through the treatment period at every weeks had been mentioned.

- **Dental program:**
    - **CDI measurement:**
      - **PD:** That named periodontal pocket assessment, six sitesper tooth were measured with a Periodontal Probe (Hu-Friedy ® Co.).
      - **PI:** Its developed assesses the thickness of plaque at the cervical margin of the tooth. Scores are: Zero=no plaque present, 1=film of plaque present on the tooth, 2=moderate accumulation of soft deposits in the gingival pocket or on the tooth, 3=abundance of soft matter within the pocket or on the tooth. Four ratings assigned: 0=excellent, 0.1-0.9=good, 1.0-1.9=fair, 2.0-3.0=poor
      - **BOP:** An early sign of gingivitis is bleeding on probing and described it as the Sulcus Bleeding Index (SBI). Scores are: Score0=healthy looking papillary and marginal gingiva no bleeding on probing. Score1=healthy looking gingiva, bleeding on probing. Score2=bleeding on probing, change in color, no edema, Score3=bleeding on probing, change in color, slight edema. Score4=bleeding on probing, change in color, obvious edema. Score5=spontaneous bleeding, change in color, marked edema<sup>[29]</sup>.
    - **DL treatment:** Following scaling, DL equipment (Discus Soft Laser Pro, LLC of ZAP Lasers, Culver City,CA90232 USA) with a wave length of 808±5 nm, were delivered by a400-µm diameter fiber optic device was used for this trial. After tooth debridement, and coronal polishing of teeth, the fiber optic was introduced in the periodontal pocket parallel to the long axis of the tooth, 1mm coronal to the base of the pocket, and it was moved coronal with sweeping movements, using a power of 1.5W, 20s and power of density of 1,193.7W/cm<sup>2</sup>.
  - **Microbial program:**
    - **Specimens collection:** Specimens were collected from each Pts, at 1<sup>st</sup>, 3<sup>rd</sup>, 5<sup>th</sup>, 7<sup>th</sup>, 9<sup>th</sup> and 10<sup>th</sup> week, aseptically with sterile paper tips from periodontal pockets for evaluation of CFUs/ml.
    - **CFUs/ml evaluation:** Specimens were transported in Robertson’s cooked meat media to the Microbiology Laboratory within 1hr., of collection. CFUs/ml of MOs were calculated by:  $Y \times 10^{-d} \times 1/V$  (d=dilution, V=volume plated and Y=colony count on the between 30 and 300)<sup>[30]</sup>.
- Data Analysis:** The data were recorded and entered into Microsoft Excel Sheet, then summarized and analyzed<sup>[31]</sup>.

### III. Results and discussion

**Table and figure1: The mean prevalence of \*CDI during treatment phases**

Item	Group	*CDI					
		Study group (SG) *No.=60*Pts			Control group (CG) *No.= 15*Pts		
Phase	Week	*PD mm	*PI	*BOP	*PD mm	*PI	*BOP
Phase 1: Baseline	1 <sup>st</sup> week	6.6	2.7	95%	6.6	2.7	96.7%
Phase 2: Treatment secessions	3 <sup>rd</sup> week	5.6	1.7	66.7%	5.8	1.9	75%
	5 <sup>th</sup> week	4.5	1.2	40%	4.8	1.4	63.3%
	7 <sup>th</sup> week	4.0	0.8	25%	4.2	1.1	45%
	9 <sup>th</sup> week	3.6	0.4	11.7%	3.9	0.9	31.7%
Phase 3: Follow up	10 <sup>th</sup> week	3.1	0.2	1.6%	3.5	0.6	25%

*\*No.: Number, \*Pts: Patients, \*CDI: Clinical Dental Indices, \*PD: Probing Depth, \* PI: Plaque Index, \* BOP: Bleeding on Probing*

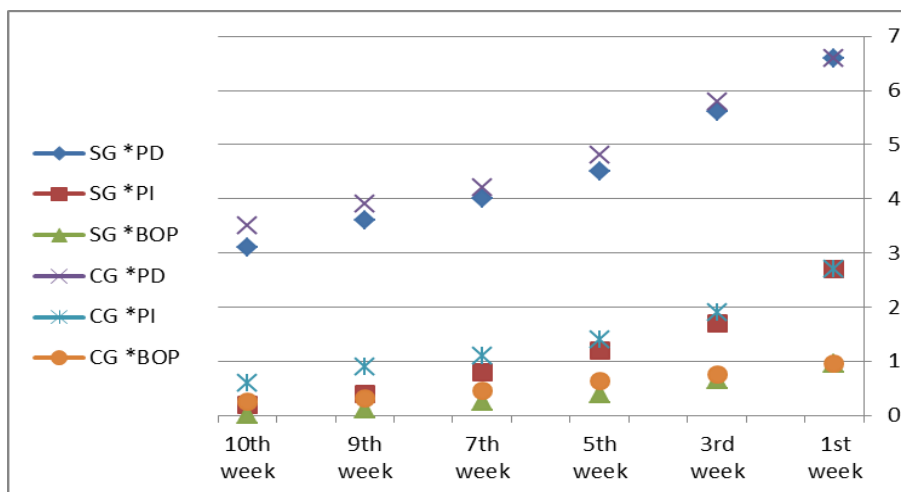


Table and figure1 showed the mean prevalence of CDI during treatment phases, that PD were (6.6, 5.6, 4.5, 4.0, 3.6 and 3.1mm) and (6.6, 5.8, 4.8, 4.2, 3.9 and 3.5mm) for SG and CG. PI were (2.7, 1.7, 1.2, 0.8, 0.4 and 0.2) and (2.7, 1.9, 1.4, 1.1, 0.9 and 0.6) for SG and CG. BOP were (95, 66.7, 40, 25, 11.7 and 1.6%) and (96.7, 75, 63.3, 45, 31.7 and 25%) for SG and CG respectively. That results had showed the differences in PD were 3.1 to 3.5mm, in PI were 0.2 to 0.6, in BOP were 1.6 to 25% for SG and CG respectively. The differences were resulted had revealed significantly clear which confirmed DL therapy than old methods. There was a significant improvement of the studied clinical parameters in PD, PI and BOP for SG than CG. PI score became <1 at the 4<sup>th</sup> week post-operatively after the second lasing session suggesting maintenance of fair oral hygiene. BOP decreased significantly from baseline to 8weeks in test group rather than control group. Effectiveness of mechanical SRP+LR in reducing signs of inflammation due to the effective removal of calculus and infected granulation tissue<sup>[2]</sup>. DL provides in atherosclerotic plaques and there has been evidence<sup>[3]</sup>. It is an excellent soft tissue laser because of its tissue coagulating and haemostatic properties<sup>[4]</sup>. Non-surgical therapy leads to resolution of inflammation and reduction probing pocket depth<sup>[5]</sup>. Er:YAG Laser was used for debridement during access flap surgery and noted promoted more new bone formation<sup>[10]</sup>. It is an excellent soft tissue surgical Laser, indicated for cutting and coagulating gingiva and oral mucosa, and for soft tissue curettage or secular debridement<sup>[11]</sup>. DL therapy has attracted attention recently as a potential alternative. It had been used in the therapy of periodontal pocket for soft tissue management<sup>[13]</sup>. It is one of the cheaper high intensity Laser, machine used is small and light<sup>[14]</sup>. A part of DL energy scatters and penetrates during irradiation into periodontal pockets. The attenuated Laser at a low energy level might then stimulate the cells of surrounding tissue resulting in reduction of inflammatory conditions in cell proliferation, increased flow of lymph improving the periodontal tissue attachment and possibly reducing postoperative pain<sup>[15]</sup>. It was effective against the tissue invasive peri pathogens caused by absorption of Laser energy up to 1-2mm in the deeper tissues<sup>[16]</sup>. It has been hypothesized that the charred layer that forms on the undersurface of the flap prevents the epithelial migration and promotes new attachment. Provided histological evidence of formation of new cement, periodontal ligament and bone<sup>[17]</sup>. It could be effective and also safe<sup>[18]</sup>. The reduction of pocket depth was significantly greater in the Laser group at 4-8weeks after lasing. DL is an excellent soft tissue and available in smaller cost-effective units. It shows greater absorption and less penetration, especially in blood-rich tissue. The wavelength of DL is absorbed by the haemoglobin, leads to tissue coagulation and formation of charred layer. It leads to thermo coagulation of blood vessels, responsible for its haemostatic effect<sup>[26]</sup>. DLs are very effective for soft tissue applications including incision, haemostasis and coagulation<sup>[27]</sup>. Its advantages, include a bloodless operating field, minimal swelling and scarring, and much less or no postsurgical pain. When its surgical procedures are carried out, the surface produced heals favorably as an open wound, without need for sutures or surgical dressings, verified the lethal effect of DL associated with dental periodontitis<sup>[28]</sup>.

**Table2 and figure2&3: The mean prevalence of \*CFUs/ml during the treatment phases**

Item	Week	Group			
		Study group (SG) *No.=60*Pts		Control group (CG) *No.= 15*Pts	
Phase	Week	*CFUs/ml			
		%	*No.	%	*No.
Phase 1: Baseline	1 <sup>st</sup> week	100%	500	100%	500
Phase 2: Treatment	3 <sup>rd</sup> week	86%	430	91%	455

secessions	5 <sup>th</sup> week	67%	335	80%	400
	7 <sup>th</sup> week	41%	205	65%	325
	9 <sup>th</sup> week	16%	80	51%	255
Phase 3: Follow up	10 <sup>th</sup> week	3%	15	33%	165

\*No.: Number, \*Pts: Patients, \*CFUs/ml: Colony Forming Units/ml

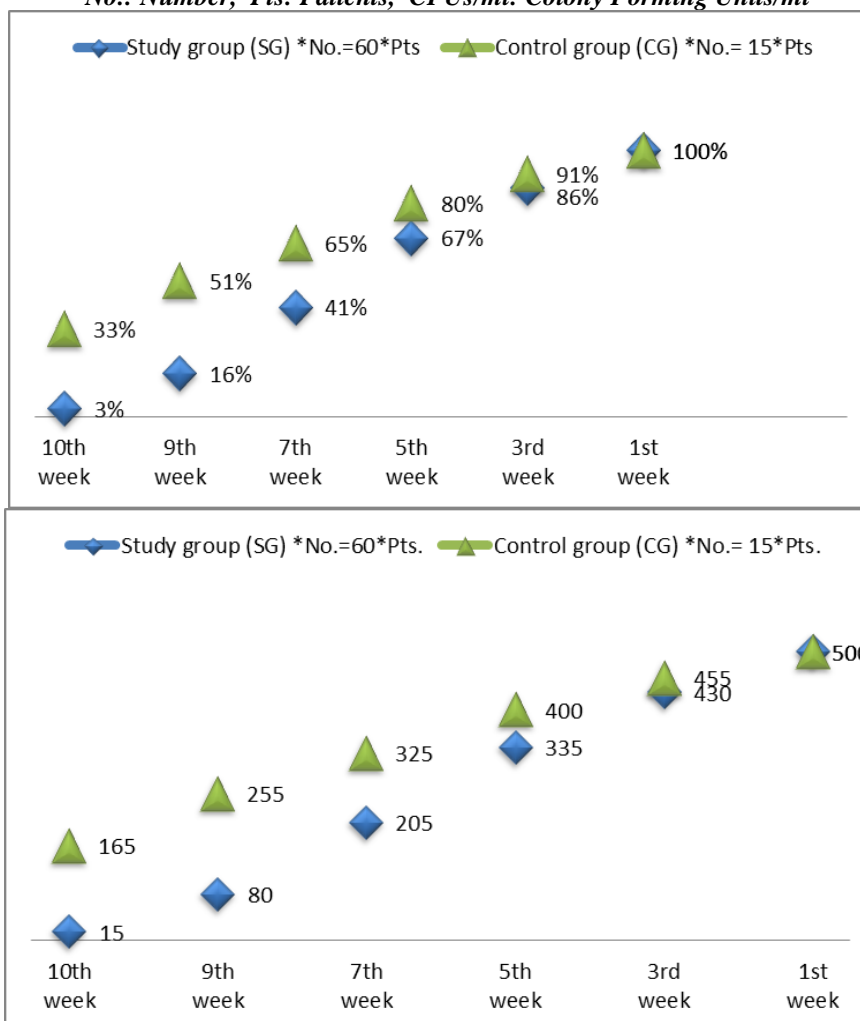


Table 2 and figure 2 & 3 showed the mean prevalence of CFUs/ml during the treatment phases, that were in percentage as (100, 86, 67, 41, 16 and 3%) and (100, 91, 80, 65, 51 and 33%) for SG and CG. On the other hand CFUs/ml by numbers were as (500, 430, 335, 205, 80 and 15) and (500, 455, 400, 325, 255 and 165) for SG and CG respectively. That results showed at the end of the treatment period the CFUs/ml were 3%=15 for SG and 33%=165 for CG, so that had appeared the significant difference between treatment method and healing pathway by reducing the CFUs/ml in SG more than and CG by different in CFUs/ml as 30%=150 MOs, that had indicated the DL therapy is more effective and takes short healing time with its beneficially in reducing CFUs/ml during the treatment of chronic periodontitis other than the old or surgical treatment methods. It's had improved the healing process completely and reduction of microbial counts in SG than CG. Periodontitis is a MOs related inflammatory disease causing destruction of tooth supporting tissues namely periodontal ligament and alveolar bone. Non-surgical treatment was based on the elimination of MOs deposits adhered to tooth surfaces, primarily by means of root scaling and planning<sup>[1]</sup>. The adjunctive effects of DL in open flap debridement had been evaluated based on MOs parameters<sup>[2]</sup>. It provides a non-antibiotic solution, anaerobic MOs had also been found in atherosclerotic plaques and there has been evidence to suggest that<sup>[3]</sup>. It is an excellent soft tissue laser because mode of antiseptics has several potential advantages over traditional biochemical antibiotics<sup>[4]</sup>. An alternative approach would be to get rid of the putative MOs. Non-surgical therapy leads to reduction bacterial load<sup>[5]</sup>. DL is considered selective eradication of bacteria, those making such claims must also consider that periodontitis is a mixed infection involving at least 30 or more MOs spp., of oral bacterial<sup>[6]</sup>. DL has been

evaluated its potential in relation to its biocompatibility and to its ability in reducing bacterial counts<sup>[7]</sup>. The bactericidal effect of DL is evident from the reduction in the CFUs/ml of obligate anaerobes MOs. It is antimicrobial in tissues because of deeper penetration of laser energy<sup>[10-11]</sup>. It is one of the cheaper high intensity Laser, machine used is small and light, have inconsistently demonstrated the ability to reduce MOs within a periodontal pocket<sup>[14]</sup>. There was a statistically significant reduction in the number of CFUs/ml of anaerobes MOs in SG compared with CG. The wave length of DL was absorbed by anaerobic peri pathogens, lead to vaporization of water and caused lysis of bacterial cell wall, leading to cell death<sup>[16]</sup>. MOs of the total sub gingival microbial flora, its possibility of selective eradication by DL is considered.<sup>[19]</sup> The bactericidal and detoxifying effect of DL treatment is advantageous in periodontal therapy, has bactericidal effectiveness on treatment of periodontal diseases<sup>[20]</sup>. DL affects equally extracellular and intracellular pigmented MOs. Laser energy has the potential to breach the protective mechanisms of biofilms<sup>[21]</sup>. Sub gingival Laser therapy, that relatively low numbers of highly pathogenic anaerobic MOs. Yet marketing statements continue to be made regarding “pocket sterilization” and assertions that DL and Laser wave lengths selectively destroy if the possibility of selective eradication of MOs by DL is considered, those making such claims must also consider that periodontitis is a mixed infection involving at least 30 or more MOs *spp*. How the wavelength of the various DLs are related to selective destruction of black/brown-pigment-producing bacteria<sup>[24]</sup>. Positive results of microbial using the same type of DL<sup>[25]</sup>. Its verified the lethal effect of DL radiation on MOs associated with periodontitis<sup>[28]</sup>.

#### **IV. Conclusions**

DL therapy had provided additional benefits of non-surgical periodontal treatment, it was well tolerated by the Pts, and it had demonstrated a significant bactericidal effect, can form an integral part of periodontal therapy in the future. It had effected on clinical as showed in CDI parameters were included (PD, PI and BOP) and on MOs eradication as in CFUs/ml, which effect on specific MOs and had appeared clear by decolonization. After 10 weeks of the treatment period had been evaluated the treatment by the effects on healing and CFUs/ml. A comparison had been between the initial and the final results of SG and CG for studying through CDI and CFUs/ml, that had been revealed irradiation with DL facilitates considerable enhancing healing through CDI and reducing MOs counts by elimination through CFUs/ml, more obviously had clarification in SG than CG, that all had been from the experimental periodontal pocket treatment during 10 weeks.

#### **V. Acknowledgments**

Most grateful had been sent to the following partners; Private Clinics Owners, Dentists, Pts, and Microbial Lab. Staff for their helpful had been assisted in the producing of this research paper work.

#### **VI. References**

- [1]. Akoi, M., 2008. Current status of clinical laser applications in periodontal therapy. *General Dentistry*, 3:674-687.
- [2]. Lindhe, J. and Nyman, S., 1985. Scaling and granulation tissue removal in periodontal therapy. *J. Cline. Periodontal*, 12:374-388.
- [3]. Gold, V., 1994. Pulsed laser beam effects on gingival. *J. Cline. Periodontal*, 21:391-393.
- [4]. Centy, I., Blank, L., Levy, B., Romberg, E. and Barnes, D., 1996. Carbon dioxide laser for de-epithelialization of periodontal flaps. *J. Periodontal.*, 68:763-769.
- [5]. Darveau, R., Tanner, A. and Page, R., 1997. The microbial challenge in periodontitis. *Periodontal.*, 14:12-32.
- [6]. Socransky, S., Haffajee, A. and Cugini, M., 1998. Microbial complexes in sub gingival plaque. *J. Cline. Periodontal.*, 25:134-144.
- [7]. Moritz, A., Schoop, U., Goharkhay, K. and Schauer, P., 1998. Treatment of periodontal pockets with a diode laser. *Lasers Surg. Med.*, 22:302-311.
- [8]. Schenk, G., Flemmig, T., Lob, S., Ruckdeschel, G. and Hickel, R., 2000. Lack of antimicrobial effect on periodontal pathic bacteria by ultrasonic and sonic scalers in vitro. *J. Cline. Periodontal.*, 27:116-119.
- [9]. Kreisler, M., Daublander, M., Willershausen-Zonnchen, B. and D'Hoedt, B., 2001. Effect of diode laser irradiation on the survival rate of gingival fibroblast cell cultures. *Laser Surg. Med.*, 28:445-450.
- [10]. Saygun, I., Sahin, S., Zdemir, A., Kurtis, B., Yapar, M., Kubar, A. and Ozcan, G., 2002. Detection of human viruses in patients with chronic periodontitis and the relationship between viruses and clinical parameters. *J. Periodontal.*, 73:1437-1443.
- [11]. Yilmaz, S., Kuru, B., Kuru, L., Noyan, U., Argun, D. and Kadir, T., 2002. Effect of gallium arsenide diode laser on human periodontal disease: a microbiological and clinical study. *Lasers Surg. Med.*, 30:60-66.
- [12]. Ishikawa, I. and Baehni, P., 2004. Nonsurgical periodontal therapy—where do we stand now?. *Periodontal.*, 36:9-13.
- [13]. Aoki, A., Sasaki, K., Watanabe, H. and Ishikawa, I., 2004. Lasers in non-surgical periodontal therapy. *Periodontal.*, 36:90-97.
- [14]. Kreisler, M., Al-Haj, H. and D'Hoedt, B., 2005. Clinical efficacy of semiconductor laser application as an adjunct to conventional scaling and root planning. *Laser Surg. Med.*, 37:350-355.
- [15]. Quadri, T., Miranda, L., Tuner, J., and Gustafsson, A., 2005. The short term effects of low level lasers as adjunct therapy in treatment of periodontal inflammation. *J. Cline. Periodontal.*, 32:714-719.
- [16]. Castro, G., Gallas, M., Nunez, I., LeyesBorrajó, J. and Garcivarcla, L., 2006. Histological evaluation of the use of diode laser as an adjunct to traditional periodontal treatment. *Photo med. Laser Sur.*, 24:64-68.
- [17]. Mizutani, K., Aoki, A., Takasaki, A., Kinoshita, A., Hayashi, C., Oda, S. and Ishikawa, I., 2006. Periodontal tissue healing following flap surgery using an Er:YAG laser in dogs. *Lasers Sur. Med.*, 38:314-324.
- [18]. Haypek, P., Zezell, D., Bachmann, L. and Marques, M., 2006. Interaction between high-power diode laser and dental root surface. Thermal, morphological and biocompatibility analysis. *J. Oral Laser Appl.*, 6:1-9.

- [19]. Paster, B., Olsen, I., Aas, J. and Dewhirst, F., 2006. The breadth of bacterial diversity in the human periodontal pocket and other oral sites. *Periodontal.*, 42:80-87.
- [20]. Ciancio, C., 2006. Wound healing of periodontal pockets using the diode laser, *Applications of 810nm Diode Laser Technology. A Clinical Forum*, 2:14-17.
- [21]. Gaspirc, B. and Skaleric, U., 2007. Clinical evaluation of periodontal surgical treatment with an Er:YAG laser: 5-year results. *J. Periodontal.*, 78:1864-1871.
- [22]. Ribeiro, I., Sbrana, M., Esper, L. and Almeida, A., 2008. Evaluation of the effect of the GaAlAs laser on sub gingival scaling and root planning. *Photo med. Laser Sur.*, 26:387-391.
- [23]. Ishikawa, I., Aoki, A., Aristeo, A., Takasaki, K., Sasaki, K. and Izumi, Y., 2009. Application of lasers in periodontics: true innovation or myth?. *Periodontal.*, 50:90-126.
- [24]. Christopher, H. and Blackburn, P., 2011. laser physics. *RDH.*, 31:66-72.
- [25]. De-Micheli, G., Andrade, A., Alves, V., Seto, M., Pannuti, C. and Cai. S., 2011. Efficacy of a high intensity diode laser as an adjunct tonon-surgical periodontal treatment: a randomized controlled trial. *Laser Med. Sci.*, 26:43-48.
- [26]. Chow, R., Armati, P., Laakso, E., Bjordal, J. and Baxter, G., 2011. Inhibitory effects of laser irradiation on peripheral mammalian nerves and relevance to analgesic effects: a systematic review. *Photo med. Laser Sur.*, 29:365-381.
- [27]. Euzebio, V., Andrade, A., Toaliar, M., Conde, M., Zezell, M., Cai, S. and Micheli, G., 2012. Clinical and microbiological evaluation of high intensity diode laser adjutant to non-surgical periodontal treatment: a 6month clinical trial. *Cline. Oral. Invest., DOI.*, 35:100-107.
- [28]. Gokhale, S., Padhye, A., Byakod, G., Jain, S., Padbidri, V. and Shivaswamy, S., 2012. A Comparative Evaluation of the Efficacy of Diode Laser as an Adjunct to Mechanical Debridement Versus Conventional Mechanical Debridement in Periodontal Flap Surgery: A Clinical and Microbiological Study. *Photo med. and Laser Sur.*,30:598-603.
- [29]. Muhlemann, H. and Son, S., 1971. Gingival sulcus bleeding-a leading symptom in initial gingivitis. *Helvetica Odontology. Act.*, 15:107-113.
- [30]. Cai, Z., Niladri, C., Wenchao, J., Conrad, C., Jean, P. and Raymond, M., 2011. Optimized digital counting colonies of congenic assays using Image software and customized macros: comparison with manual counting. *Int. J. of Radiation Bio.*, 87:1135-1146.
- [31]. Coulombier, D., Fagan, R., Hathcock, L. and Smith, C., 2001. *Epi Info 6 Version 6.04.A Word Processing, Database and Statistical Program for Public Health.* Centers for Disease Control and Prevention, Atlanta, Delaware, USA.