

# Cavernous sinus meningioma revealed by ophthalmic involvement: a case report

salma hassina,hasnaoui I,Krichene MA,Tebbay N,Bardi C,Hazil Z,Akkanour Y,Serghini L,Abdallah EL

*1 ophthalmology B specialty hospital rabat morocco*  
*[drsalmahassina@gmail.com](mailto:drsalmahassina@gmail.com) phone num : +212626069914*

---

## **Abstract**

*The case involves a 51-year-old woman who has ptosis and paralysis of the third cranial nerve. These conditions are caused by a meningioma located in the cavernous sinus. The diagnosis was confirmed through a cerebral MRI. Considering the complexity of the meningioma's involvement with surrounding vascular-nervous structures, gamma radiosurgery is being considered as a treatment option. The focus is on using a multidisciplinary approach and customized interventions to manage neurogenic ptosis caused by cavernous sinus meningiomas.*

**KEYWORDS :** *meningioma,cavernous sinus,ptosis,radiosurgery*

---

Date of Submission: 09-06-2024

Date of Acceptance: 21-06-2024

---

## **I. Introduction**

Any local lesion that compresses the third cranial nerve can cause ptosis, which can be painful. Imaging examinations can reveal various tumors, such as meningiomas, metastases, and pituitary tumors.

Meningiomas in the cavernous sinus are generally rare and benign. They make up 1.8% of all intracranial meningiomas and 41% of all cavernous sinus tumors. Clinical symptoms are mainly dominated by cavernous sinus syndrome, which affects the third, fourth, and sixth cranial nerves. Radiological diagnosis is based on CT data, specifically magnetic resonance imaging (MRI), which allows for visualization of the relationships between the meningioma and intracavernous structures.

### **Case**

A 51-year-old female patient with no previous history was referred to us for a left ptosis with paralysis of III occurring one year ago with a progressive decline in visual acuity. Ophthalmological examination revealed severe ptosis (figure 1) with paralysis of elevation, lowering and adduction of the eyeball. There was hypoesthesia in the V1 territory, but not in the V2 territory, a visual acuity a finger movement to the left, an incipient cataract with papillary pallor at the fundus, and examination of the right eye was normal with an acuity of 8/10.

An etiological work-up (cerebral MRI) (figure 2) was carried out, showing a process occupying the left cavernous sinus, measuring approximately 36×20×26 iso, intense in T1/T2, in favour of a meningioma of the left cavernous sinus, with local extension and advanced vasculo-nervous involvement (IC intra- and supra-cavernous ophthalmic artery, cerebellar artery, M1 segment of the sylvian artery, V nerve, at the level of meckel's cavum, trigeminal ganglion, nerves 3,4,6, and part of the optic nerve, partial infiltration of the inferior orbital fissure). The patient was referred to neurosurgery for management, where they proposed gamma knife radiosurgery: with annual monitoring.

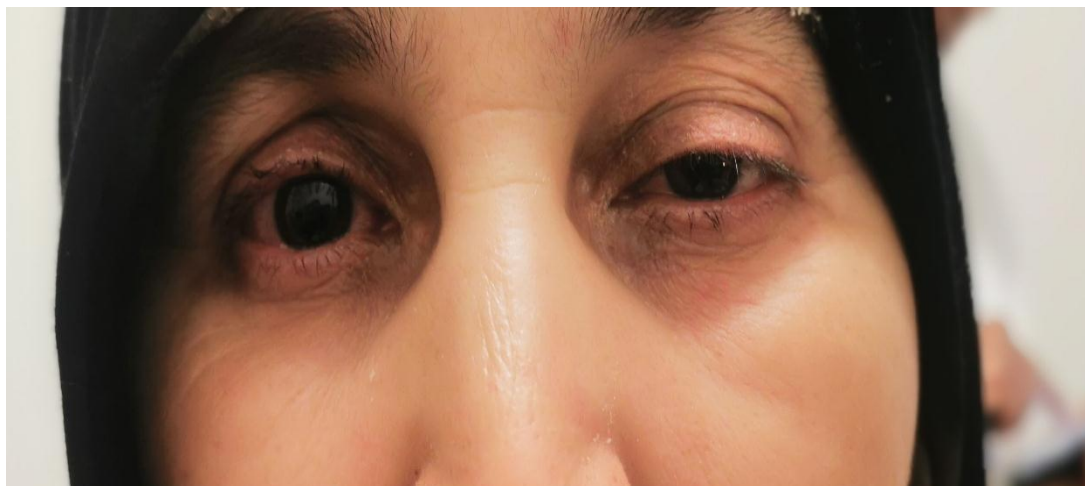


FIGURE 1 ; Image showing severe ptosis.

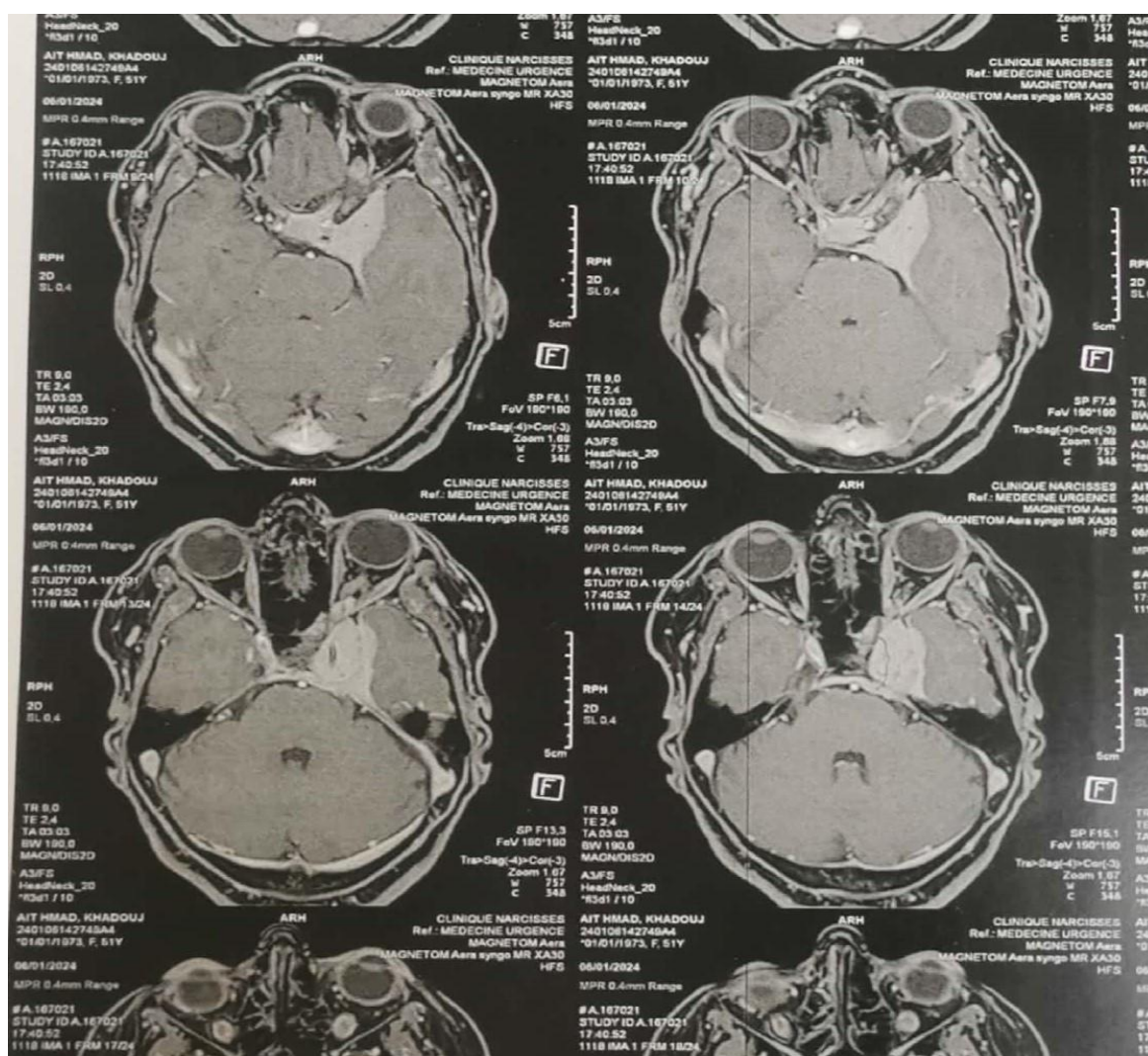


FIGURE 2 ; MRI showing a process occupying the left cavernous sinus in favour of a meningioma of the left cavernous sinus

## II. DISCUSSION

Cavernous sinus meningiomas (CSM) are a diverse group of meningiomas that mainly occur in developing countries. Cavernous sinus (CS) meningiomas are meningiomas located laterally to the sella turcica, developing in and around the CS (1).

These meningiomas mainly occur in the third or fourth decade of life, with a female predominance in a 3:1 (female:male) ratio (1-2).

They account for only about 1% of all intracranial meningiomas (3). CSMs are a specific subset of intracranial meningiomas, mostly being World Health Organization (WHO) grade I lesions with meningothelial histology (4). Their clinical presentation is related to their specific location.

Cavernous sinus meningiomas can present with various symptoms, including ophthalmoplegia (paralysis of the eye muscles), ptosis, hypoesthesia (decreased sensitivity), and exophthalmos (protruding eyes). Diagnosis is based on imaging studies such as CT and MRI scans (5-6).

Treatment of cavernous sinus meningiomas may include stereotactic radiotherapy or radiosurgery for symptomatic lesions. In our case, gamma knife radiosurgery was proposed, but due to the absence of new deficits and the age of the lesions, surveillance was decided upon (7).

Surgical excision of these lesions was once considered technically demanding due to their deep location (1).

Surgical excision of these lesions was a challenging task. Several authors have described the multidimensional microsurgical anatomy and surgical approaches, paving the way for surgical excision of these lesions in this inaccessible site (8-9). Moreover, surgical treatment of CSM has evolved considerably thanks to improvements in neurological imaging (10).

The advent of stereotactic radiosurgery (SRS) has improved the prognosis and management of CSM, making it the treatment of choice (11).

## III. Conclusion

This summary emphasizes the significance of a multidisciplinary approach in managing cases of neurogenic ptosis. It stresses the importance of considering both functional and aesthetic aspects, and making therapeutic choices that are specifically suited to each individual clinical situation.

## References

- [1]. Nanda A, Thakur JD, Sonig A, Missios S. Microsurgical resectability, outcomes, and tumor control in meningiomas occupying the cavernous sinus. *J Neurosurg.* 2016;125(2):378–392. doi:10.3171/2015.3.JNS142494
- [2]. Radhakrishnan K, Mokri B, Parisi JE, O'Fallon WM, Sunku J, Kurland LT. The trends in incidence of primary brain tumors in the population of rochester, minnesota. *Ann Neurol.* 1995;37(1): 67–73. doi:10.1002/ana.410370113
- [3]. Meling T.R., Da Broi M., Scheie D., Helseth E. Meningiomas: skull base versus non-skull base. *Neurosurg. Rev.* 2019;42:163–173. doi: 10.1007/s10143-018-0976-7.
- [4]. Maiuri F., Mariniello G., Guadagno E., Barbato M., Corvino S., Del Basso De Caro M. WHO grade, proliferation index, and progesterone receptor expression are different according to the location of meningioma. *Acta Neurochir.* 2019;161:2553–2561. doi: 10.1007/s00701-019-04084-z
- [5]. Nery Silva M, Saeki N, Hirai S, Yamaura A. Unusual cranial nerve palsy caused by cavernous sinus aneurysms, clinical and anatomical considerations reviewed. *Surg Neurol* 1999;52:143–9.
- [6]. De Jesús O, Colón LE. Extradural intrasphenoidal cavernous sinus schwannoma. Case illustration. *J Neurosurg* 1996;85:359.
- [7]. Colin P, Scavarda D, Delemer B, Nakib I, Caron J, Bazin A, et al. Radiothérapie stéréotaxique fractionnée : résultats dans les adénomes hypophysaires, les neurinomes de l'acoustique et les méningiomes du sinus caverneux. *Cancer Radiother* 1998;2:207–14.
- [8]. Raheja A, Couldwell WT. Cavernous sinus meningioma. *Handb Clin Neurol.* 2020;170:69–85. doi:10.1016/B978-0-12-822198-3.00029-X
- [9]. Mahajan A, Rao VRK, Anantaram G, Polnaya AM, Desai S, Desai P, et al. Clinical-radiologicalpathological correlation of cavernous sinus hemangioma: Incremental value of diffusionweighted imaging. *World J Radiol.* 2017;9(8): 330–338. doi:10.4329/wjr.v9.i8.330
- [10]. Sindou M, Nebbal M, Guclu B. Cavernous sinus meningiomas: Imaging and surgical strategy. *Adv Tech Stand Neurosurg.* 2015;42:103–121. doi:10.1007/978-3-319-09066-5\_6
- [11]. Sekhar LN, Qazi Z. Current approach to meningiomas of the medial sphenoid wing and the cavernous sinus. *Neurol India.* 2018;66(2):335–341. doi:10.4103/0028-3886.227292