

Peripheral Nerve Damage Following Removal of Mandibular Third Molar: Causes and Prevention

Kaushalya Kanagasabapathy, Dr. Brigit Eapen

Abstract: *Third molar extraction is a routinely done procedure by a Dental and Maxillofacial Surgeon. However, chances are that this procedure can bring about damage to one of the branches of the mandibular nerve. An in-depth knowledge on the anatomy of the nerve, correct diagnosis and the usage of proper techniques will enable the clinician to carry out this procedure without leaving post-operative complications. This review article focuses mainly on the causes of peripheral nerve trauma during the procedure and what should or can be done to prevent it.*

I. Introduction

Extraction of the third molar- either erupted or impacted is one of the most common procedures done by a Dental and Maxillofacial Surgeon. A clinician is said to have a profound understanding of this procedure if he or she addresses the complication that might follow this simple surgery. Usually, surgical removal of third molars are followed by pain, swelling, trismus, and general oral impairment during the phase of healing [30]. Apart from the common complaints, a more dangerous negative impact is peripheral nerve paraesthesia caused by an insult to the Inferior Alveolar Nerve (IAN) and/or the Lingual Nerve (LN). The overall percentage of IAN and LN injury following the removal of the mandibular third molar ranges around 0.5% to 5% [33,35]. The percentage of Lingual Nerve injury is around 0.02% to 0.06% which has a lower frequency compared to the IAN injury. [21, 23, 24, 25, 27]

Paraesthesia following peripheral nerve injury is usually temporary and could be permanent in very rare cases. Permanent loss of sensation can occur as a result of failure in complete nerve regeneration. The reported permanent inferior alveolar nerve injury is lesser than 1% [2, 9, 15, 26, 28, 32, and 36]

However, focusing on meticulous details during the procedure and a complete understanding of the anatomy of the nerve can avoid such occurrences. This article comprises of a simplified anatomy of the mandibular nerve, pathophysiology of nerve damage, causes of nerve injury and the approach towards minimizing peripheral nerve injury.

II. The anatomy of lingual and inferior alveolar nerve

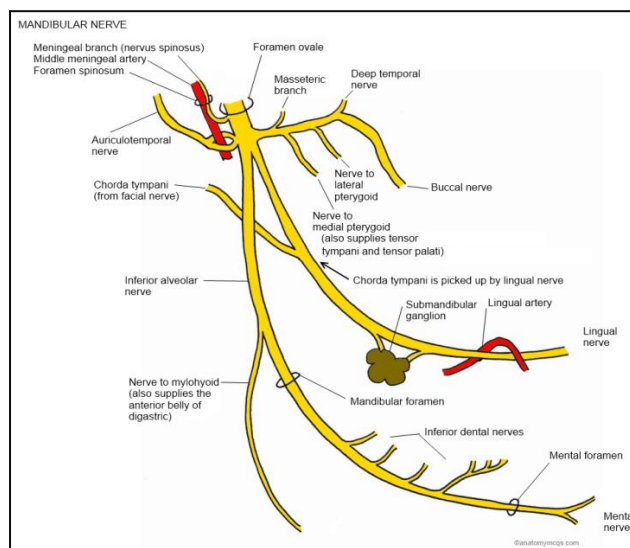
The inferior alveolar nerve (IAN) and Lingual Nerve (LN) are branches of the posterior trunk of the Trigeminal nerve (TN). The trigeminal nerve (TN) is a mixed cranial nerve that consists mostly of sensory neurons. It divides as 3 major branches from the Trigeminal ganglion; the mandibular nerve (MN) being largest of the three divisions. The MN also has an additional motor component the nerve to mylohyoid. [18]

The TN exits the brain from the lateral surface of the pons and then divides into three branches.

The MN, being the main concern in this article, divides into two branches - the lingual branch (which supplies general sensation to the mucosa the floor of the mouth, of the anterior two thirds of the tongue and the lingual surface of the gingival [29] and the inferior alveolar branch which supplies the lower molars, premolars and adjacent parts of the gingiva.

The IAN which descends medial to the lateral pterygoid, passes in between the sternocleidomastoid muscle and the lower border of the mandible to then enter the mandibular foramen. It then runs along the mandibular canal and divides into its terminal branches - the incisive branch and mental branch, between the first and second mandibular premolar.

The LN on the other hand, is the smallest branch of the posterior trunk of the trigeminal nerve. This nerve starts its course from the infra temporal fossa, near the otic ganglion and is separated about 5 to 10mm from the IAN. The lingual nerve proceeds to move and downwards and forwards till it approaches the ramus of the mandible. From here, it travels to lie opposite to the posterior root of the third molar tooth, where it is superficially covered by the gingival mucoperiosteum alone. The IAN winds under the submandibular duct first, before dividing into different branches and entering into the substance of the tongue.



**Figure 1 : Anatomy of the mandibular nerve [39]*

III. Aetiopathogenesis of nerve Damage and neuronal regeneration

Neuronal degeneration depends upon the extent of the injury, the age of the patient, and the location of the injury [16]. Neural trauma which leads to a pathology usually arises from disordered central zones either from hyperactive ganglion cells, or by the formation of a neuroma. [6] Mild injuries can lead to segmental demyelination which may act as ectopic impulse generation sites. [19]

A study by *Kipp et al.* (1980)[15] suggests that all nerve injuries following extraction recovered within 6 months- the period of time which is a commonly set bench mark for the recovery of a nerve injury. Blackburn and Bramley, 1989 [3] showed that there is an incident rate of 11% and a 0.05% persistence rate in a LN injury.

Carmichael and McGowan's(1992) [5]statistics for the IAN showed an incidence of 5.5% at 6 to 24 hours, 3.9% at 7 to 10 days, and 0.9% after 1 year.

Ailing (1986) [1] recorded endured deficits in 13% of LN injuries which had an incidence of 0.06% contrary, to the IAN which had a 0.4% incidence and 3.5% persistence at one year. On the whole, the IAN recovers better than the lingual nerve probably due to the guiding of the mandibular canal.

Neurons, like many other cells in the human body, are capable of regeneration. The healing of nerve tissue is a unique process as its regeneration depends solely upon the cell and not based on tissue repair i.e. cellular regeneration [22]. The Schwann cell and its basal lamina (Bands of Büngner) play a vital role in this process. If a nerve cell survives an injury, it lets out nerve sprouts from the proximal portion of the injured area which could begin as early as 24 hours after the injury. The Schwann cells on the other hand would multiply in the distal segment of the nerve and when they come in contact with the axon sprouts they undergo a series of changes which eventually triggers the myelin production. [20]

1. Causes

#Lingual nerve injury

The LN is much less likely to be injured compared to the IAN. Of the causes, the most understood cause for the LN injury is said to be the enormous variation in its pathway, especially in the third molar area. The nerve is commonly located in the lingual cortex of the mandibular third molar. However, it can be located at any position between the mylohyoid muscle and the gingival crevice. [12] Also, reports have been made regarding the stretching and compression of the nerve while retracting the lingual flap. Some reports suggest that anasthetic injections or even the toxicity of the anasthetic solution could have an ill effect on the nerve, but there were no significant scientific studiesto prove it right.

#Inferior alveolar nerve injury

Rood and NoraldeedShahab39(1990) [19] established three conditions which were found to be in favour with the IAN injury. These were the diversion of the canal, darkening of the root and interruption if the white lines.

The latter two findings were also emphasized by Howe &Poyton[9], as well as Kipp[15] and Rudd[29].

#Direct and indirect injuries

Many studies have been carried out to specify the cause of the LN and IAN injury during the removal of the impacted or erupted third molar. The types of damages imposed onto the nerve can be categorized by direct and indirect injuries.

✦ *Direct injuries:* Direct injuries include those injuries that occur while carrying out the procedure such as trauma to the soft tissue, injuries during the administration of local anesthetic injection, crush injuries and injuries as a result of improper instrumentation

✦ *Indirect injuries:* Indirect injuries are injuries pertaining to physiological means such as root infections and pressure from a hematoma or post-surgical oedema. [4]

IV. Classification of Nerve Injury

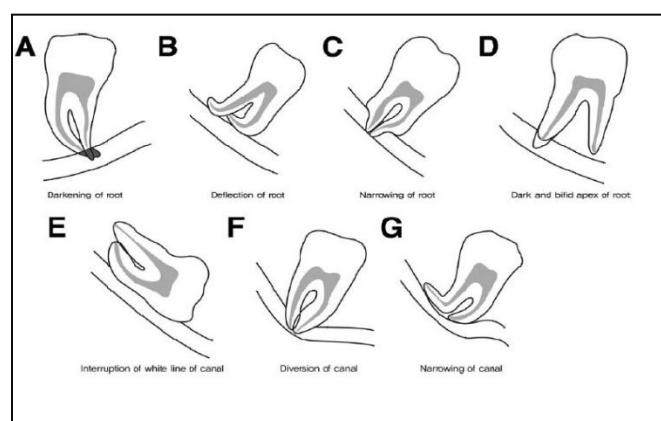
Many accepted classifications have been given by authors over the years in attempt to have a better, more simplified view on this rather vast topic. One of the most commonly used classification and also the most accepted classification is the one proposed by Seddon and Sunderland. Seddon classifies neural trauma into three types - neurapraxia, axonotmesis, and neurotmesis based upon the severity of tissue injury, time for recovery and prognosis for recovery (1943) [20]

Neuropraxia is characterized by paraesthesia (mild loss in sensory) and poor discrimination and stimulus interpretation. This is usually cause by mild trauma to the nerve trunk. Here, there is no axonal degeneration and complete sensory recovery occurs within hours to several days. A slightly more severe form is axonotmesis which is characterized by severe paresthesia. In this form of nerve injury the nerve trunk is intact, however with variable degrees of tissue injury but the afferent fibers undergo degeneration. The sensory recovery is good but not complete and the axonal regeneration usually picks up several months. The most severe form of neural trauma in seddon's classification is neurotmesis whose sensory deficit is characterized by anesthesia (complete loss of sensation). Sensory recovery is nil unless the nerve courses through a canal such as the mandibular canal. Sunderland (1987) classifies nerve injury based upon the degree of tissue injury with a more detailed description compared to the latter author.[20]

V. Risk factors

#Radiographic findings

A close anatomical relationship of the mandibular canal to the tooth is the one factor that cautions the practitioner before he/she decides to extract the tooth. Patients with these radiographic signs are said to be 'high risk' patients. Some other signs also include narrowing or deviation of the canal, loss of the cortical outline of the canal and increased radiolucency over the root area[27]. However, injury to the nerve can occur independent to any of these factors.



**Figure 2 : 7 juxtapositions of the third molar.*[40]*

#Other patient related factors

Some researchers have stated that the patient's age (around 26-30years) could also increase the chances of getting the nerve injury. Apart from that, horizontally impacted teeth [38] and teeth with greater lingual angulation [8] may be of significant importance in increasing the chances of lingual nerve injury as there may be a need to manipulate the lingual flap in the latter case.

VI. Approach towards minimizing nerve injury

Many ideas have been brought forward aiming to reduce nerve injury during the removal of the mandibular third molar. A preoperative radiograph should be taken to assess the relationship of the corresponding nerves and the tooth to be extracted. In high risk patients as mentioned earlier, the anatomical position of the tooth lies very close the nerve. Thus, in such situations, the patient should be informed prior about the condition and the complications the individual mightface if a nerve injury takes place.

Magnetic Resonance Imaging (MRI) has several advantages over the conventional Radiographic and CT imaging. The advantage of MRI is that it has a better soft tissue contrast resolution without having to use ionizing radiation. Hence this method provides sufficient information on the relationship of the IAN and the impacted third molar and can be used in young patients to prevent radiation exposure. [7]

Cone Beam CT (CBCT) appears to be the gold standard for this procedure. Since this device is not readily available in most places, it still remains as a poor source of obtaining the diagnosis for a mandibular third molar extraction.

A study carried out by LucaLandi,DDS,CAGS [17] consisted of a surgical approachtowards reducing the risk of peripheral nerve injury.This was done by removing the mesial portion of the anatomical crown of a fully erupted third molar. The objective of this procedure was to create adequate space for the mesial migration of the third molar so that the extraction of the third molar can be done with minimal invasion to the IAN. Here, a group of 9 patients (age range of 18 years to 43years) were chosen and the procedure was carried out in these patients. In a course of 6 months, (mean174.1days,range92-354days) all the third molars were mesially migrated and removed successfully without causing trauma to the IAN.

Checchi [4] introducedan orthodontic appliance to move the impacted third molar distant to the IAN. This method was proven to be successful. However, the orthodontic appliance which is positioned in a difficult area of the mouth may cause trauma to the neighbouring tissue. Furthermore, this technique is not only time consuming as it required 5months of active therapy and 3 months of stabilization but also not cost effective.

Focusing on the surgical aspect would probably be the best approach towards minimizing nerve injuries.It is a known fact that minor details such as the application of buccal approach and proper flap elevation contribute to a large extent. For instance, the Howarth's, a commonly used periosteal elevatoris placed between the lingual periosteum and the lingual plate of bone carefully without over instrumentation. The primary goal of the flap elevator is to protect the LN during bone removal and tooth elevation. Chisels on the other hand are used for socket saucerization and the tooth delivered distolingually. [10]

VII. Summary

Various methods have been suggested by dentist all over the world intending to reduce the occurrence of peripheral nerve injury while extracting the mandibular third molar. The most preferred and conventional methods are based upon the techniques used to extract the tooth such as using the buccal approach while extracting and focusing on minimal soft tissue damage. Therefore, a strategic approach towards handling this situation requires the operator to have a combination of adequate knowledge on the anatomy of the mandibular nerve, application of apt techniques and the ability to make evidence based diagnosis. More clinical studies should be carried out to discover the best methods in preventing IAN and LN injuries.

References

- [1] Ailing CC (1986). Dyesthesia of the lingual and inferior alveolar nerves following third molar surgery. *I Oral Maxillofac Surg* 44:454-457
- [2] AzazB, ShteyerA, PiamentaM. Radiographic and clinical manifestations of the impacted mandibular thirdmolar.*IntJOralSurg*1976;5:158.
- [3] Blackburn CW, Bramley PA (1989). Lingual nerve damage associated with the removal of lower third molars. *Br DentJ* 167:103-107
- [4] Cade TA .Paresthesia of the inferior alveolar nerve following the extraction of the mandibular third molars:a literature review of its causes, treatment, and prognosis. *MilMed* 1992;157:389-92
- [5] Carmichael FA, McGowan DA (1992). Incidence of nerve damage following third molar removal. *Br J Oral MaxillofacSurg* 30:78-82
- [6] Devor M, Wall PP (1990). Cross excitation in dorsal root ganglia of nerve injured and intact rats. *Neurophysiology* 64:1733-1746
- [7] FFerretti*, M Malventi and R Malasoma Dental magnetic resonance imaging: study of impacted mandibular third molars Radiologic Division, Dental Service, Hospital of Livorno, Italy
- [8] Fielding AF, Rachiele DP, Frazier G. Lingual nerve paresthesia following third molar surgery. Aretrospective clinical study. *Oral Surg Oral Med Oral Pathol Oral RadiolEndod* 1997;84:345-8
- [9] HoweGL, PoytonHG. Prevention of damage to the inferior dental nerve during extraction of mandibular third molars.*BrDentJ* 1980;108:356.
- [10] Inferior Alveolar Nerve Damage During Removal of Mandibular Third Molars(2004)By Howard. Holmes, DDS, Dip OMFS, FICD; David Lam, DDS; Taylor MC Quire, DDS and Peter Giolious DDS
- [11] Khan MM, Darwish HH, Zaher WA. 2009. Perforation of the inferior alveolar nerve by the maxillary artery: An anatomical study. *British Journal of Oral and Maxillofacial Surgery* (in Press
- [12] KiesselbachJE, ChamberlainJG. Clinical and anatomical observations on the relationship of the lingual nerve to the mandibular third molar region.*JOral MaxillofacSurg*1989;42:565-7

- [13] Kim HJ, Kwak HH, Hu KS, Park HD, Kang HC, Jung HS, Koh KS. 2003. Topographic anatomy of the mandibular nerve branches distributed on the two heads of the lateral pterygoid. *Int J. Oral Maxillofac. Surg* 32: 408-413.
- [14] Kim SY, Hu KS, Chung IH, Lee EW, Kim HJ. 2004. Topographic anatomy of the lingual nerve and variations in communication pattern of the mandibular nerve branches. *SurgRadiolAnat* 26: 128-135
- [15] Kipp DP, GoldsteinBH, WeissWW. Dysesthesia after mandibular third molar surgery: a retrospective study and analysis of 1977 surgical procedures. *J Am Dent Assoc* 1980;100:185.
- [16] Lieberman AR (1974). Some factors affecting retrograde neuronal responses to axonal lesions. In: - Essays on the nervous system. Bellars R, Gray EG, editors. Oxford, England: Clarendon Press, p. 71
- [17] LucaLandi(2010). A Novel Surgical Approach to Impacted Mandibular Third Molars to Reduce the Risk of Paresthesia: A Case Series. 2010 American Association of Oral and Maxillofacial Surgeons 0278-2391, p.1-5
- [18] M. Piagkou1, T. Demesticha2, G. Piagkos3, Chrysanthou Ioannis4, P. Skandalakis5 and E.O. Johnson6. The Mandibular Nerve: The Anatomy of Nerve Injury and Entrapment.
- [19] Nordin M, Nyström B, Wallin U, Hagbarth KE (1984). Ectopic sensory discharges and paresthesia in patients with disorders of peripheral nerves dorsal roots and dorsal columns. *Pain* 20:231-245
- [20] Pelligrino RG, Spencer PS (1985). Schwann cell mitosis in response to regenerating peripheral axons in vivo. *Brain Res* 341:16-25
- [21] Pichler JW, Beirne OR. Lingual flap retraction and prevention of lingual nerve damage associated with third molar surgery: a systematic review of the literature. *Oral Surg Oral Med Oral Pathol Oral Radiol Endod* 2001;91:395-401.
- [22] R. Bruce Donolf (1995). NERVE REGENERATION: BASIC AND APPLIED ASPECTS. *Crit Rev Oral Biol Ued* 6(1):18-24
- [23] Renton T, McGurk M. Evaluation of factors predictive of lingual nerve injury in third molar surgery. *Br J Oral Maxillofac Surg* 2001;39:423-8.
- [24] Rezai RF, Bayley NC, Austin K. Lingual nerve damage : causative factors and management. *Quintessence International* 1988;19:295-8.
- [25] Robinson PP, Smith KG. Lingual nerve damage during lower third molar removal: a comparison of two surgical methods. *Br Dent J* 1996;180:456-61.
- [26] Rood JP, Shehab BA. The radiological prediction of inferior alveolar nerve injury during third molar surgery. *Br J Oral Maxillofac Surg* 1990;26:26.
- [27] Rood JP. Lingual split technique: damage to inferior alveolar and lingual nerves during removal of impacted mandibular third molars. *Br Dent J* 1983;154: 402-3
- [28] Rud J. Third molar surgery: relationship of root to mandibular canal and injuries to inferior dental nerve. *Tandlaegetidning* 1983;87:619.
- [29] Rusu MC, Nimigean V, Podoleanu L, Ivascu RV, Niculescu MC. 2008. Details of the intralingual topography and morphology of the lingual nerve. *Int J Oral Maxillofac Surg* 37:835-839
- [30] S.M.Susarla et al. / *Oral Maxillofacial Surg Clin N Am* 15(2003)177-186
- [31] Seddon HJ. Three types of nerve injury. *Brain* 1943; 66:237-88
- [32] Smith AC, Barry SE, Chieng AY, et al. Inferior alveolar nerve damage following removal of mandibular third molar teeth: a prospective study using panoramic radiography. *Aust Dent* 1997;42:149.
- [33] Swanson AE. Incidence of inferior alveolar nerve injury in mandibular third molar surgery. *J Can Dent Assoc* 1991;57:327-8.
- [34] Third molar surgery and associated complications S.M.Susarla et al. / *Oral Maxillofacial Surg Clin N Am* 15(2003)177-186.
- [35] Valmaseda-Castellon E, Berini-Ayres L, Gay-Escoda C. Inferior alveolar nerve damage after lower third molar surgical extraction: a prospective study of 1117 surgical extractions. *Oral Surg Oral Med Oral Pathol Oral Radiol Endod* 2001;92:377-83.
- [36] Van Gool AV, Ten Bosch JJ, Boering G. Clinical consequences of complaints and complications after removal of the mandibular third molar. *Int J Oral Surg* 1977;6:29
- [37]. Waseem J, Tahwinder U, Priya S, Farai N, et al. Risk factors associated with injury to the inferior alveolar and lingual nerves following third molar surgery revisited. *Oral Surg Oral Med Oral Pathol Oral Radiol Endod* 2010; 109:335345
- [38] Zuniga JR, Meyer RA, Gregg JM, et al. The accuracy of clinical neurosensory testing for nerve injury diagnosis. *J Oral Maxillofac Surg* 1998;56:2-8

Web references

- [39] www.cambridgequestions.co.uk. The Anatomy of Mandibular Nerve
- [40] www.intechopen.com. The Mandibular Nerve: The Anatomy of Nerve Injury and Entrapment. www.intechopen.com