

Small Cell Osteosarcoma of Distal Femur – Reporting a Rare Variant.

Dr. Arun Kumar Pandian, Dr Giriraj Harshvardhan, Dr. P. Ramesh Vyravan ,
Dr.Ganesan G.Ram, Dr. P. V. Vijayaraghavan

Resident, Department of Orthopaedics, Sri Ramachandra Medical College, Chennai.

Associate Professor, Department of Orthopaedics, Sri Ramachandra Medical College, Chennai.

Associate Professor, Department of Orthopaedics, Sri Ramachandra Medical College, Chennai.

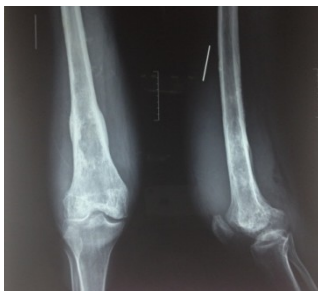Assistant Professor, Department of Orthopaedics, Sri Ramachandra Medical College, Chennai

Professor, Department of Orthopaedics, Sri Ramachandra Medical College, Chennai.

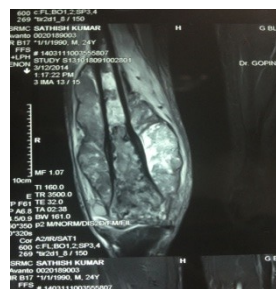I. Introduction

Small cell osteosarcoma is a variant of osteosarcoma composed of small cells and varying amount of osteoid. It was first described by Sim et al⁴ in 1979. It is a very rare bone tumor and represents 1% to 1.5% of all osteosarcomas³. Its clinical features are similar to conventional osteosarcoma. It occurs in all ages but most of the cases occur in a slightly older age group as compared to conventional forms³. The majority of tumors occur in metaphysis¹, with purely lytic lesion most common site is distal femur^{1,2}.

23 year old gentleman had pain and swelling in the right distal thigh for three years. Pain increased in intensity and swelling progressed in size. Presented to us with pain and swelling. On examination patient had diffuse swelling extending from knee to mid-thigh, globular in shape, dilated veins seen. Right knee range of movements: FFD 10degrees, flexion 10-45 degrees with foot drop. Hemoglobin was low; Serum calcium, alkaline phosphatase and phosphorus were within normal limits.



X-RAY (Fig1.1) shows lytic lesion in the distal metaphysis

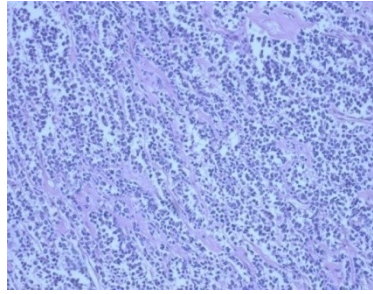


MRI (Fig1.2) shows permeative lytic intramedullary lesion extending to the joint

To rule out secondaries bone scan was done showed increased vascularity in the right distal femur with no other skeletal metastasis. CT thorax done no lesions. Core needle biopsy was done which showed small cells with scanty neoplasm and hyper chromatic nucleus suggestive of high grade small round blue cell tumor.

We discussed with surgical oncologist and planned for amputation in view aggressive tumor, deficient soft tissue cover and chances of recurrence. Transfemoral amputation was planned. Using MRI we measured the lesion which was 22 cm from the greater trochanter. He underwent neoadjuvant chemotherapy as per medical oncologist advice. Three cycles of chemotherapy Inj. Ifosphamide 7gm, Inj. Adriamycin 70 mg, Inj. Cisplatin 75 mg, Inj. Mesna 7 amp (0, 4, 8 hrs x 2 days). He underwent above knee amputation and sent for histopathology and confirmed the diagnosis using immunohistochemistry (IHC).

IHC ruled out all forms of small round blue cell tumors. CD99, a specific maker for Ewing's sarcoma was negative. Acid Schiff was negative which is usually positive in Ewing's. CD 45 marker was negative which is positive in lymphoma. The tumor cells were negative for vimentin, osteocalcin, osteonectin, smooth muscle actins, and CD-56. It is negative for all the conventional lymphoid markers. Microscopically it was blue round cell tumor that is pleomorphic in nature with abundant mitotic osteoid –pink amphorus material arranged in strands.



Histopathological specimen showing round blue cell tumor pleomorphic in nature with abundant osteoids.

II. Result

Bone scan was done to rule out metastases. CT Thorax was done chest secondaries ruled out. Patient was given neo adjuvant chemotherapy. Then above knee amputation was done. Biopsy reported as Small cell osteosarcoma with 90% tumor necrosis. Radiotherapy was given after he was diagnosed to have brain metastasis. But in spite this patient died.

III. Discussion

Ayala et al¹ in their publication have stated that the most common site of occurrence is distal femur. Age distribution is still a controversy. Sim et al⁴ have said that incidence is common in age group more than thirty years but Ayala et al have told that incidence is more common in age group of second decade of life. Our case is at age group of twenty three years. Also all blue round cell tumors can have osteoid presence with abundant mitosis^{2,3,4}. Our case also has osteoid presence.

The presentation can be mixed-lytic and blastic³. Our case is also having mixed presentations in X-rays. Matrix can be present both in and outside^{2,3} the bones. This is a distinctive feature of small cell osteosarcoma². Mineralized matrix can be present^{2,3}. Our case has a mineralized matrix as seen in the MRI. Both Ewing's sarcoma and small cell osteosarcoma can be without spindle cells as in our case hence differentiation between these two which is usually difficult can be made out by the presence mineralized matrix².

Immunohistochemistry plays a vital role in differentiating among this group³ of round blue cell tumors. In our case the tumor cells were negative for vimentin, osteocalcin, osteonectin, smooth muscle actins, and CD-56. In our case pleomorphism with abundant mitosis was seen in our case which also makes a diagnosis of small cell osteosarcoma.

In our study we did a bone scan six months before surgery which showed no metastases. Two months after surgery patient came to us with seizures. CT-Brain done which showed brain metastasis. Mortality is very high in spite of aggressive treatment including chemotherapy². The range of survival rate is 5 months to ten years².

IV. Conclusion

Small cell osteosarcoma is rare variant high grade aggressive malignant tumor. It is very important to differentiate this tumor from other tumors of the round blue cell tumors. For this immunohistochemistry helps a lot in arriving at the diagnosis. Metastases should be ruled out as early as possible.

Bibliography

- [1]. Small Cell Osteosarcoma A Clinicopathologic Study of 27 Cases ALBERTO G. AYALA, MD et al.
- [2]. Small cell osteosarcoma of bone review article Hisayanakajima et al CANCER June 1(1977) volume 79
- [3]. Small cell tumors of bone Shayong li et al AdvAnatPathol Volume 17 number 1 Jan (2010)
- [4]. Sim FH, Unni KK, Beabout JW, Dahlin DC. Osteosarcoma with small cells simulating Ewing's tumor. J Bone Joint Surg(Am) 1979;61A:207-215