

Ischemic monomelic neuropathy (IMN) -A Case Report

Om Prakash Lekhra, Amit Maheshwari, Yajuvendra Rathore
Department of Neurology, SAIMS Medical College & PG Institute. Indore

Abstract: Ischemic monogenic neuropathy (IMN) reported mostly in diabetics with peripheral neuropathy or peripheral vascular disease is a rare condition. Usually seen after AV fistula for haemodialysis, it is a preventable entity. We describe a rare case of ischemic monomelic neuropathy (IMN) in a young girl with involvement of all three nerves developing after preventive tourniquet application in a presumed snake bite.

Key words: Ischemic, neuropathy, snake bite, tourniquet

I. Introduction

Ischemic monomelic neuropathy (IMN) is an infrequently recognized type of neuropathy, produced after acute arterial occlusion or reduced blood flow to an extremity^[1]. In the upper limb, it usually occurs after vascular access for arteriovenous fistula for haemodialysis^[2,3]. IMN has been reported largely in diabetics with peripheral neuropathy, peripheral vascular disease and brachial artery grafts^[2]. We report a case of IMN with clinical and electrophysiological signs of sensorimotor dysfunction of multiple nerves of right upper limb following tourniquet application for suspected snake bite.

II. Case Report

A 19 year old right handed girl from a remote hilly area of Nepal, gave a history of doubtful "snake bite" over her ring finger of right hand while asleep. The type of snake could not be ascertained by her or attendants. There were no neurological or haematological features suggestive of envenomation. She was applied a tight tourniquet using her clothing over her mid-forearm, to inhibit spread of the venom, as per her local practices. As the nearest medical was far off after 24 hrs she developed discoloration & weakness in the form of inability to move her fingers and make fist & tourniquet was removed. This weakness was non-progressive but affected her activities of daily living (ADL). There was no past history of peripheral vascular disease. After five months she was admitted with us.

On examination, patient had healed abrasions on right forearm & hand. The involved hand was cold. All peripheral pulses including both radial and brachial were regular and equal. BP was 120/70 mm Hg in both arms. There was hyperpigmentation and discoloration over right forearm below elbow up to distal wrist. There was grade 1/5 power in all median, ulnar and radial nerve innervated forearm and hand muscles. Mild sensory deficit over autonomous zone of radial and ulnar nerve was noted. Her DTRs were normal. There was atrophy in thenar, hypothenar & extensor muscles of forearm with contracture of wrist, thumb & finger flexors (Fig 1a,b).

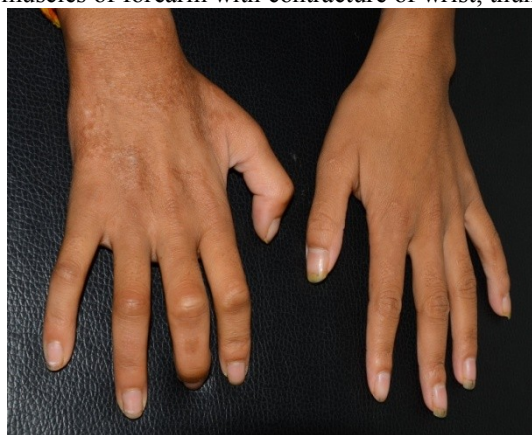

Fig 1a: Wasting of the extensor muscles of the right hand

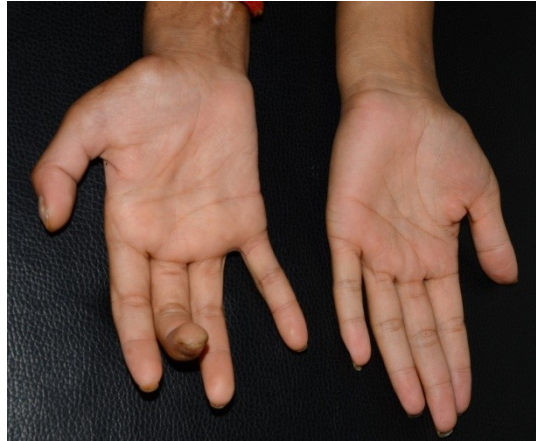


Fig1b.: Wasting of the thenar and hypothenar area of the right hand

Routine investigations along with vasculitis and coagulation profile were normal. Chest X ray was unremarkable. Right upper limb arterial & venous doppler were normal. Electrophysiological study revealed absent compound motor action potential (CMAP) of right median and ulnar nerves. Right radial nerve show normal latency with grossly diminished amplitude (Fig2a). Sensory nerve action potential of right median, right ulnar and right radial nerves are not recordable. These findings are suggestive of predominantly sensorimotor axonal neuropathy of the right upper limb. The other limbs showed normal conduction studies. Thus a diagnosis of ischemic monomelic neuropathy was considered. Daily rehabilitation and physiotherapy sessions were started in the form of sensory integration training, joint compression, proprioceptive inputs in right upper limb and stretching of wrist flexors, thumb and fingers. Electrical muscle stimulation was also done with intermittent galvanic mode with improvement in the form of lesser stimulation required progressively. After a month of this treatment power improved to grade 4+/5 in both flexors & extensors such that she was able to write & lift a weight of 750 grams with her hand & able to perform her ADLs. Repeat nerve conduction study after a month revealed improved conduction in radial nerve and emergence of CMAP amplitude (Fig2b).

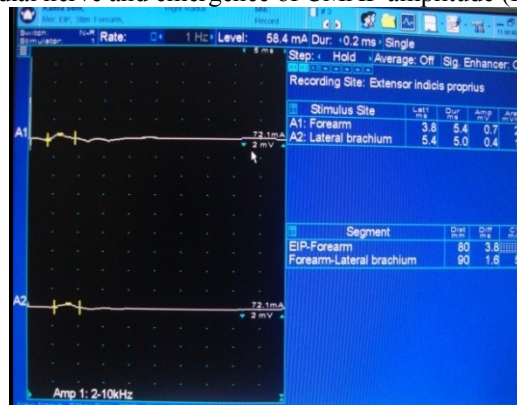


Fig 2a: Radial motor conduction study revealing reduced amplitude of CMAP (0.7mV) at time of admission.

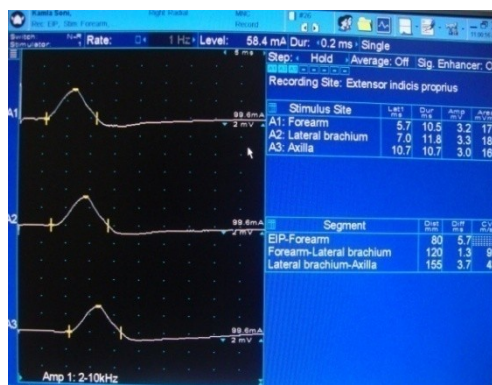


Fig 2b: Repeat radial nerve conduction study revealed improved amplitude of CMAP(3.2mV) after one month

III. Discussion

Ischemic monomelic neuropathy (IMN) involving median or ulnar nerves is a rare condition that requires an early diagnosis and treatment. It is characterized by pain, weakness, and paralysis of the muscles of the forearm and hand, minutes to hours after placement of an antecubital AV access. It usually involves axonal nerves leading to axonal neuropathy. Reversible electrophysiological changes has been reported in the course of IMN. The muscle, skin, bone, and other tissues are usually spared but exceptions can be there. IMN can also occur after surgical procedures (for example, vascular surgery involving the thoracoabdominal aorta and its caudal arterial channels), or because of the development of arterial emboli or thrombi^[4]. IMN in the arm have also described in any problem that causes a hypercoagulable state, as well as thoracic outlet obstruction (with angiographic confirmation), trauma or laceration of the brachial artery, intra-arterial injection, and cellulitis^[4]. There is controversy in the literature over the terms vascular steal syndrome and IMN. Moreover overlap between the these two terminologies has been also well described^[5]. But the electrophysiological evidence of neuropathy in IMN is well established and this factor alone differentiates it from vascular steal syndrome. The normal hemodynamic flow in the doppler studies also favor the diagnosis of IMN vis-a-vis vascular steal syndrome.

Tourniquet was tightly tied for a prolonged period in our case resulting in compression of underlying vessels and nerves^[6]. The wasting noted in the area below the tourniquet indicated axonal damage to median, ulnar and the radial nerves which correlated with the electrophysiological findings as described above^[7]. The application of tourniquet for suspicious snake bite, wasting of the muscles and the electrophysiological evidence of neuronal involvement favor the diagnosis of IMN. The involvement of all three nerves (i.e. median, ulnar and radial) in the upper limb in IMN is not so common.^[8] Long duration tourniquet or tight immobilization bandages cause ischemia leading to tissue hypoxia, hyperkalemia and acidosis. High energy phosphate depletion results in loss of membrane potential of the ischemic myocytes due to failure of the sodium pump with leakage of potassium into the interstitium^[9]. This leads to cellular necrosis and wasting as evident in our case. Practice of tying tough clothing as a tourniquet in presumed snakebite is common in Nepal, India & nearby Asian countries^[10]. Firstly it should be discouraged and secondly even when it is applied it, effort should be on so that patient receives the medical care within 2-3 hours. We wish to stress upon the fact that one should be aware of the potential complications of tight tourniquet and need to be alert in early recognition of cases of IMN by electrophysiology so that irreversible damage could be avoided by rehabilitation and physiotherapy.

References

- [1]. Wilbourn AJ, Furlan AJ, Hulley W, Ruschhaupt W. Ischemic monomelic neuropathy. *Neurology* 1983;33:447-451.
- [2]. Natasha M. Rogers and Paul D. Lawton. Ischaemic monomelic neuropathy in a non-diabetic patient following creation of an upper limb arteriovenous fistula. *Nephrol Dial Transplant*. 2006; 22: 933-935
- [3]. Muhammad Awais, Johann Nicholas, Abdul Al-Saleh and Jules Dyer Ischaemic monomelic neuropathy (IMN) following vascular access surgery for haemodialysis: an under-recognized complication in non-diabetics. *Clin Kidney J*. 2012; 5: 140-142
- [4]. Andary, M. T. (2013, Aug 14). Ischemic Monomelic Neuropathy. Retrieved June 14, 2014, Medscape: <http://emedicine.medscape.com/article/315915-overview>
- [5]. Payman Zamani, James Kaufman, Scott Kinlay. Ischemic steal syndrome following arm arteriovenous fistula for hemodialysis. *Vascular Medicine* 2009; 14: 371-376
- [6]. George Watt, Laurena Padre, Ma. Linda Tuazon, R. David G. Theakston, Larry W. Laughlin. Tourniquet application after cobra bite: Delay in the onset of neurotoxicity and the dangers of sudden release. *Am J Trop Med Hyg*. 1988;38:618-622
- [7]. Levin KH. AAEE case report # 19 ischemic monomelic neuropathy. *Muscle-nerve* 1989;12:791-5
- [8]. Ji Soo Han, Moo Yong Park, Soo Jeong Choi, Jin Kuk Kim, Seung Duk Hwang, Keun Her, and Tae Eun Kim. Ischemic monomelic neuropathy: a rare complication after vascular access formation. *Korean J Intern Med* 2013;28:251-253
- [9]. Cormier JM, Legrain M. Hyperkalemia, very severe complication of acute ischaemia syndromes of the limbs. *J Chronic Dis* 1962 ; 83 : 473-483
- [10]. Chapter in book: Guidelines For the Clinical Management Of Snake Bites In South- East Asia Region Written and edited by David A Warrell published by WHO, 2000