

## Incomplete Oblique Fissure, Absence of Horizontal Fissure: A Case Report

J.Sumalatha<sup>1</sup>, T. Sobha devi<sup>2</sup>

<sup>1</sup>Post graduate, Dept. of Anatomy, S.V. Medical college, Tirupati, A.P, NTRUHS

<sup>2</sup>Assistant Professor, Dept. of Anatomy, S.V. Medical college, Tirupati, A.P, NTRUHS

---

**Abstract:** The right Lung classically has one oblique fissure and one horizontal fissure and Three Lobes namely Upper, Lower, and middle Lobes. Variations in the lung fissures and lobes have been described by many authors which have got their Surgical and Radiological importance. During Routine dissection in the Department of Anatomy, S.V. Medical College, Tirupati, we encountered an Incomplete oblique Fissure, Absence of Horizontal fissure in the Right Lung of an Adult male Cadaver. Anatomical Knowledge of the variations of Fissures of Lung are important for C.T. Surgeons performing Lobectomies, and Radiologists interpreting X-Rays.

**Keywords:** Right Lung, Oblique Fissure, Horizontal Fissure, Incomplete lobes

---

### I. Introduction

Right lung is broader and heavier than the left lung. Two fissures oblique and horizontal, divide it into three lobes namely, upper, middle and lower. The oblique fissure separates the lower lobe from the remaining two lobes. It runs obliquely and crosses the inferior border of the lung about 7.5 cm behind its anterior end. The horizontal fissure separates the upper and middle lobe. It begins from the oblique fissure, runs horizontally and cuts the anterior border at inner end of fourth costal cartilage. The longer and lighter left lung is divided into a superior and an inferior lobe by an oblique fissure which extends from costal to medial surfaces of the lung both above and below the hilum<sup>3</sup>

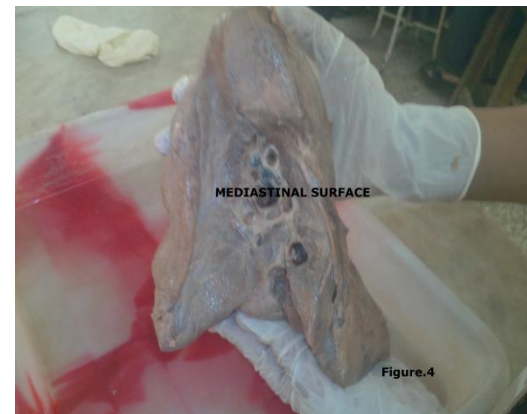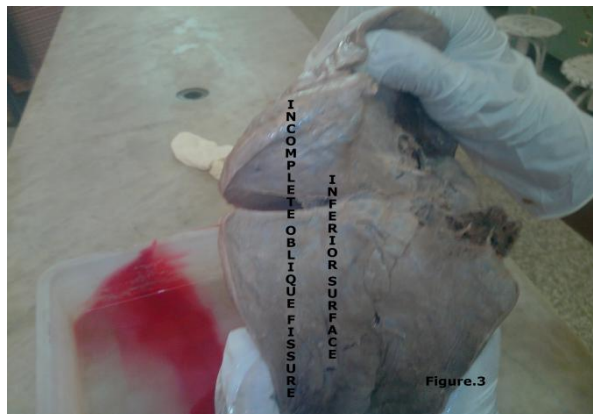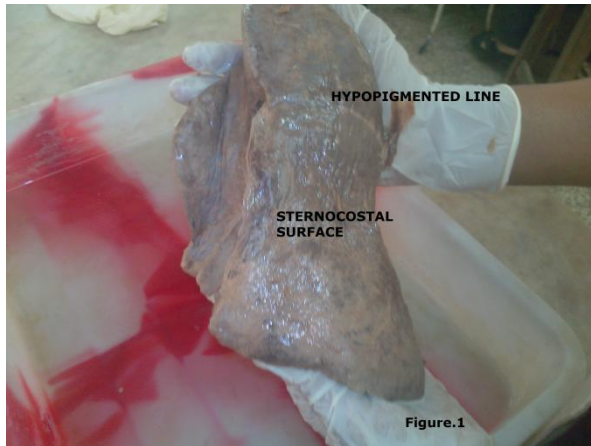
The fissures facilitate the movement of the lobes in relation to one another, which accommodates greater distention and movement of the lobes during respiration. The fissures may be complete, incomplete or absent. In case of complete fissure the lung lobes are held together only at the hilum by the bronchi and the pulmonary vessels. Parenchymal fusion of varied extent along the floor is found in case of incomplete fissure<sup>4</sup>. Knowledge of the anatomy and variations of the major fissures are essential for recognizing their variable imaging appearances as well as related abnormalities. The cardiothoracic surgeons performing segmental lung resections and the radiologists must have a detailed knowledge of variations of classical and accessory fissures regarding their length, depth, positions etc to have uncomplicated preoperative and postoperative events and proper radiological interpretations respectively.

### II. Materials And Method

Anomaly was observed during Routine dissection in the Department of Anatomy, S.V. Medical College, Tirupati in an Adult male cadaver. Both lungs were observed, Photographs were taken.

### III. Observations

Right Lung showed an incomplete Oblique Fissure, Absence of Horizontal Fissure. Left Lung is normal. Incomplete oblique fissure started from the Apex of the Right Lung at about 12.5 cms at the Level of Mid-Axillary line. It runs Antero inferiorly over the Sternocostal surface and cuts the Inferior border of lung at about 19 cms from the Apex or 6.5 cms from the anterior border. It runs Along the Inferior surface for 5.5 cms and ends blindly at the junction of Mediastinal and Inferior surface at about 4.5 cms from the Anteroinferior aspect of Hilum. Depth of the fissure is about 2 cms proximally, 2.5 cms at the terminal part, 3.5 cms in the deepest part. No other Accessory fissures noted. Right lung is incompletely divided into 2 lobes. Tertiary Bronchi are 10 in number. Relations of tertiary bronchi with pulmonary artery branches, pulmonary vein tributaries are normal. Parenchymal fusion of oblique fissure is represented by an Hypopigmented Line. Horizontal Fissure is completely absent. Figures 1,2,3,4, showed the observations



#### IV. Discussion

The fissures facilitate the movement of the lobes in relation to one another, which accommodates greater distention and movement of the lobes during respiration. The fissures may be complete, incomplete or absent. In case of complete fissure the lung lobes are held together only at the hilum by the bronchi and the pulmonary vessels. Parenchymal fusion of varied extent along the floor is found in case of incomplete fissure. Finding accessory fissures in lung specimens is not uncommon, but appreciating them on radiographs and CT scans is difficult and hence they are either not appreciated as distinct entities or are completely misinterpreted. In addition to those fissures lung might also have accessory fissures, usually indicating junction between bronchopulmonary segments. As per Godwin<sup>3</sup>, they are superior accessory fissure, inferior accessory fissure or left minor fissure. No oblique fissure could be detected in 8% lungs of left and 11.54% of right side. Horizontal fissure was completely absent in 34.6%. Various degree of parenchymal fusion was more common on the right side. None of the oblique fissures had uniform depth Sumita Dutta<sup>11</sup> Fifty pairs of lungs were used for the study, Seven right lungs showed absence of horizontal fissure while one specimen showed absent oblique fissure, there is a wide range of difference in occurrence of major, minor and accessory fissures between and among different populations. Knowledge of such variations might explain bizarre presentation of certain clinical cases pertaining to lung pathologies Ajay Ratnakar rao Nene<sup>1</sup>

Study was conducted on 48 lung specimens by Suja Mary Jacob<sup>5</sup>, among which 30 are right and 18 left lungs. In right lungs, the horizontal fissure was absent in 2 lungs (6.6%) and incomplete horizontal fissure was found in 25 lungs (83.4%). Oblique fissure was incomplete in 15 lungs (50%). One lung showed absence of oblique fissure (3.4%). An accessory fissure was observed in 4 lungs (13.3%). On the basis of CT scans, Otsuji *et al.* (1993)<sup>9</sup> made an analysis of both lungs in 154 patients, including seven cadavers, and came to the conclusion that the frequency of the incomplete inter-lobe fissure was high in right-sided lungs (83.1%), when compared to the left lungs (50%)

Craig and Walker (1997)<sup>2</sup> have proposed a fissural classification based on both the degree of completeness of the fissures and the location of the pulmonary artery at the base of the oblique fissure. Four stages have been described. Grade I – complete fissure with entirely separate lobes; Grade II – complete visceral cleft but parenchymal fusion at the base of the fissure; Grade III – visceral cleft evident for a part of the fissure; and Grade IV – complete fusion of lobes with no evident fissural line, Present case falls under Grade III

S. Meenakshi et al<sup>10</sup> studied on 30 pairs of lungs, Five right-sided lungs showed absence of horizontal fissure, 19 showed incomplete horizontal fissure. Eleven right-sided and 14 left-sided lungs showed incomplete oblique fissure and two right-sided lungs showed both absence of horizontal fissure and an incomplete oblique fissure. Accessory fissure was seen in three left-sided and one right-sided lungs

N. Bhimai Devi et al<sup>8</sup> studied on 22 cadavers and observed Two left lungs showed absence of fissures; in eight left lungs incomplete oblique fissure was observed. In four right lungs of transverse fissure was incomplete and in two right lungs incomplete oblique and transverse fissures were found. In two cadavers accessory lobes were present, one on right side and one on left side

M.A.Eroje et al<sup>7</sup> found 2 cases both belongs to right lung , 1<sup>st</sup> one has a horizontal and incomplete oblique fissure , 2<sup>nd</sup> one has a complete oblique fissure with complete absence of horizontal fissure which differs with present case.

Incomplete development of the lung leads to incomplete formation of the fissures or causes their absence. In both the cases parenchymal fusion is seen. When part of the fissure is absent, it is always toward the mediastinal side of the fissure. Incomplete fissure may lead to the spread of disease and collateral air drift (Hayashi *et al.*, 2001)<sup>4</sup>. It may alter the usual patterns of collapse seen in patients with endobronchial lesions and may also give rise to atypical type of pleural effusion (Meenakshi *et al.*)<sup>10</sup>. Familiarity with the appearance and implications of incomplete fissure is important for planning of lobar resection because there is a higher prevalence of air leak in lobar fusion (Hayashi *et al.*)<sup>4</sup>.

## V. Summary And Conclusion

Pneumonia in a particular lobe is contained within the confines of the lobe by complete fissures. In patients with incomplete fissures ,pneumonia may spread to adjacent lobes through the parenchymal continuation. Odd lobar involvement with carcinoma of the lung may be explained on a similar basis. A variety of genetic and environmental factors might affect development of these fissures. Knowledge of such variations might explain bizarre presentation of certain clinical cases pertaining to lung pathologies. Anatomical knowledge of fissures and lobes are important for CT surgeons, radiologists for interpreting x-rays, CT scans and MRI

## References

- [1]. Ajay Ratnakarrao Nene, Krishna Swami Gajendra, Manchiraju Venkata Ramananda Sarma Lung lobes and fissures: a morphological Study October 24, 2011 doi:10.2399/ana.10.005 International journal of Experimental and Clinical Anatomy
- [2]. CRAIG SR, WALKER WS (1997) A proposed anatomical classification of the pulmonary fissures. J R Coll Surg Edin, 42: 233-234.
- [3]. Godwin JD, Tarver RD. Accessory fissures of the lung. AJR Am J Roentgenol. 1985;144:39-47.
- [4]. Hayashi K, Aziz A, Ashizawa K, Hayashi H, Nagaoki K, Otsuji H. Radiographic and CT appearances of the major fissures. Radiographics. 2001;21(4):861-874.
- [5]. JACOB, S. M. & PILLAY, M. Variations in the inter-lobar fissures of lungs obtained from cadavers of South Indian origin. Int. J. Morphol., 31(2):497-499, 2013.
- [6]. Lydia S. Quadros, Ramesh Palanichamy and Antony S. D'souza Variations in the lobes and fissures of lungs – a study in South Indian lung specimens Eur. J. Anat. 18 (1): 16-20 (2014)
- [7]. M.A.Eroje and F.M.Onyije; Lobar Variations of Right Lung as Seen in a Nigerian Cadaver: A Case Report; Asian Journal of Biological Sciences 4 (2):196-200, 2011
- [8]. N. Bhimai Devi \*, B. Narasinga Rao \*\*, V. Sunitha \*\*\* Morphological variations of lung- A cadaveric study in north coastal Andhra Pradesh Int J Biol Med Res. 2011; 2(4): 1149 – 1152
- [9]. Otsuji, H.; Uchida, H.; Maeda, M.; Iwasaki, S.; Yoshiya, K.; Hatakeyama, M.; et al. Incomplete interlobar fissures: bronchovascular analysis with CT. Radiology, 187(2):541-6, 1993.
- [10]. S. Meenakshi, K.Y. Manjunath and V. Balasubramanyam Morphological Variations of the Lung Fissures and Lobes, Indian J Chest Dis Allied Sci 2004; 46 : 179-182
- [11]. Sumita Dutta<sup>1</sup>, Lopamudra Mandal<sup>1</sup>, Sanjay Kumar Mandal<sup>2</sup>, Jayanta Biswas<sup>3</sup>, Ansuman Ray<sup>1</sup>, Manimay Bandopadhyay<sup>4</sup> NATURAL FISSURES OF LUNG- ANATOMICAL BASIS OF SURGICAL TECHNIQUES AND IMAGING NATIONAL JOURNAL OF MEDICAL RESEARCH print ISSN: 2249 4995 | eISSN: 2277 8810