

Multidisciplinary Approach in Refining an Esthetic Smile

Soumya Abraham¹ Bds. Dr. Julie Toby Thomas²,

¹Saveetha Dental College, Saveetha University, India

²Department of Periodontics, Saveetha Dental College, Saveetha University, India

Abstract: A gummy smile is when there is too much exposure of the upper gingival during smiling. The appearance of the gingival contour depends on the underlying bony architecture. This is further influenced by factors like tooth position, the type of periodontium, the tooth form, aberrant muscle attachments and skeletal relationship. This review article focuses on the various factors influencing a gummy smile. It also highlights the various approaches in diagnosis and management for redefining a smile.

Key Words: altered passive eruption, gingiva, gummy smile, gingivectomy.

I. Introduction

Designing an aesthetic smile is a complex process. A combined approach of a restorative dentist, periodontist and prosthodontist is often necessary to achieve successful results. The smile arc is defined as the relationship of the curvature of the incisal edges of the maxillary incisors and canines to the curvature of the lower lip in the posed smile.[1] According to Garber and Salama the three components that contribute to an esthetic smile are the teeth, the lip framework and the gingival scaffold.[2] The restorative therapy would take into consideration the colour, position and the shape of the teeth. The prime consideration of periodontal treatment is to restore and maintain the integrity of the attachment apparatus.[2] The amount of gingival display can either be minimal or excessive. The term excessive gingival display, also known as gummy smile is used when there is too much exposure of the upper gingiva during smiling.[3]

Excessive gingival display is mainly due to dentoalveolar deformities such as short clinical crown due to trauma or carious disease, altered passive eruption, gingival overgrowth and anterior dentoalveolar extrusion. There are also non-dentoalveolar deformities like vertical maxillary excess (VME), short lip and hyperactivity of the upper lip levator muscle.[4]

Factors Governing Smile[5]

- Structure of lip form- lip line ,smile line and curvature of lip
- Gingival elements- Gingival zenith, gingival display
- Smile symmetry

The lip defines the esthetic zone.[4] There are three forms of lip lines: high, medium and low.[2] According to study done by Jensen et al. 1995, 33% of younger Germanic Caucasian and 43% of younger Asian females showed high or very high smile lines and 70% of older Asian males presented with low smile lines. Only 6% of Germanic Caucasian males over 35 years showed a high or very high smile line. [6] Tjan, Miller and Josephine et al performed a semi- quantitative study on smile line variations and concluded that males predominantly displayed a low smile line whereas females predominantly displayed high smile lines.[7]

Classification Of Smile Lines [8]

This determines the amount of teeth and gingival display.

Class 1- Very high smile line (Fig 1a)

- Visibility of more than 2mm of the marginal gingiva or more than 2mm apical to the CEJ, for a healthy periodontium. This is called a gummy smile.

Class II - High smile line (Fig 1b)

- Visibility of 0-2mm marginal gingival or 0-2mm apical to the CEJ for a healthy periodontium.

Class III - Average smile line (Fig 1c)

- The cases where only gingival embrasures are visible.

Class IV - Low smile line (Fig 1d)

- The cases where both gingival embrasures and CEJ are not visible.

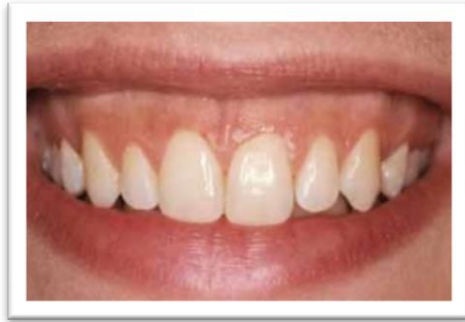

Fig. 1a: Class I

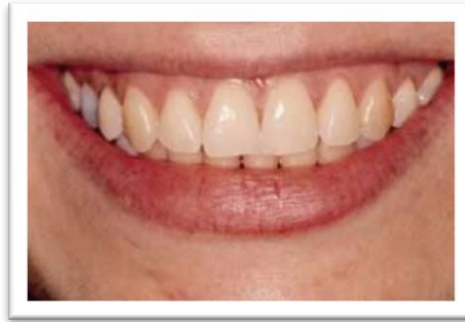

Fig. 1b: Class II

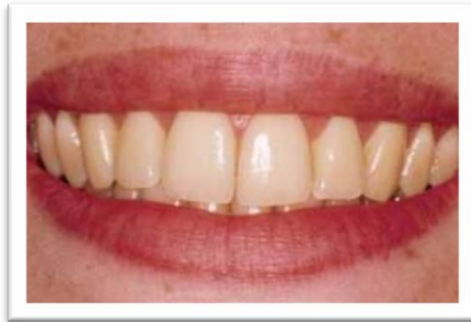

Fig. 1c: Class III

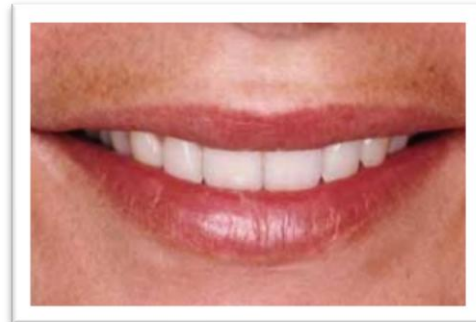

Fig. 1d: Class IV

This paper focuses on the diagnosis and etiological aspects of a gummy smile and the different steps to be considered in treatment planning of excessive gingival display.

Critical Factors To Be Considered In Gingival Aesthetics

1. Gingival Zenith

The position of the zenith of the gingival tissue seems like a small detail but it can greatly influence the axial inclination and emergence profile of the teeth, which ultimately has an impact on the beauty of a smile. Ideally the zenith of the central incisor should be at the distal third, the lateral incisor in the middle, and the cuspid can range from anterior third through to the distal third.[9] (Fig 2) However in certain conditions such as inflammation, recession, periodontitis, altered active and passive eruption this level of gingival zenith may be altered thereby creating an unesthetic smile.

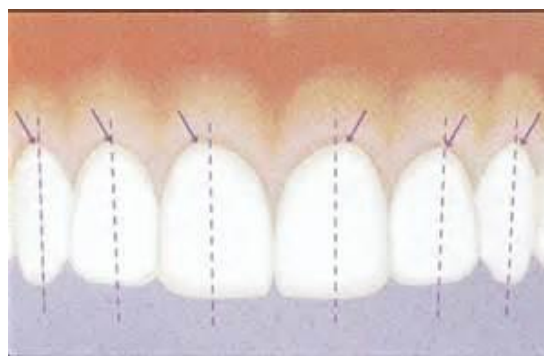


Fig 2.

2. Gingival Height Of Contour

The ideal relationship of the Gingival height of contour is a straight line, where the level with the horizontal plane will join the gingival margin of the centrals and cuspids, and this line will be harmonious with the upper lip which should just cover 1mm of the margin during full smile. This ranges from 2mm-2mm. [10]

3. Gingival Display

The amount of teeth and gingival display is a very crucial factor in contributing to an esthetic smile. Ideally 1-3mm of the incisal edges of the incisors are seen at rest and when in a full smile the tips of the papilla

and a small portion of the gingival are also displayed. However this amount of gingival display can either be minimal or excessive.

Numerous etiologies contribute to a gummy smile. It can be broadly divided into dentoalveolar deformities and non dentoalveolar deformities.

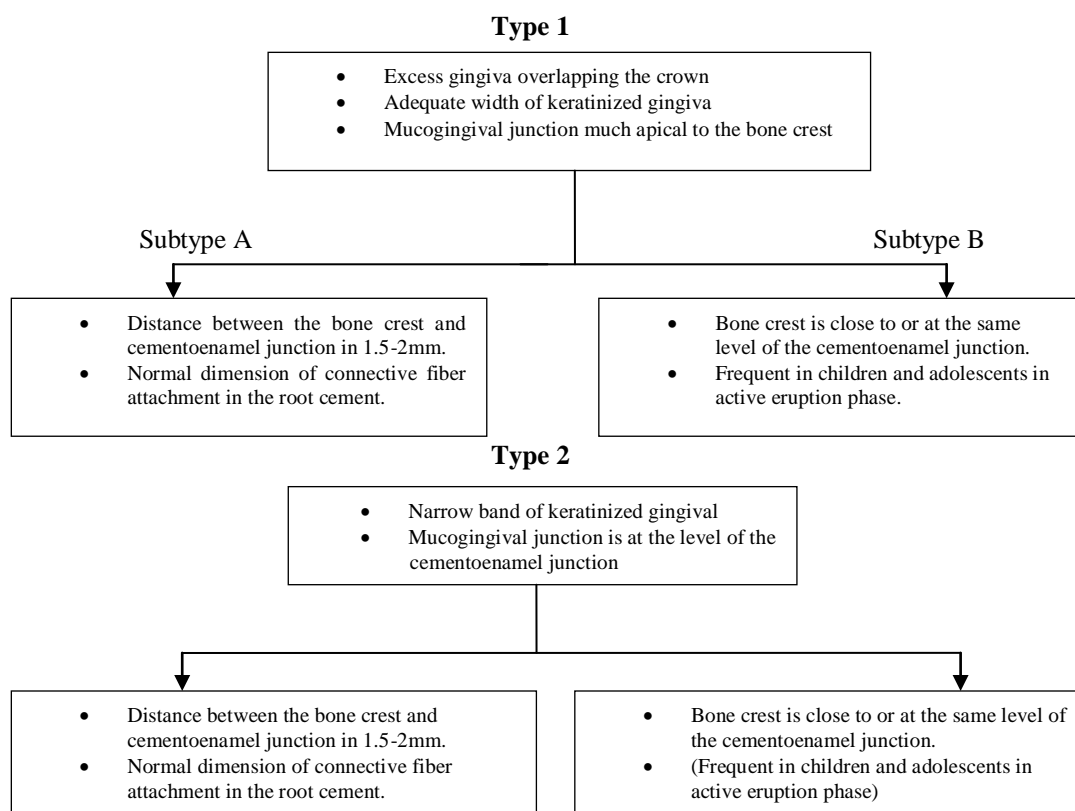
• **Dentoalveolar Deformities**

a) **Short Clinical Crown:** This is usually due to traumatic injury that may result in crown fracture. It can also be due to dental caries or incisal attrition that results in coronal destruction.[11] Crown lengthening procedures such as gingivectomy should be undertaken to lengthen the tooth in case of favourable crown root ratios. In such cases, orthodontic intrusion followed by lengthening of the incisal edge is necessary to restore the tooth to proper height.[10]

b) **Altered Passive Eruption:** During tooth eruption, the tooth actively erupts through the bone so that the CEJ is 2mm above the level of crestal bone. After eruption, the gingival complex will gradually recede to create a sulcus depth 1 to 2.5mm from the CEJ. This is called the passive eruption phase. This normal recession causes the gingiva to recede to the CEJ resulting in a sulcus depth, which ranges from 1 to 2.5mm.[10] The dimension of the soft tissue, which is attached to the portion of the tooth coronal to the crest of the alveolar bone is termed as the Biological width as explained by Gargiulo et al .[12] The biological width in humans is about 2.5mm and includes 1.5 mm epithelium and 1mm connective tissue. Goldman and Cohen[13] defined altered passive eruption as the situation in which “the gingival margin in the adult is located incisal to the cervical convexity of the crown and removed from the CEJ of the tooth”. It is otherwise called “retarded passive eruption” or “delayed passive eruption”. [14] This condition can be seen in both individual tooth and multiple teeth. The incidence of altered passive eruption in the general population is about 12.1%. [14] Simple sculpting away of the excess gingival tissue can be done to restore normal sized tooth and more ideal GHOC.[15] Delayed active eruption occurs during the eruption phase when the CEJ remains partially covered by bone.[10]

Coslet et al[15] classified Altered Passive Eruption into two types, Type 1 and Type 2, according to location of the mucogingival junction in relation to bone crest and further subdivided it according to the position of the bone crest in relation to cemento enamel junction.

The flow chart below describes the classification in detail.



c)

- d) **Gingival Overgrowth:** The prime etiology of gingival overgrowth can be due to dental plaque and calculus which is attributed to lack of oral hygiene, along with contributing factors like various drug intake like cyclosporine, phenytoin and calcium channel blockers, hormonal imbalances and endocrine problems.[16]
- e) **Anterior Overgrowth Of The Gums:** Over eruption of the maxillary incisors with their dentogingival complex leads to a more coronal position of the gingival margins and excessive gingival display. This may be associated with attrition of the teeth or with anterior deep bite.[17]
- **Non Dentoalveolar Deformities**
 - a) **Vertical Maxillary Excess (Vme):** In this situation there is excess gingival display and the teeth are of normal height. Vertical maxillary excess occurs due to excessive growth of the maxilla. Patients with VME usually appear to have a long face.[18,19] Since the occlusal plane is lower than normal, patients with VME have excessive gingival display with the lower lip covering the incisal edges of the maxillary canines and premolars[17]. Diagnosis of VME can be done by cephalometric analysis.
 - b) **Short Upper Lip:** Comparative studies performed by Peck et al have shown that in most cases of gummy smile although the upper lip appears short, clinically it is actually of normal length[20].
 - c) **Hyperactivity Of The Upper Lip Muscle:** This condition is due to the increased activity of the levator muscles of the upper lip when the patient smiles[17]. Studies confirmed that individuals with excessive gingival display showed more efficient lip elevation musculature compared to people with average smile lines.[7]

4. Papillary Height Of Contour (Phoc)

Preservation of the papilla height and symmetry is of utmost importance in achieving esthetic success and hence should be treated with care and precision during all treatments. Interproximal contact point, tooth form and root angulation and approximation are some of the factors to be taken into consideration in preserving the papillary height and position.[10] The height of the interproximal contact point must be 4.5mm from the height of the crestal bone.[21] If the contact point is greater than 4.5mm from the crestal bone, it will result in a black hole (black triangles) between the teeth. If the height is less than 4.5mm from the crestal bone to the contact, the biological width will be compromised resulting in an inflamed papilla.[10]

Papilla height is greatly influenced by root angulation and tooth rotations too. When the roots are too close together, the resulting impingement on the papilla can create strangulation of the papilla thereby causing chronic inflammation or blunting of the papilla.[10]

5. Gingival Color

Normal gingival color varies from patient to patient according to their ethnic backgrounds. This ranges from light coral pink to pink with melanotic pigmentations from light to heavy.[10]

Diagnosis

As excessive gingival display has a multifactorial etiology, it is important for the clinician to arrive at a proper diagnosis to be able to formulate a specific treatment plan.

Assessment of dentolabial characteristics of the patient includes:

- a) Interlabial assessment
- b) Exposure of upper incisor
- c) Smile arc
- d) Width / length ratio of upper incisors
- e) Anatomic characteristics of gingival and musculature of upper lip

Interlabial Distance: Gummy smile is due to muscular etiology when the interlabial distance is 1-3mm. However if the distance is more than 3mm, gummy smile is due to skeletal disharmony and / or not associated with the lip.

Upper Incisor Exposure: To have a young smile, women should have an average upper incisor exposure of 2 – 4.5 mm while men should have an average of 1 – 3 mm. However, as age increases, this exposure decreases. Increased exposure of upper incisor can be due to:

- a) Upper incisor extrusion
- b) Dolichocephalic facial pattern
- c) Vertical maxillary excess
- d) Short upper lip

Smile Arc : The smile arc should be defined as the relationship of the curvature of the incisal edges of the maxillary incisors and canines to the curvature of the lower lip in the posed smile^[1]. To have a young smile, this curvature should be parallel to the superior margin of the lower lip. Men usually have a flat curvature while women have a sharper curvature. Brachiocephalic patients manifest a flatter smile arc as compared to dolichocephalic patients.

Width / Length Of Upper Incisors : Gold standard ratio is where the width of the maxillary incisor is 80% of the length. Variation between 65% - 85% is acceptable. High width/length ratio is found in square teeth whereas low width/length ratio is found in long teeth. This ratio is dependent on facial pattern. Gummy smile can demonstrate short teeth.

Anatomic Considerations Of Gingival And Musculature Of Upper Lip : The gingival margin should be healthy and harmonious with the teeth. However, gingival overgrowth can also give the appearance of short clinical crown. Gingival overgrowth can be caused by inflammation, associated with systemic disease or conditions or maybe drug induced (phenytoin, calcium channel blockers, etc).

Morphofunctional Features Of Upper Lip: This includes the length, thickness, insertion, direction and contraction of lip musculature. The normal length of upper lip for men is 24 mm and 20 mm for women.

Certain guidelines also have to be followed during the diagnosis of excessive gingival display.

a) Skeletal Assessment

Table 1 below describes the the 3 skeletal forms and their features.

Table 1

SKELETAL FORMS	FEATURES
Mesocephalic	Normal dental arches
Dolichocephalic	Long narrow heads. Exposure of the upper lip common.
Brachycephalic	Broad short heads, broad dental arches and flat smile arcs.

b) Occlusion Assessment

Dental occlusion of the patient has to be assessed if any occlusal discrepancies are present like rotated teeth, deep bite or crowding which has to be corrected with orthodontic treatment.

c) Assessment Of Lips And Gingiva.

The lips also have to be in harmony with the skeletal base and the teeth. Hyperactivity of the upper lip and length of the upper lips has to be checked. Health of gingiva and periodontium is also important during the diagnosis of excessive gingival display.

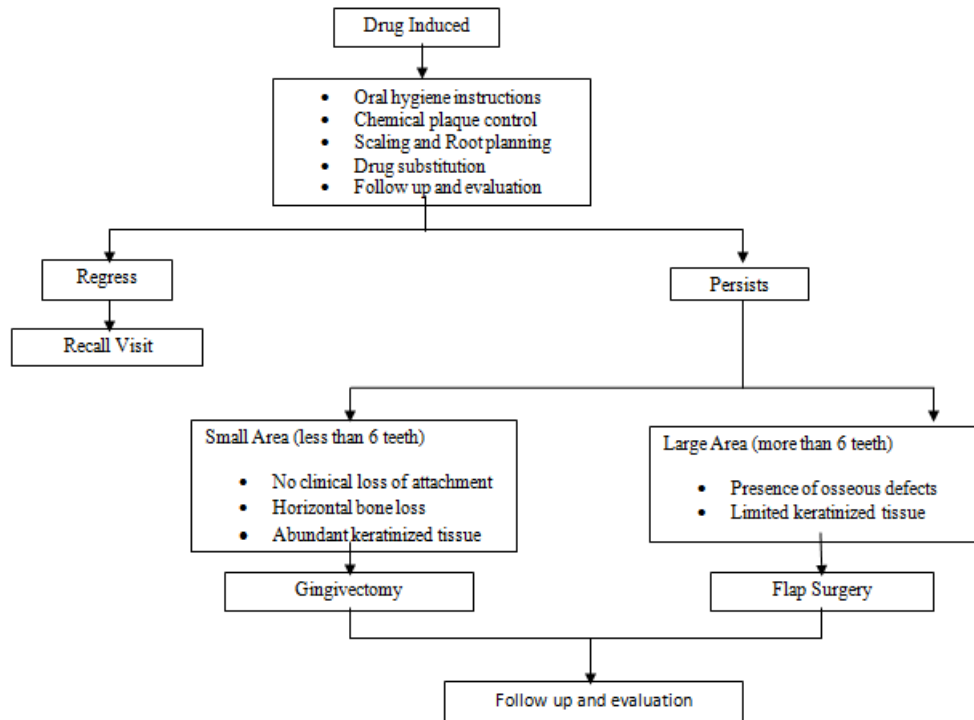
Treatment Plan

The decision for proper treatment depends on the etiologic factors that cause the excessive gingival display. Interdisciplinary approach should be undertaken by the oral surgeon, orthodontist, periodontist and prosthodontist in assessing the deformity involved and planning the treatment.

1) Treatment For Correcting Gummy Smile Due To Gingival Enlargement

If gingival enlargement is caused by inflammation, it can be managed by performing simple prophylactic procedures like scaling and root planning. Chemical plaque control measures like chlorhexidine mouth rinse can be prescribed to the patient. Oral hygiene instructions should be given and periodic recalls should be done to ensure that the inflammation subsides[22].

However, if the gingival enlargement is drug induced, a different treatment plan should be considered. The flow chart below discusses the treatment plan for drug induced gingival enlargement[22].



2) Treatment of gummy smile due to altered passive eruption (APE)

Table 2 below discusses the treatment for correcting gummy smile due to altered passive eruption[17].

Table 2

Type	Treatment
Type 1A	Gingivectomy
Type 1B	Apically positioned flap with osseous resection
Type 2A	Apically positioned flap without osseous resection
Type 2B	Apically positioned flap with osseous resection

3) Treatment Of Gummy Smile Due To Short Lip And Hyperactive Lip

There are a number of treatment modalities suggested for the correction of gummy smile due to short upper lip. Rubenstein and Kostianovsky et al have described a surgical technique whereby an elliptical excision of gingiva and buccal mucosa is done, thus establishing lower connection between the upper and the gingival tissues, thereby restricting the upper lip elevation during smile which limits the amount of gingival tissue exposure. [23] Later in 1979, Litton and Fournier et al modified this technique such that the detachment of lip muscles from bony structures above should be done to bring the lip down[24]. Miskinyar et al in 1983 demonstrated myectomy and partial resection of levator labi superioris.[25] Maria Polo et al(2005) has done studies that incorporates the use of Botulinum toxin type A injection, as a non surgical management in the reduction of gummy smile[26]

4) Treatment For Correcting Gummy Smile Due To Vertical Maxillary Excess

If the gingival display is in the range of 2-4mm, orthodontic intrusion can be done to correct it along with periodontal therapy. If the display is 4-8mm, a combination of periodontal and restorative therapy is attempted. The choice of orthognathic surgery depends on the remaining amount of root present in the bone and the crown-root ratio. If the display is greater than 8mm, orthognathic surgery is the only option.[2]

II. Conclusion

Esthetic awareness has increased among the adult population which has created a drive amongst dentists to improve their esthetic demands. A proper analysis of occlusal, gingival and skeletal factors is essential in evaluating the patient’s smile line. Therefore an interdisciplinary approach should be undertaken in the treatment of excessive gingival display to contribute to a better outcome in the improvement of patient’s esthetics thereby contributing to their confidence.

References

- [1]. Sarver D.M. The importance of incisor positioning in the esthetic smile: the smile arc. *Am J OrthodDentofacialOrthop* 2001;120:98-111
- [2]. Garber D.A, Salama M.A. The aestheticsmile: diagnosis and treatment. *Periodontology* 2000, Vol 1, 1996, 18-28
- [3]. Allen EP. Use of mucogingival surgical procedures to enhance esthetics. *Dent Clin North Am* 1988;32:307-330.
- [4]. Gottesman E. Excessive gingival display: addressing multiple etiologies for optimal esthetic outcomes. *DentistryIQ*, <http://www.surgicalrestorative.com/articles/2012/09/excessive-gingival-display-addressing-multiple-etiological-for-optimal-esthetic-outcomes.html>, September 12, 2012.
- [5]. CS Baiju, Himanshu Khashu, Amit Garg. Smile Design- Periodontal outlook of basics. *JOHCD* 2010;4.
- [6]. Jensen J, Joss A, Lang N.P. The smile line of different ethnic groups in relation to age and gender. *Acta Med Dent Helv* 4 1999 : 38-46
- [7]. Tjan AH, Miller GD, Josephine GP The. Some esthetic factors in smile design. *J Prosth of Dent* 1984;51:24-28.
- [8]. Liébert M.F, Fouque-Deruelle C, Santini A, Dillier F.L, Monnet-Corti V, Glise J.M, Borghetti A. Smile Line and Periodontium Visibility. *Perio*,1:17-25, 2004.
- [9]. Gargiulo, R., The Concepts, Contours and Cosmetics of Periodontics and Restorative Dentistry for the General Practitioner. *CDS Review*, 1983;76(8):26.
- [10]. Ron Goodlin. Gingival Aesthetics: A critical factor in Smile Design. *Oral Health Group*. 2003-04-01.
- [11]. Levine RA, McGuire M. The diagnosis and treatment of gummy smile. *Compend Contin Educ Dent* 1997 Aug;18(8):757-62; quiz 766.
- [12]. Gargiulo AW, Wentz FM, Orban B. Mitotic activity of human oral epithelium exposed to 30 percent hydrogen peroxide. *Oral Surg Oral Med Oral Path* 1961;14:474-92.
- [13]. Goldman HM, Cohen DW. *Periodontal therapy*, de 4 St.Louis, C.V. Mosby Company 1968.
- [14]. Velchanksy A, Cleaton-Jones PE. Delayed passive eruption- A predisposing factor to Vincents infection? *J Dent Asso S Africa* 1974;29:291-294.
- [15]. Coslet JG, Vanarsdall RL, Weisgold A. Diagnosis and classification of delayed passive eruption of the dento-gingival junction in the adult. *Alpha Omegan* 1977;70(3):24-28.
- [16]. Claffey N. Plaque-induced gingival disease. In: Lindhe J, Karring T, Lang NP (eds). *Clinical Periodontology and Implant Dentistry*, ed 4. Oxford: Blackwell Munksgaard, 2006.
- [17]. N. Silberg, M. Goldstein, and A. Smidt. Excessive gingival display – etiology, diagnosis and treatment modalities. *Quintessence Int* 2009;40:809-818
- [18]. Chiche GJ, Pinault A. Esthetics of anterior fixed prosthodontics. Chicago *Quintessence* 1994.
- [19]. Kawamoto HK Jr. Treatment of elongated lower face and the gummy smile line. *Clin Plast Surg* 1982;479-489.
- [20]. Peck S, Peck L, Kataja M. The gingival smile line. *The Angle Orthodontist*, 1992, Vol.62 No.2
- [21]. Tarnow, D.P., Mabner A.W., Fletcher, P.: The effect of the distance from the contact point to the crest of bone on the presence or absence of interproximal papilla. *J. Periodontol* 1992 Dec., 63(12).
- [22]. Newman M.G, Takei H.H, Klokkevold P.R, Caranza F.A, Elsevier, 10th edition *Clinical Periodontology*, pg 921, 2006.
- [23]. Rubinstein A, Kostianovsky A. Cosmetic surgery for the malformation of the laugh: Original technique. *Prensa Med Agent*, 1973;952-954
- [24]. Litton C, Fournier P. Simple surgical correction of the gummy smile. *Plast Reconstr Surg*, 1979;60:952-954
- [25]. Miskinyar S.A. A new method for correcting a gummy smile. *Plast Reconstr Surg* 1983;72:397-400
- [26]. Polo M. Botulinum toxin type A in the treatment of excessive gingival display. *Am J OrthodDentofacialOrthop* 2005;127:214-8