

Non Surgical Management of Large Periapical Lesions-A Report of Two Cases

Dr. Bhosale Swati¹, Dr. Priya Philip², Dr. M. Ramesh Kumar³, Dr. Jayasree. S⁴

^{1,2}(Junior Residents, Department of Conservative Dentistry and Endodontics)

³(Professor and Head, Department of Conservative Dentistry and Endodontics)

⁴(Associate Professor, Department of Conservative Dentistry and Endodontics)

Abstract : Diseases of dental pulp, if not managed within appropriate time, cause periapical infection which may result in the formation of periapical lesions. It is a general belief that large periapical lesions will not heal by nonsurgical endodontic treatment and needs surgical intervention. But there is no direct evidence that all large periapical lesions need surgical intervention. When endodontic treatment is performed to accepted clinical standards, a success rate of around 90% can be expected. This article highlights the healing potential of non surgical endodontic treatment in the management of large periapical lesions.

Keywords: Calcium hydroxide, Non surgical management, Periapical lesion, Triple antibiotic paste.

I. Introduction

Lesions of apical periodontitis represent an inflammatory response to bacterial infection of the root canal [1]. Periapical radiolucency is the most pronounced clinical hallmark of these lesions[2]. They are generally diagnosed either during routine dental radiographic examination or following acute pain in a tooth[3]. When endodontic treatment is performed to accepted clinical standards, a success rate of around 90% can be expected[4]. All inflammatory periapical lesions should be initially treated with conservative non surgical procedures[5]. Surgical intervention is recommended only after non surgical techniques have failed [6]. Performing apical surgery on every case with a periapical lesion will most likely enhance healing kinetics. Nevertheless, it can hardly be justified because surgery has repercussions for the well-being of the patient; swelling, pain, and discomfort are among the expected side effects [7]. Furthermore, many anatomic locations preclude apical surgery either because of inaccessibility or risk to adjacent structures. In accordance, the American Association of Endodontists recommends performing apical surgery only in cases that cannot be treated otherwise [8].

This article presents non surgical regression of large periapical lesions associated with multiple maxillary teeth in case 1 and mandibular teeth in case 2.

II. Case Reports

2.1 Case: 1

A female patient 17 years of age, reported to the department of Conservative Dentistry and Endodontics of our institution with the chief complaint of swelling and intermittent pain in relation to upper front teeth. A history of accident 8 years back involving trauma to lower face region was recorded. There was slight bearable pain since one year and swelling since 4-5 months which has been increasing progressively.

Detailed intra oral examination revealed palatal as well as buccal vestibular swelling in the relation to 21 and 22 (Fig: 1A & 1B). Hard tissue examination showed Ellis class 2 fractured 21 with mild discoloration. Pulp sensitivity testing using Endo-frost (Roeko, -50⁰ C) on 11, 21 and 22 gave a negative response. Radiographic analysis indicated the presence of a large periapical radiolucency approximately 3cmx2cm in dimension, involving the immature root apex of 11 and 21 (Fig: 1C). The condition was diagnosed as pulp necrosis with symptomatic chronic apical periodontitis secondary to trauma. Treatment plan was decided and informed consent was obtained from the patient. Access cavity preparations were done on 11, 21 and 22 under rubber dam isolation. Working length of each tooth was determined and confirmed with radiographs. Shaping and cleaning was done using hand K files (Sybron Endo) and more emphasis was given on chemical debridement. Master apical file sizes for tooth 11 and 21 was #80 K file where as for tooth 22 it was # 50. Pus drainage was observed after access preparation. Triple antibiotic paste made up of Metronidazole, Ciprofloxacin and Minocycline was placed as an intracanal medicament and the coronal part was sealed with Cavit (3M ESPE) for three weeks. Patient was recalled and triple antibiotic paste was removed using 5.25% sodium hypochlorite. The canal was packed with Calcium Hydroxide paste (RC Cal-Prime Dental) for 2 weeks. Obturation was then completed on 22 with cold lateral condensation of Gutta Percha (Fig: 1 D). Fresh Calcium Hydroxide was placed in the weeping canals of 11 and 21. Patient was recalled every 3 weeks for next 3 months and Calcium Hydroxide was replaced every 3 weeks in 11 and 21. After 3 months, radiographic examination

revealed reduction of periapical radiolucency (Fig:1E). After ensuring that the canals were dry, one step MTA (Pro root MTA-Dentsply,Tulsa Dental) apexification was done in 11 and 21 and obturated using gutta percha(Fig:1F).Marked reduction in periapical radiolucency was found during the 6 month follow up visit(Fig:1G). Patient was asymptomatic at all the appointments.

2.2 Case: 2

A 25 year old male patient reported to the department of Conservative Dentistry and Endodontics with the chief complaint of pain and swelling in lower front teeth region since 7-8 months. There was a history of trauma while playing football 5 years back. Clinical examination revealed a large labial vestibular swelling in the region of teeth numbered 31 and 41 along with a grade 2 mobility of the teeth. Radiographic analysis showed a moderate periapical radiolucency of approximately 2cmx2cm in dimension (Fig:2A). Pulp sensitivity testing using Endofrost (Roeko,-50⁰ C) showed a negative response with both 31 and 41. Access cavity preparations of both teeth were done under rubber dam isolation. Cleaning and shaping was performed to the apical file size of 40 using hand K files(Sybron Endo),copiously irrigated with sodium hypochlorite which was agitated ultrasonically, and Calcium Hydroxide paste (RC Cal-Prime Dental) was placed as intracanal medicament which was replaced after every 3 weeks for 3months. Following radiographic examination, obturation was completed with gutta percha using lateral condensation technique after ensuring that the canals were dry (Fig: 2B). Resolution of periapical radiolucency was observed on radiographs at 6 month (Fig: 2C) and 1year (Fig: 2D) follow up visits.

III. Discussion

Most periapical lesions (>90%) can be classified as dental granulomas, radicular cysts or abscesses [9,10].The incidence of cysts within periapical lesions varies between 6 and 55%[11].There is clinical evidence that as the periapical lesions increase in size, the proportion of radicular cysts increases. However, some large lesions have been shown to be granulomas [12].The definitive diagnosis of a cyst can be made only by a histological analysis.

Treatment options to manage large periapical lesions range from nonsurgical root canal treatment and apical surgery to extraction [13].Various nonsurgical methods have been used in the management of periapical lesions including conservative root canal therapy without adjunctive treatment, passive decompression of the lesion, active non surgical decompression technique using the Endo-eze vacuum system, needle aspiration of the cystic fluid using a buccal palatal approach,aspiration through the root canal,methods using intra canal calcium hydroxide,lesion sterilization and repair therapy(LSTR) and apexum procedure[14]. Conventional nonsurgical root canal therapy is the treatment of choice in managing teeth with large periapical lesions[15] When this treatment does not succeed in resolving the periradicular pathosis, additional options must be considered, such as nonsurgical retreatment or periapical surgery.

Irrigation with 5.25% sodium hypochlorite and adequate biomechanical preparation is recommended for effective neutralization and removal of infection from the root canal system, followed by calcium hydroxide intracanal medication[16]. The benefits of calcium hydroxide include anti inflammatory action through its hygroscopic properties,forming calcium-protein bridges, phospholipase inhibition,neutralization of acidic products,activation of alkaline phosphatase and antibacterial action[17].The efficacy of calcium hydroxide depends on the sustained release of calcium and hydroxyl ions to the root canal system and periapex.As they are progressively resorbed by the periapical fluids,regular renewal of the canal dressing is fundamental in decreasing the intensity of the periapical inflammatory process [16]. The triple antibiotic paste has been proven to be effective in eliminating bacteria from infected dental tissues [18,19,20]. Metronidazole has a wide bactericidal spectrum against anaerobes. Ciprofloxacin and minocycline are effective against bacteria resistant to metronidazole [20]. Despite the little amount of used medicament, sensitivity of patients to chemicals or antibiotics should be ruled out before their use [21]. The disadvantage of the triple antibiotic paste is tooth discoloration induced by minocycline. Cefaclor and fosfomycin are proposed as alternatives to minocycline [22].

Ultrasonics in endodontics(Endosonics) is a useful adjunct in cleaning difficult anatomic areas in root canals such as webs and fins. It has been demonstrated that an irrigant in conjunction with ultrasonic vibration which generates a continuous movement of the irrigant and is directly associated with the effectiveness of cleaning of canal space[23].

IV. Conclusion

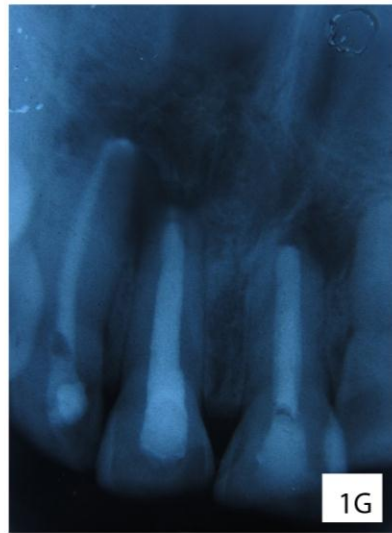
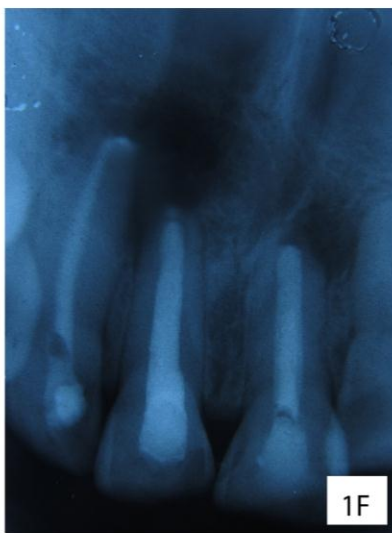
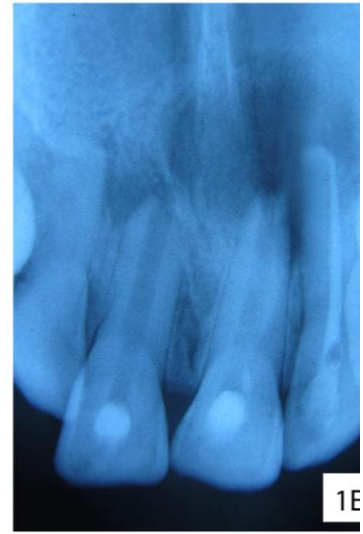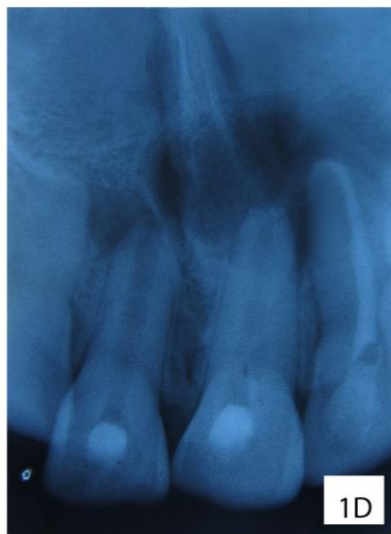
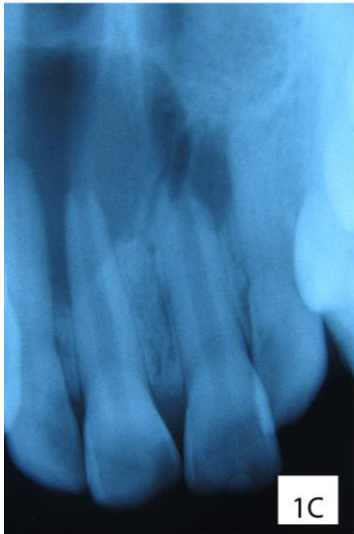
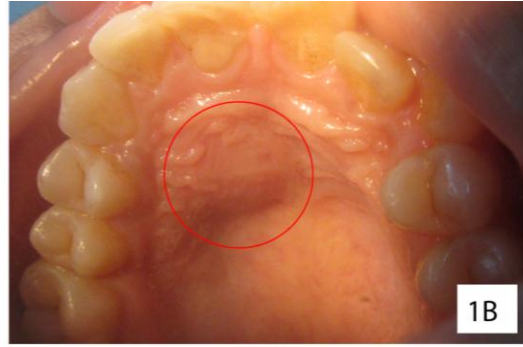
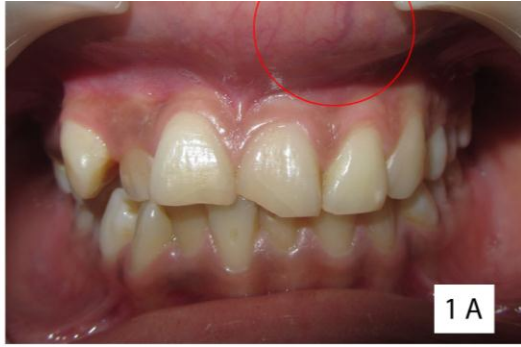Root canal treatment rendered with the highest standards of care with attention to asepsis, adequate cleaning and shaping, irrigation, canal disinfection and judicious use of triple antibiotic paste and calcium hydroxide can culminate in non surgical regression of large periapical lesions. However, to ascertain that complete healing has taken place, longer follow up periods are recommended.

References

- [1] Ørstavik D. Time course and risk analysis of the development and healing of chronic apical periodontitis in man. *Int Endod J* 1996;29:150–5.
- [2] Friedman S. Prognosis of initial endodontic treatment. *Endod Topics* 2002;2:59–88.
- [3] Barbakow FH, Cleaton-Jones PE, Friedman D. Endodontic Treatment of teeth with periapical radiolucent areas in a general dental practice. *Oral Surg* 1981;51:552-9.
- [4] Sjogren U, Hagglund B, Sundqvist G, Wing K. Factors affecting the long-term results of endodontic treatment. *J Endod* 1990; 16: 498–504.
- [5] Lin LM, Huang GT, Rosenberg PA. Proliferation of epithelial cell rests, formation of apical cysts and regression of apical cysts after periapical wound healing. *J Endod* 2007;33:908-16.
- [6] Nicholls E. *Endodontics* 3rd ed. Bristol :John Wright Sons Ltd 1984 p-206.
- [7] Kvist T, Reit C. Postoperative discomfort associated with surgical and nonsurgical endodontic retreatment. *Dental Traumatol* 2000;16:71–4.
- [8] Appropriateness of Care and Quality Assurance Guidelines. 3rd ed. Chicago, IL: American Association of Endodontists; 1998.
- [9] Bhaskar SN. Oral Surgery-oral pathology conference number 17, Walter Reed Army Medical Center. Periapical lesions-types incidence and clinical features. *Oral Surg Oral Med Oral Pathol* 1966;21:657-71.
- [10] Lalonde ER, Leubke RG. The frequency and distribution of periapical cysts and granulomas. *Oral Surg Oral Med Oral Pathol* 1986;25:861-8.
- [11] Nair PNR, Pajarola G, Shroeder HE. Types and incidence of human periapical lesions obtained with extracted teeth. *Oral Surg Oral Med Oral Pathol oral Radiol Endod* 1996;81;93-102.
- [12] Natkin E, Oswald RJ, Carnes LI. The relationship of lesion size to diagnosis, incidence and treatment of periapical cysts and granulomas. *Oral Surg Oral Med Oral Pathol* 1984;57:82-94.
- [13] Loushine RJ, Weller RN, Bellizzi R, Kulild JC. A 2-day decompression: a case report of a maxillary first molar. *J Endod* 1991;17:85-7.
- [14] Marina Fernandes, Ida de ataide. *Journal of Conservative Dentistry* Oct-Dec 2010.vol 13.
- [15] Walton RE, Torabinejad M. *Principles and practice of endodontics*. 3rd ed. WB Saunders Co.; 2002.
- [16] Soares JA, Santos SMC, Silveira FF, Nunes E (2006) Non surgical treatment of extensive cyst like periapical lesion of endodontic origin. *Int Endod J* 39,566-575.
- [17] Siqueira JF, Lopes HP (1999) Mechanisms of antimicrobial activity of calcium hydroxide: a critical review. *Int Endod J* 32,361-369.
- [18] Takushige T, Cruz EV, Asgor Moral A, Hoshino E. Endodontic treatment of primary teeth using a combination of antibacterial drugs. *Int Endod J* 2004;37:132-8.
- [19] Hoshino E, Kurihara-Ando N, Sato I, Uematsu H, Sato M, Kota K, Iwaku M. In-vitro antibacterial susceptibility of bacteria taken from infected root dentine to a mixture of ciprofloxacin, metronidazole and minocycline. *Int Endod J* 1996;29:125-30.
- [20] Sato I, Ando-Kurihara N, Kota K, Iwaku M, Hoshino E. Sterilization of infected root-canal dentine by topical application of a mixture of ciprofloxacin, metronidazole and minocycline in situ. *Int Endod J* 1996;29:118-24.
- [21] Özcan Ü, Kürşat E. Endodontic treatment of a large cyst-like periradicular lesion using a combination of antibiotic drugs: a case report. *J Endod* 2005;31:898-900.
- [22] Kim JH, Kim Y, Shin SJ, Park JW, Jung IY. Tooth discoloration of immature permanent incisor associated with triple antibiotic therapy: a case report. *J Endod* 2010;36:1086-91.
- [23] Gnanluca Plotino, Cornelis H, Pameijer, Nicola Maria Grande, Francesco Somma. *Ultrasonics in endodontics: a review* JOE 2007 vol 33.

Figure Legends

- 1 A- Clinical photograph showing labial vestibular swelling.
- 1 B- Clinical picture of palatal swelling.
- 1 C- IOPA revealing periapical radiolucency in relation to 11,21,22.
- 1 D- IOPA on 1 month follow up, obturation completed with 22.
- 1 E- 3 month follow up radiograph showing resolving periapical radiolucency.
- 1 F- Radiograph after MTA apexification and obturation of 11,21.
- 1 G- 6 month follow up, IOPA reveals marked reduction in periapical radiolucency.
- 2 A- Preoperative radiograph showing periapical radiolucency in relation to 31, 41.
- 2 B- Master cone radiograph taken after 3 month of initiation of endodontic treatment.
- 2 C- 6 month follow up radiograph shows reducing periapical radiolucency.
- 2 D- 1 year follow up, remarkable reduction in periapical radiolucency is observed.



Case 2

