

Reno alimentary fistulae

Dr. J. V. Hardikar *

Faculty of Medicine AIMST university Malaysia

Abstract: *Reno alimentary fistulae are rare. The article describes various types of reno alimentary fistulae including rarer calico colic fistula and vesico colic fistula due to diverticulosis. The clinical features and management is discussed; and the relevant literature reviewed.*

Key words: *reno alimentary fistulae, calico colic fistula, vesico colic fistula*

I. Introduction:

Reno alimentary fistulae are rare. They can occur at various levels. The etiology can be varied. It could be due to inflammatory lesions of the urinary tract causing erosion in the adjacent small or large bowel. The iatrogenic fistulae can occur due to damage to the colon during percutaneous nephrolithotomy; Reno alimentary fistula has also been reported as a complication of percutaneous radiofrequency ablation and laparoscopic cryo ablation¹ of tumors. Some of the fistulae are intentionally created like ileal conduit as a procedure for urinary diversion following total cystectomy.

Following cases illustrate the various presentations of reno alimentary fistulae.

A 40 yr. old male patient presented with frequent attacks of right ureteric colic. The clinical examination was essentially normal except for tenderness in the right renal angle. Blood urea nitrogen and Serum creatinine levels were normal. Plain X-ray abdomen showed a radio-opaque shadow in the region of renal pelvis. Intravenous urography showed no excretion of dye from the right kidney however the left sided kidney showed prompt excretion indicating normal function. There was a radio opaque shadow seen indicative of calculus in right upper part of ureter. A provisional diagnosis of right ureteric calculus resulting in hydronephrosis was made. Antegrade pyelography was done to evaluate the degree of hydronephrosis. Antegrade pyelography showed dilatation of renal calyces and appearance of contrast in the colon; thus diagnosis of calico colic fistula was made. (Fig.1) The patient was explored after thorough bowel preparation. A fistula was found between the kidney and posterior part of hepatic flexure of colon. After mobilization of kidney, the involved part of colon was excised and colonic wound was sutured in two layers. Ureterolithotomy was done to remove the calculus. Though the stone was impacted in the ureter, there was no narrowing. The patient made uneventful recovery.

Case 2: 70 yr. old lady presented to general practitioner with pyrexia of unknown origin for three weeks. Hematological examination showed microcytic hypochromic anemia and leukocytosis. The urine examination showed plenty of pus cells. She was treated with antibiotics to which she responded for some time. The fever and urinary symptoms recurred. At this juncture she was referred to us. She was investigated to find the cause of repeated urinary tract infections. A CT scan showed fistulous communication between bladder and sigmoid colon. She was explored; during surgery the fistula was found between the colon and urinary bladder (Fig.2)

The involved portion of colon was excised and Hartman's procedure was carried out (Proximal end was brought as end colostomy and closure of distal stump). The patient made uneventful recovery. She declined to undergo the reversal of Hartman's procedure and remained asymptomatic since then.

Case 3 A 78 yr. old lady presented with vague ill health, low grade fever and pneumaturia. She did not give history of passing blood per rectum or progressive constipation. She underwent colonoscopy which showed diverticulosis and inflamed area of colon. A CT scan showed fistula between the bladder and colon and presence of air in the urinary bladder (Fig.3). She was advised surgery which she refused. Her symptoms are under control with antibiotics and bulk laxatives

II. Discussion:

The first reno alimentary fistula was reported by Hippocrates, father of medicine in 460BC². They were increasingly recognized in mid nineteenth century. Most of these fistulae were secondary to renal tuberculosis. The incidence of fistulae has gone down due to effective chemotherapy for tuberculosis and control of pyogenic renal infections. The etiology has now changed to malignancy and percutaneous interventions. As more patients with small renal tumors are now undergoing advanced forms of tumor treatment, surgeons should be mindful of renoalimentary fistulae as a potential complication of them.³⁻⁴

Reno alimentary fistulae comprise less than 1% of fistulae between the urinary and intestinal tracts, Long standing fistulae are as a result of neglected cases of renal calculi leading to infection and fistulation in alimentary tract. Pyeloduodenal fistula can occur as a result of the foreign object lodging in the duodenum with resultant inflammatory reaction that involves the duodenum and adjacent renal pelvis posteriorly.

The clinical presentation may vary depending upon the site of communication and the size of fistula. If the fistulous opening is small then patients present with repeated attacks of urinary tract infection. Larger. Fistulae can lead to diarrhea, pneumaturia and gross contamination of urinary tract with fecal organisms. The fistulae resulting from percutaneous nephrostomy tube placement, gas and enteric contents may drain through the tube, while voided urine may or may not appear normal.

Reno alimentary fistula can occur due to bladder cancer invading a loop of small bowel or colonic malignancy invading the bladder. ;however the common cause of colovesical fistula is diverticulosis.

Vesico colonic fistula is seven times more common in males than females, indicating that the uterus may play a role in the prevention of fistulization to the bladder. Moreover, in women with diverticulitis, vaginocolonic fistulas are much more frequent than vesicolonic fistulas, further supporting the role of the uterus as a protective anatomic barrier.

Despite the fact that most vesicoenteric fistulas are the result of primary bowel disease, patients most often have urologic symptoms, with a significant absence of localizing intestinal symptoms. Since some patients have very minimal symptoms, the clinical suspicion is very important. The obvious symptoms like pneumaturia and fecaluria are not common unless fistulous communication is large. In cases where patient presenting with recurrent urinary tract infection without any stone disease, malignancy or obstructed urinary tract, one should suspect communication with gastro intestinal tract. In elderly patients a diverticulosis is the commonest cause.

Physical signs are minimal. Some patients present with lump and local abdominal tenderness due to localized sepsis. Urinalysis may show striated muscle fibers (rhabdomyocytes) derived from undigested meat residue from stool, Urine cultures show predominantly E.coli rather than polymicrobial flora. Urine culture may be negative if the fistula is temporarily blocked because of edema.

Once reno alimentary fistula is suspected, it is necessary to document its presence and site. This can be done imaging with contrast studies. Cystoscopy may be diagnostic in colovesical fistulas.

Management of reno alimentary fistula depends on the site of fistula, status of the kidney and the degree of sepsis. The involved bowel is resected or the portion of it is excised if the communication is small It may be combined with nephrectomy; if the kidney is irreparably damaged. The high risk elderly patients with minimal symptoms can be managed conservatively with intermittent antibiotics and percutaneous drainage. In the rare cases of renoalimentary fistula following radiofrequency ablation or cryoablation, conservative measures have been found to be successful⁵

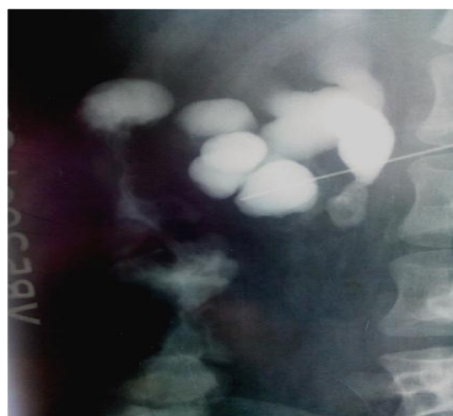

Fig.1 Antegrade pyelography showing contrast in the colon

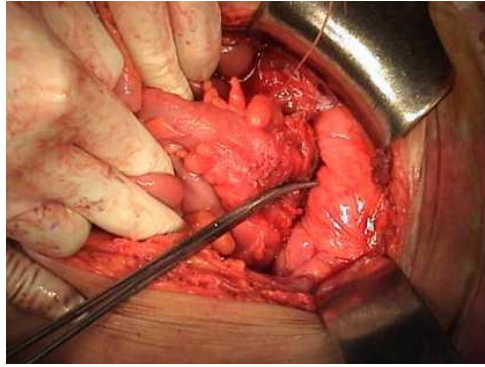


Fig.2 showing operative photograph of vesico colic fistula

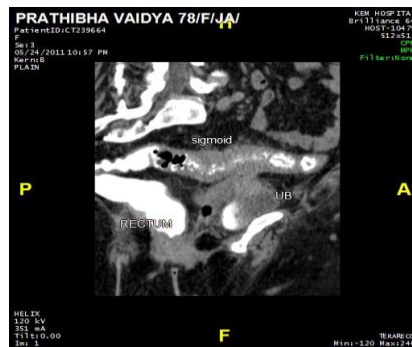


Fig. 3 CT scan shows vesico colic fistula and air in the bladder

References:

- [1]. Colo-renal fistula: An unusual cause of hematochezia John D Wy etal World J Gastrointest Pathophysiol. 2010 August 15; 1(3): 106–108. Published online 2010 August 15 [10.4291/wjgp.v1.i3.106](https://doi.org/10.4291/wjgp.v1.i3.106) PMID: PMC3097949
- [2]. Martha K Terris, MD, FACS; Chief Editor: Edward David Kim, MD, FACS [emedicine.medscape.com/article/441604-overview](https://www.medscape.com/article/441604-overview)
- [3]. Silverman SG, Tuncali K, vanSonnenberg E, Morrison PR, Shankar S, Ramaiya N, Richie JP. Renal tumors: MR imaging-guided percutaneous cryotherapy--initial experience in 23 patients. *Radiology*. 2005;236:716–724. [[PubMed](#)]
- [4]. Arthur GW, Morris DG. Reno-alimentary fistulae. *Br J Surg*. May 1966;53(5):396-402. [[Medline](#)].
- [5]. Vanderbrink BA, Rastinehad A, Caplin D, Ost MC, Lobko I, Lee BR. Successful conservative management of colorenal fistula after percutaneous cryoablation of renal-cell carcinoma. *J Endourol*. 2007;21:726–729. [[PubMed](#)]

*The author was Professor and head, department of Surgery at Seth G.S.medical College & K.E.M.Hospital ,Mumbai India.