

## The Recent About Growth Modification Using Headgear and Functional Appliances in Treatment of Class II Malocclusion: A Contemporary Review

EyadAlmuhtaseb<sup>1,2</sup>, Mao Jing<sup>1</sup>, He Hong<sup>2</sup>, Rawan Bader<sup>3</sup>

<sup>1</sup>Orthodontic department/Tongji Hospital, Tongji college, Huazhong University of Science and Technology, China

<sup>2</sup>Orthodontic department/Stomatology Hospital, Wuhan University, China

<sup>3</sup>Pediatric department/ Ministry of Health, kingdom of Saudi Arabia

**Abstract:** In this review of literature we are discussing growth modification in treating class II malocclusions. The prevalence of class II malocclusion is very high ranging from 15% to 20%, in some regions in the world it is considered the most common malocclusion, others consider it as the second common malocclusion.

It is estimated that one fourth of all patients, and one third of all children, are treated in two phase treatment. Our target here is the growing patients trying to get benefit and advantage from their growth potential. There is a lot of debate and controversy regarding the optimal time of treatment, the type of appliance that produce the best treatment outcome.

Despite recent questions of the effectiveness of early treatment, it is generally recognized that the use of growth modification still has a place in modern orthodontic practices. The aim of this review is to study growth modification either by restriction of maxillary growth using the head gear or stimulating the mandibular growth using the functional appliances. In this review we discuss the orthopedic appliances usages, advantages, disadvantages of each appliance and the optimal time of treatment.

We are trying not just to achieve class I dental occlusion but also to improve the facial profile of the patients, which will improve the patients psychosocial and patient's self-esteem.

In addition to that it is very important not to forget that in orthodontics we are working on three planes not just we are trying to understand that growth modification for class II malocclusion doesn't mean just adjusting the anterior posterior plane but also we will try to treat the vertical and transverse discrepancies.

**Key points:** Class II malocclusion, functional appliance, growth modification, headgear appliance.

### I. Introduction

According to Edward Angle 1899 class II malocclusion can be defined as the condition in which the mandibular first molars occlude distal to the normal relationship with the maxillary first molar. He further divides it into two divisions: division 1 in which maxillary incisors protruding, division 2 in which the maxillary incisors retruding. On the other hand the British dental institute in 1983 defined class II as the condition in which the lower incisor edges lie posterior to the cingulum plateau of the upper incisors which are proclined or of average inclination and there is an increase in overjet<sup>[1,2]</sup>. The etiology of class II malocclusion varied between skeletal, soft tissues, dental factors and habits and the prevalence of class II is high, according to angles he estimated about 27% of malocclusion could be classified as class II, While according to the NHANES 33% class II discrepancies. Almost the same frequency was found in Caucasians, African- Americans and Hispanics. The international epidemiologic studies conducted to date suggest that there seems to be over than 20% prevalence of class II malocclusion in North American, Europe and North Africa. While in the Middle East, Asia and Latin America the prevalence is 10 to 15 %. The lowest prevalence among the black populations of sub-Saharan Africa is about 1 % to 10%<sup>[1,2]</sup>.

Most of class II accompanied by skeletal discrepancies<sup>[2]</sup>. Skeletal class II; could be because of: (1) maxillary jaw protrusion. (2) Mandibular jaw retrusion. (3) Combination of both. Another interesting statistics we have to mention it that is according to McNamara 75% of class II skeletal discrepancies are the result of mandibular retrognathia.

The treatment modalities of any skeletal problem<sup>[1]</sup>:

➤ Growth modification

Head gear, high pull, low pull and medium pull.

Functional Appliances.

➤ Dental camouflage

Fixed Appliance (extraction non extraction)

➤ And orthognathic surgery.

In growing patients all modalities can be applied while in adults only the last two can be applied. In the

early years of the 20<sup>th</sup> century, it was taken for granted that pressure against the growing face could change the way it grows. From the main stay functional appliances for treatment of mandibular deficiency in growing children. Extra oral force to the maxilla “headgear was utilized by the pioneer American orthodontists of the late 1800s, who found it reasonably effective to restrict the maxilla and allow the mandible to catch up. Later Angle and his contemporaries thought that class II elastics would cause the same effect and the usage of headgear had been abandoned in the early 20th century with the introduction of intermaxillary elastics. That was not because the headgear was ineffective, but because it was considered an unnecessary complexity as angles thoughts was. At 1936 a paper by Oppenheim revived the idea that headgear would serve as a valuable adjunct to treatment <sup>[1]</sup>. The introduction of cephalometrics to orthodontics has helped clinicians to evaluate the results achieved from headgear usage effectively. Such comprehensive documentation using cephalometric data started to appear in the 1940s. Dr. Silas Kloehn was one of the early advocates when he demonstrated successful results from cervical headgear use. Since then, a variety of headgear applications have been recommended to treat different malocclusions <sup>[3]</sup>. The requirements for treatment success by growth modification can be summarized into four major categories: (1) The timing of treatment. (2) Case selection. (3) The patient compliance. (4) Appliance selection.

Growth stimulation can be defined into two ways:

- 1- The growth attainment of final size larger than the one that would have occurred without treatment.
- 2- The occurrence of more growth during a given period of time than that would have been expected without treatment.

The objective of this review is to highlight the factors to obtain consistent good result from the orthopaedic appliance in treating children with class II malocclusion.

## **II. Timing of treatment**

Timing of treatment is one of the most important criteria in achieving successful treatment of any skeletal discrepancy. The optimal time for treatment of patients with Class II malocclusions remains controversial. Some clinicians believe strongly that beginning treatment in the mixed dentition before adolescence is advantageous, but others are convinced that early treatment is often a waste of time and resources. We have to keep in mind that the more the patient has growth potential the more we gain skeletal growth modification achievement, but if we delay treatment we have dental effect rather than skeletal effect <sup>[4]</sup>.

There are many advantageous of early treatment we have to consider it: 1- the ability to modify skeletal growth 2-better and more stable results. 3-less iatrogenic tooth damage (because roots did not develop well so there is more favorable biologic response to orthodontic treatment). 4-better cooperation can be achieved sometimes because children has less outside interests .5-improved patient self-esteem and parental satisfaction, (there is a clear correlation between improved esthetics and psychosocial wellbeing). On the other hand disadvantages of beginning treatment earlier are that the cost is increased, the variation of result and stability, patient/parent could be “burnout” and the iatrogenic problems.

If we decide to do two phase treatment, child will benefit more if he is treated during preadolescent year <sup>[1, 2]</sup>. In the absence of severe dento skeletal compensations orthopedic appliance therapy should be initiated at the beginning of cervical vertebrae maturation stage CS3 to maximize the treatment effects and reduce the need for post treatment retention <sup>[5]</sup>.

There are many methods to predict growth potential like hand wrist and cervical vertebrae radiographs, as well as talking with the child parents about the growth potential could be helpful. Keeping in mind that females grow earlier than males and to consider ethnic differences <sup>[1, 2, 6]</sup>.

Alexander suggested initiate treatment once patients have lost all primary teeth, with the exception of the primary mandibular second molars this usually occurs when patients are about 11 to 12 years old and experience period of rapid growth. Individual conditions, however, always take priority in such decision. In addition, according to his experience he found that an 8,9, or 10 years old girl respond better to head gear while boys respond better to orthopedic treatment between 12 and 14 years of age <sup>[6]</sup>.

Bondevik reported a greater treatment success with increasing the age of the patient. The mean age in the group with satisfactory treatment result was 11.95 years while the mean age in the group with the unsatisfactory group was 10.87 years this suggest that the treatment results were better with late treated cases <sup>[1]</sup>.


In 2005, Hsich and coworkers investigated 512 consecutive patients and found that it was inefficient to start treatment in the mixed dentition with early treatment objectives or to start treatment before the age of 10.5 years in males and 10 in females <sup>[6]</sup>.

## **III. Head gear**

Headgear is a common term for an appliance that is used for delivering a posteriorly directed extra oral force to the maxilla <sup>[2]</sup>, and a mechanism whereby structures outside the oral cavity are used to apply forces to the teeth <sup>6</sup>.

### 1.1 Head gear components<sup>[6]</sup> (Fig. 1)

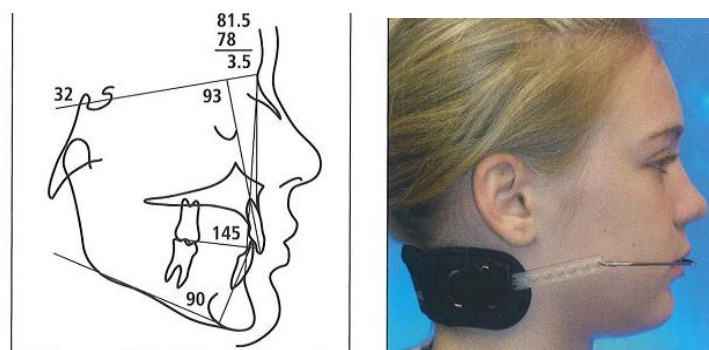
1. A head cap of which there are number of designs- they are almost always made of plastic tape that passes coronally around the occiput and sometimes around nape of the neck.
2. A face bow or whisker that fits into the fixed or removable appliance-this is made from stainless steel and there is usually an inner whisker that fits into the appliance and an outer whisker that passes outside the mouth.
3. A means of applying a force between the head cap and face bow- this can be elastic or a spring, or indeed part of the head cap may itself be elasticized.
4. Safety mechanisms- various safety components available include: a plastic neck strap that prevents the face bow from coming out of the mouth, a snap-away mechanism whereby the face bow easily disengages away from the head cap; therefore if the face bow is pulled out of the mouth it will not remain attached to the head cap and so will not spring back into the patient's face, and modifications to the facebow such as turning the ends of the facebow over on themselves so they present a bigger and blunter surface area or to have a facebow that locks into position<sup>[6]</sup>.



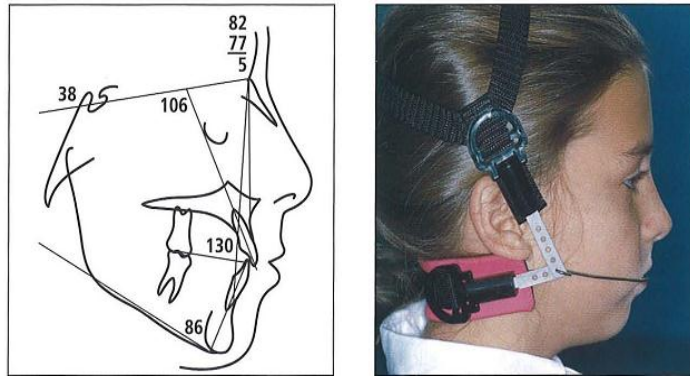
**Figure 1:** Components of headgear.

### 3.2 Head gear types

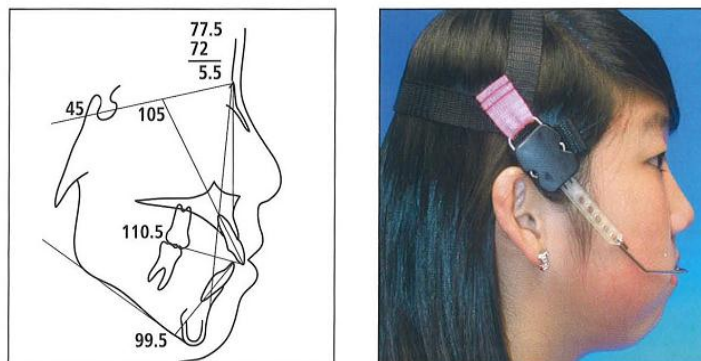
There are two types of headgear available for delivering extra oral force to the maxilla: the face bow and the J-hook headgear. The first and most common type of headgear is the face bow, which is a large-gauge wire framework consisting of an outer bow for the extra oral attachment soldered to an inner bow that attaches intraorally in tubes attached to the maxillary first permanent molar bands. Face bow can be used with either a maxillary fixed or removable appliance. The fixed appliance can be as simple as banded maxillary first permanent molars alone or can include banding or bonding of the remaining dentition. The face bow headgear can be designed in one of three ways, dependent on the direction of pull of force: low pull, straight pull, or high pull as in figures (2, 3 and 4) respectively. Also the terms occipital and cervical have synonymously been used to mean high and low pull, respectively. To distribute the external force over more surfaces and to provide more control of the direction of the force vector. The disadvantage is that patient compliance that it increases the number of parts that the patient has to wear, manage, and possibly lose<sup>[2]</sup>. Thus cooperation becomes more challenging<sup>[2]</sup>. This combination headgear the vector of the force can be adjusted to produce relatively less tipping and/or extrusion<sup>[7]</sup>.



**Figure 2:** Low pull (cervical) head gear applied for skeletal class II patient low angle pattern

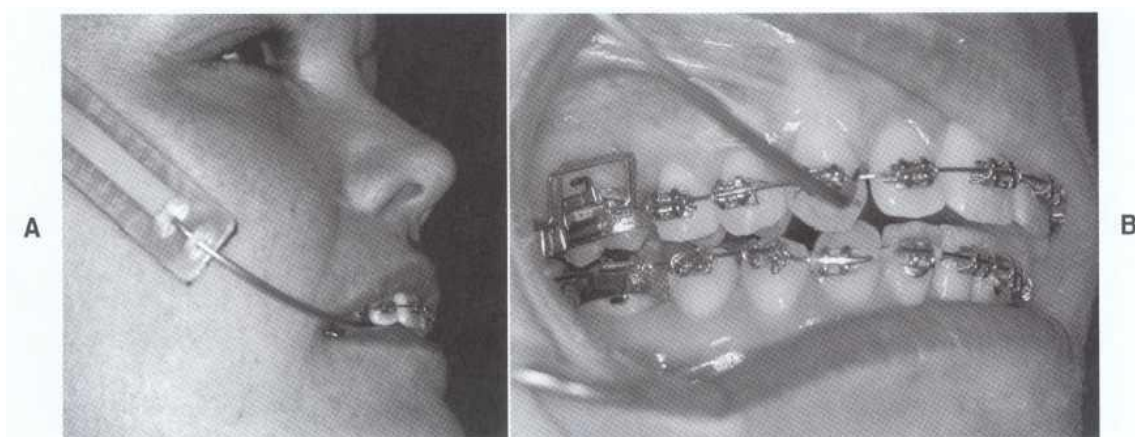


**Figure 3:** Straight (combined )head gear applied for skeletal class II patient medium angle pattern



**Figure 4:** High pull (occipital)headgear applied for skeletal class II patient high angle pattern<sup>6</sup>

The second type of headgear, J-hook headgear: it is two separate, curved, large gauge wires that are formed on their ends into small hooks, both of which attach directly to the anterior part of the maxillary arch wire. This type of headgear is more used for retraction of canines or incisors rather than orthopedic purposes. The J-hook headgear can be used only with a maxillary fixed appliance with a continuous arch wire. It is better if all the maxillary teeth are incorporated in the fixed appliance, but a minimum requirement is inclusion of the maxillary first molars and incisors<sup>[2]</sup>.



**Figure 5:** A, The intraoral attachment for the J-hook headgear is directly to the maxillary arch wire, usually placed mesial to the maxillary canines. This anterior location permits the J-hook wires to emerge from the mouth without impinging the lip commissures. B, A J-hook headgear for orthopedic purposes only should be placed with a complete fixed appliance in the maxillary arch<sup>[2]</sup>.



### **3.3 Selection of head gear type**

To select the headgear type, practitioner needs to answer series of questions: weather the patient is child or adult? Weather the facial pattern of the patient is hypo divergent or hyper divergent? What kind of malocclusion the patient has; is it dental problem or skeletal problem? What is the soft tissue picture; is it characterized by a flat lip posture or the lips are full, is it protrusive or convex? What are the anchorage requirements of the case once treatment is instituted? What are the treatment objectives for this case? Is the malocclusion class II and how is it to be corrected? The answers to these questions come only with a complete set of diagnostic records and a thorough understanding of an entire range of subjects<sup>[5]</sup>.

The initial choice of headgear configuration is usually based on the original facial pattern: the more signs of a vertically excessive growth pattern are present, the higher the direction of pull and vice versa<sup>[1, 2, 5]</sup>. According to Alexander one of the methods to select the head gear type is to depend on the vertical skeletal pattern. To provide an accurate rate assessment of the patients skeletal vertical pattern the sellanasion – mandibular plane (sn-mp), frankfort mandibular plane angle occlusal plane –mandibular plane ,and Y axis are measured .Then according to his KISS principle (keep it simple ,stupid) sn –mp is used as the reference measurement ,a simple analysis follows<sup>[6]</sup>.

- 1- If the Sn –mp angle is 35 degrees or less; class II skeletal patterns can be treated with a cervical facebow.
- 2- If the sn-mp angle is 36 \_41 degrees; vertical dimension is best treated with the use of combination head gear (occipital and cervical straps).
- 3- If the sn-mp angle is 42 degrees or greater; we need to prevent further vertical growth of the maxilla .A high pull face bow is described for the patient with high angle skeletal class II.

Also we can consider that the forces through the center of resistance of the molar should cause bodily movement, and vectors below this point should cause distal crown tipping. Control of the line of force relative to the maxilla is easier when a splint covering all the teeth is used to apply the headgear force. The face bow is usually attached to the splint in the premolar region, so that the force can be directed through the center of resistance of the maxilla that is estimated to be located above the premolar roots<sup>[1]</sup>. The literature indicates that headgear is capable of producing different force directions and moments may have advantages in particular situations. These may be summarized as follow:

- 1- Low pull J Hook headgear
  - (a) Used to the maxillary incisor region, a tipping of the incisal end of the occlusal plane in a downward direction may result, with a reduction of open bite. However, molar extrusion is probable.
  - (b) Used to the mandibular incisor region, it may depress the chin creating more vertical space into which maxillary teeth may be extruded during class III treatment. The resultant downward and backward mandibular rotation reduces the AP basal discrepancy.
- 2- Straight pull J Hook headgear
  - (a) It is suitable for moving mandibular canines distally.
  - (b) Attached to the maxillary incisor region, distal arch movement occurs, but downward tipping of the incisal end of the arch is probable.
- 3- High pull J Hook headgear
  - (a) A line of force to the maxillary incisor region passing mesial and apical to the center of resistance, will intrude the upper incisors, move them distally and augment palatal root torque.
  - (b) A line of force to the maxillary incisor region passing through the center of resistance will have a larger distal and smaller intrusive effect upon the incisor region. Theoretically this may produce greatest orthopedic effect.
  - (c) A line of force to the maxillary incisor region, passing occlusal to the centre of resistance may have a mild downward tipping effect upon the incisal end of the occlusal plane.
  - (d) It is the direction of choice for distal movement of maxillary canines, or to sliding jigs for maxillary molar distal movement or anchorage<sup>[7]</sup>.

### **3.4 Effects of head gear**

#### **3.4.1 Skeletal effect of head gear**

The headgear is used to compress the maxillary sutures, altering the growth and apposition of bone at these sutures. The result is to suppress or restrict normal downward and forward maxillary growth while the mandible continues to grow normally. The intention is for the mandible to "catch up" with the maxilla, correcting the anteroposterior skeletal discrepancy<sup>[1]</sup>.

We can predict that the growth response of the maxilla to orthopedic force is much more predictable than the growth response of the mandible. Also the effect of extraoral force with a headgear is not limited to the maxilla. Recently, there is supporting evidence from a prospective randomized controlled clinical trial that indicates enhanced mandibular growth from headgear treatment<sup>[2, 9]</sup>. The entire maxilla was displaced

posteriorly, down and back, on the cranial base, SN-PP angle was reduced<sup>[10]</sup>. Cervical traction usually used to correct a Class II malocclusion is effective in redirecting maxillary growth inferiorly and posteriorly. Kloeber cervical headgear has been most frequently used in cases of skeletal maxillary protrusion with reduced vertical dimension, producing distal displacement of the maxilla and increasing the vertical dimension, because of extrusion of the molars, generating mandibular clockwise rotation<sup>[11, 12]</sup>.

Tulloch et al found an average reduction in the SNA angle of 0.92° per year in a group allocated to early correction of Class II malocclusion with headgear<sup>[13]</sup>. Although cervical headgear is used to modify sagittal growth, it can modify vertical growth as well because of a downward and extrusive force to the upper first molar in addition to the desired backward vector. The Early use of cervical headgear does not have marked effect on the vertical growth of the face<sup>[14]</sup>, but Patients treated with headgear had significant profile improvements with treatment<sup>[15]</sup>. Marked arch length and width increases were obtained with early use of cervical headgear, indicating that the method is effective for the treatment of subjects with mild or moderate crowding<sup>[14]</sup>. Class II correction with headgear had more skeletal effect than with the pendulum. Study of the effects of cervical headgear on growing patients revealed that statistically significant maxillary basal bone changes did not occur. Cervical headgear appliances corrected the Class II Division 1 malocclusion to a Class I relationship by maintaining the maxillary first molars and redirecting dentoalveolar growth in the maxilla, rather than by significantly changing the growth of the maxillary jaw base<sup>[8, 16]</sup>. Graber described the reflexive mandibular thrust against a threat to upper airway patency associated with the use of cervical headgear, and appraised its beneficial influence on mandibular growth<sup>[17]</sup>.

### **3.4.2 Dentoalveolar effects of head gear**

The typical response from effective headgear wear is to prevent the maxillary first molars from erupting downward and forward, indirectly enhancing the forward direction of mandibular growth. Extrusion of the maxillary molars by a distal force that is directed more inferiorly can result in more downward and backward rotation of the mandible, which limits the forward expression of mandibular growth. With most skeletal Class II problems it is more desirable to have the intrusive effect on the maxillary molars to maximize the anteroposterior skeletal correction. In the minority of cases in which vertical mandibular growth expression is also desired to increase lower face height, some maxillary molar extrusion may be acceptable because the skeletal mandibular growth pattern tends to be expressed more forward with or without treatment<sup>[2]</sup>.

The dentoalveolar changes include increases in intermolar and intercanine widths. Arch width in general and length increase and an appreciable reduction in overjet can be obtained by use of the headgear alone<sup>[3]</sup>. Although minimal dental change is expected in the mandibular arch or in the anterior maxillary arch as a direct result of headgear wear, there is some evidence that the mandibular incisors may become slightly more protrusive. No appreciable movement of the maxillary incisors occurs from the use of a headgear in the absence of an arch wire connecting them to the first molars. If there is a continuous arch wire present, any distal movement of the maxillary molar crowns may also result in slight lingual movement of the incisor crowns. An intrusive and distal force can be applied to all the erupted maxillary teeth if a standard facebow is attached directly to a maxillary acrylic splint or a functional appliance<sup>[2]</sup>.

High pull headgears tend to distalize and intrude or reduce the eruption of the maxillary Molars<sup>[17]</sup>. Cervical pull headgear lead to extrusion and distalization of the maxillary first molar, and extrusion of the mandibular incisors<sup>[18]</sup>. The soft tissue profile changes were a correction of facial convexity, and an increase in lower anteroposterior, and lower vertical soft tissue dimensions. The mentolabial fold depth also significantly decreased<sup>[19]</sup>. Ghafari found that the headgear has a distal effect on the maxilla and first molars, but not the maxillary incisors and a significant increased maxillary intercanine distance and spacing among the maxillary anterior teeth with headgear treatment<sup>[16]</sup>.

### **3.5 Clinical procedure in head gear use**

If we want to use face bow that is attached to the maxillary first permanent molars, usually the only preparation of the dentition is fitting and cementing bands with headgear tubes on these molars. If the molars are severely rotated mesiolingually as it is the case sometimes, we need short period of orthodontic treatment, usually with an active trans palatal arch to rotate the maxillary first molars to permit face bow insertion. When the headgear is attached intraorally to a removable acrylic splint or functional appliance, the headgear tubes are incorporated directly into the acrylic, occlusal to the maxillary premolars. This attachment location approximates the force vector through the center of resistance for the maxilla. Under these circumstances, no special preparation of the dentition is necessary, although accurate impressions and a bite registration are necessary to fabricate the acrylic portion of the appliance.

The J-hook headgear can be delivered only after bonding of the maxillary incisors as well as banding of the maxillary molars. It is recommended that complete banding and bonding of all the maxillary teeth are considered to provide for a more stable appliance, avoiding distortion or breakage. An arch wire of adequate

stiffness to support orthopedic forces, such as 0.017-inch x by 0.025-inch stainless steel in 0.018-inch slot or 0.018-inch x 0.025-inch stainless steel in 0.022-inch slot, is recommended. For this reason, a period of time often lasting a number of months is necessary to align and level the teeth attached to the arch wire to permit placement of the stiffer wire before headgear delivery<sup>2</sup>. Preformed facebows are supplied in a variety of inner bow sizes and usually also have an adjustment loop as part of the inner bow. The inner bow should fit closely around the upper arch without contacting the teeth except at the molar tubes (within 3 to 4 mm of the teeth at all points). The correct size can be selected by fitting the bow against the maxillary cast. As a Class II molar relationship is corrected, the relative forward movement of the lower arch will produce a cross bite tendency unless the upper arch width is expanded. The inner bow should be expanded by 2mm symmetrically so that when it is placed in one tube, it rests just outside the other tube<sup>[6]</sup>. The patient will need to squeeze the inner bow as it is inserted to make it fit the tubes, thus providing the appropriate molar expansion. The outer bow should rest passively between the lips and several millimeters from the cheeks<sup>[2]</sup>.

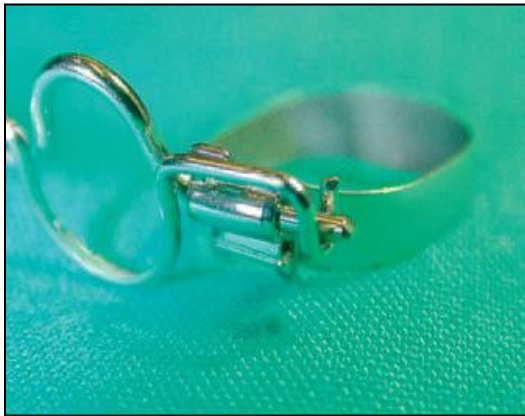It is very important to demonstrate placement and removal of the headgear to the patient with one of the parents present. This permits both the child and parent to understand how to manipulate the appliance in a safe and efficient manner. The dentist demonstrates how to carefully insert and remove the face bow without applying vertical forces with the distal ends of the inner bow in the headgear tubes that promote loosening of the molar bands. The child is then allowed to place and remove the appliance until the parent and child are confident with the process. To decrease the initial expected discomfort of wearing the headgear we either decrease the initial duration or the magnitude of force, then gradually increased until the optimum levels are reached within the first 2 weeks. The second appointment after initial delivery should be no later than 1 month to confirm that the patient is continuing to do well<sup>[2]</sup>.

The most effective extraoral force application for skeletal Class II treatment is with a face bow attached to an occipital attachment using a heavy force (400 to 600 gm per side) applied for 12 to 16 hours daily (evening and night)<sup>[2]</sup>. The growth hormone release that occurs in the early evening strongly suggests that putting the headgear on right after dinner and wearing it until the next morning-not waiting until bed time to put it on-is an ideal schedule. The current recommendation is a force of 12 to 16 ounces (350 to 450gm) per side. When teeth are used as the point of force application, some dental as well as skeletal effects must be expected. Extremely heavy forces (greater than 1000gm total) are unnecessarily traumatic to the teeth and their supporting structures, while lighter forces may produce dental but not skeletal changes.

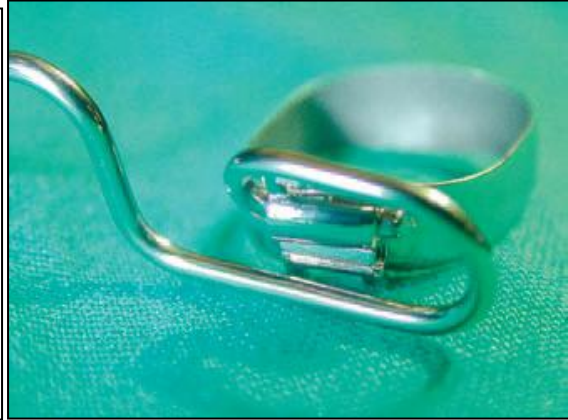Typical treatment duration 12 to 18 months, depend on rapidity of growth and patient cooperation<sup>[1]</sup>. Extra oral force must be of much greater magnitude, in order to maximize the potential for skeletal change and to minimize dental change. Forces of 12 to 16 hours' give us intermittent force which can give us skeletal effect more than dental effect. In fact, if the headgear is worn more than about 16 hr/day at force levels below approximately 400 gm or 1 pound, less skeletal effect and more dental movement will occur<sup>[1,2]</sup>. An intermittent heavy force also is less damaging to the teeth and periodontium than a continuous heavy force<sup>[2]</sup>.

### **3.6 Safety issues and complications in using head gear**

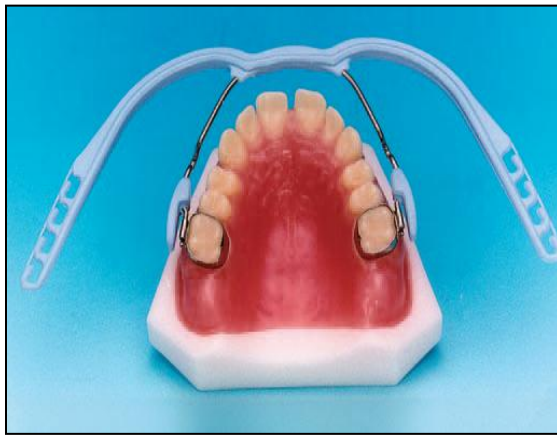The main problems with headgear safety relate to the prongs at the end of the facebow that fit into the headgear tubes on the intraoral appliance. It is possible for the bow to become dislodged, either because it is pulled out of the mouth or when the patient rolls over when they are asleep. The recoil effect from the elastics can damage the teeth, oral mucosa, soft tissues of the face and most seriously, the eyes. In order to minimize these problems various safety devices have been suggested. These involve re-curving the distal end of the wire (Figure 6), Nitom locking spring (Figure 7), using plastic coated face bows (Figure 8) and Samuels locking spring (Figure 9). Another popular method of preventing recoil is to fit a rigid safety strap, which prevents the bow from coming out of the mouth if it disengages from the tubes (Figure 10). In addition a variety of snap away face bows have been produced (Figure 11). If these are pulled beyond a preset distance, the neck strap comes apart and prevents any recoil injury. Eye injury is uncommon, but a serious risk and all available methods of reducing the risk of penetrating eye injury must be used. Every headgear and Kloehn bow must incorporate a safety feature. Failure to observe safety guidelines on the use of headgear is medico-legally indefensible<sup>[7]</sup>.



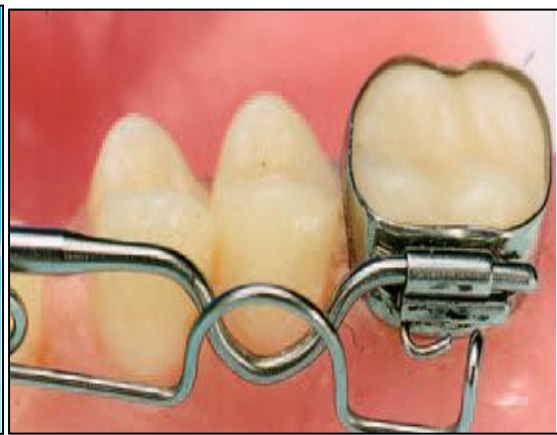**Figure 6:** Safety Kloehn bow showing recurved



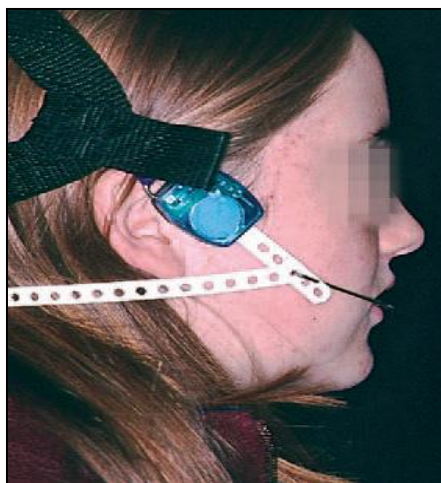**Figure 7:** Safety Kloehn bow with Nitomloops locking mechanism .



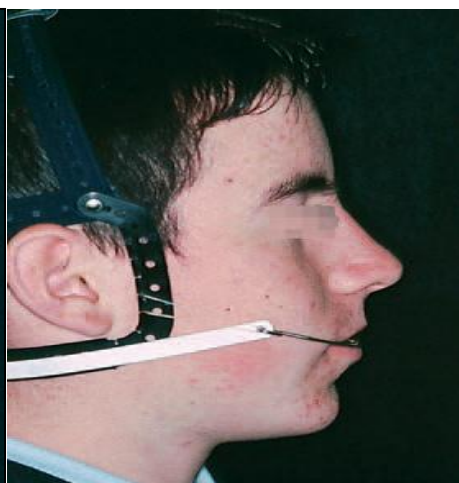**Figure 8:** Aplastic coated facebow together with a safety neck strap.



**Figure 9:** Samuels locking. This secures the face bow to the tube preventing accidental disengagement.



**Figure 10:** Interlandii headgear with arigid.masel safety strap.



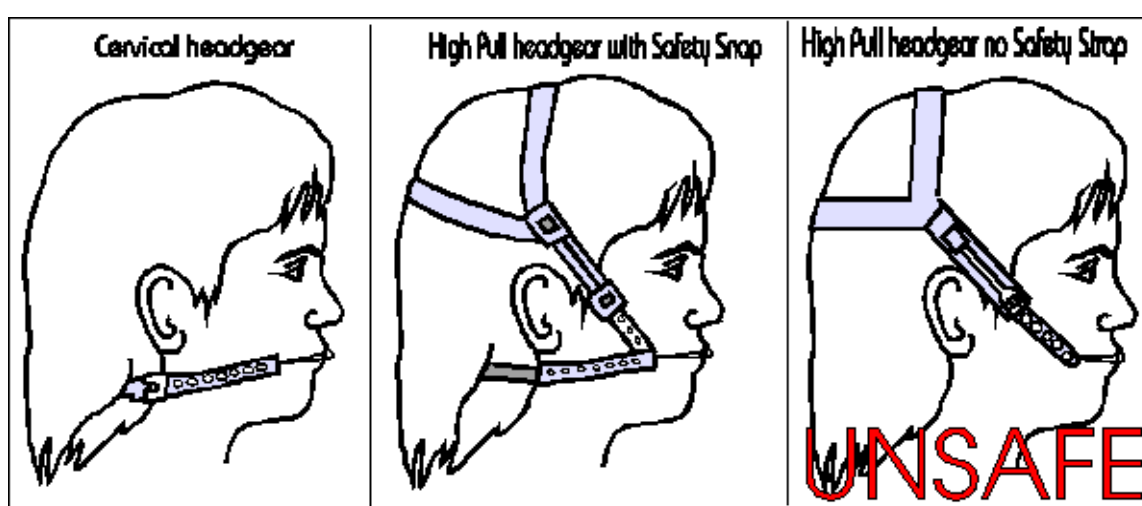
**Figure 11:** Quick release headgear attachment

Extra-oral traction should only be prescribed to those patients who are likely to comply with the orthodontists instructions. Written instructions should be issued to all patients and parents to take away with them. These instructions should include the following details:

- Patients should be advised never to wear their headgear during playful activity.



- Should another individual grab their facebow, the patient should also take hold of it until the other person has released their hold. They should then dismantle the headcap and/or neckstrap, and facebow to check that nothing has been broken.
- Always fit the locking facebow first. Once the facebow is in position then the self-releasing headcap/neckstrap may be fitted, whilst holding on to the facebow, to the prescribed tension as shown by the orthodontist.
- If the head cap/neck strap /facedown ever comes off at night or there are any other problems, the patient should stop wearing the appliance, and return to see the clinician as soon as possible.
- If the patient experiences a problem unlocking or removing the face bow, excessive force should not be used to remove it.
- Before removing the facedown the patient must first remove the head cap/neck strap.
- The patient and parent should also be advised that, if in the rare and unlikely event, they suspect that part of the head cap/neck strap/face bow might have caused injury to the eye, then the eye should be examined without delay. A warning should be given that failure to comply with the instructions may result in injury <sup>[20,21]</sup>.



#### IV. Functional appliances

Functional appliance can be defined as the appliance that changes the posture of the mandible, holding it open or open and forward <sup>[1, 22]</sup>.

It is designed to position the mandible downward and forward to stimulate or accelerate mandibular growth. According to profit functional appliance can alter the position of the mandible <sup>[2]</sup>.

Functional appliances are conceptually based on Moss' functional matrix theory.

Functional matrix theory proposes that functional matrices, tissues like muscles and glands influence skeletal units such as jaw bones and ultimately control their growth.

Norman Kingsley 1879 was the first orthodontist that developed the first appliance to position the mandible forward in United States of America. However, most consider Pierre Robin to have developed the earliest removable functional appliance, the monobloc; in France 1902 he used it to treat his patients with Pierre Robin syndrome.

Later in Berlin 1905 at the international dental congress Emil Herbst introduced a fixed pin and tube appliance to posture the mandible forward. After that in Denmark in 1908 viggo Andreasen introduced the activator functional appliance and later modified in Norway by his colleague, Karl Haupl. More recent innovation in functional appliance design a functional corrector or functional regulator was developed by Rolf Frankel in Germany in 1966. After that, until now countless modifications of removable functional appliances were introduced. All of these appliances postured the mandible downward and forward with the intent that the muscle and soft tissue pressure attempting to reposition the jaw back to its original position would modify jaw growth to correct the class II skeletal problem <sup>[4]</sup>.

INDICATION: in theory functional appliances stimulate and enhance mandibular growth, while headgear retards maxillary growth so roughly we can say functional appliances is the choice to treat mandibular deficiency, and head gear to treat maxillary excess <sup>[1]</sup>.

The primary indication to use functional appliances is mandibular skeletal retrusion and an abnormal muscular function. So we have to keep it in mind that functional appliances remove abnormal and restrictive muscular activity that prevent the normal development of the maxilla and mandible as well as appropriate

development of dental arches<sup>[5]</sup>.

According to Bishara the ideal indication for the use of the appliance in the correction of skeletal class II malocclusions “with active growth potential” is mandibular deficiency with normal maxillary development and in patients that have normal or mildly decreased face height since most of these appliances encouraged mandibular posterior dental eruption. Also to counter the dentoalveolar expected effect of the functional appliance use it is recommended to treat patient with slightly protrusive maxillary incisors and retrusive mandibular incisors<sup>[2,22]</sup>.

#### **4.1 Functional appliance components**

##### **4.1.1 Functional components**

- Lingual pad or flanges: it contact with mucosa and it is the most effective.
- Lip pads: it contact with mucosa but less effective.
- Buccal and lingual shields: it is tooth controlling component .it is passive and effective.
- Occlusal or incisal tooth controlling component stops it prevent eruption in discrete area
- Sliding pin and tube it contact with teeth and cause variable tooth movement.
- Facets or flutes
- Displacing springs

##### **4.1.2 Active components**

- Labial bow
- Headgear tube
- Torquing springs
- Expansions screw and spring<sup>[1]</sup>.

#### **4.2 Functional appliances types**

There are three main kinds of functional appliances: tissue borne appliances , passive tooth borne appliances which are commonly used and the third kind active tooth borne appliances which are not used nowadays in modern orthodontics.

##### **4.2.1 Tissue borne appliances**

###### **Frankel II Functional regulator**

It is the only example of tissue borne appliance. It consists of vestibular shields and lower labial pad against the labial mucosa beneath the lower incisors. It prevent labial and buccal musculature pressure to restrict dental and skeletal development also its buccal shield cause lateral expansion of both upper and lower arches because cheek pressure is removed. In addition to that its vestibular shields cause tension on the alveolar periosteum which stimulate mandibular repositioning<sup>[1, 2, 5, and 23]</sup>.

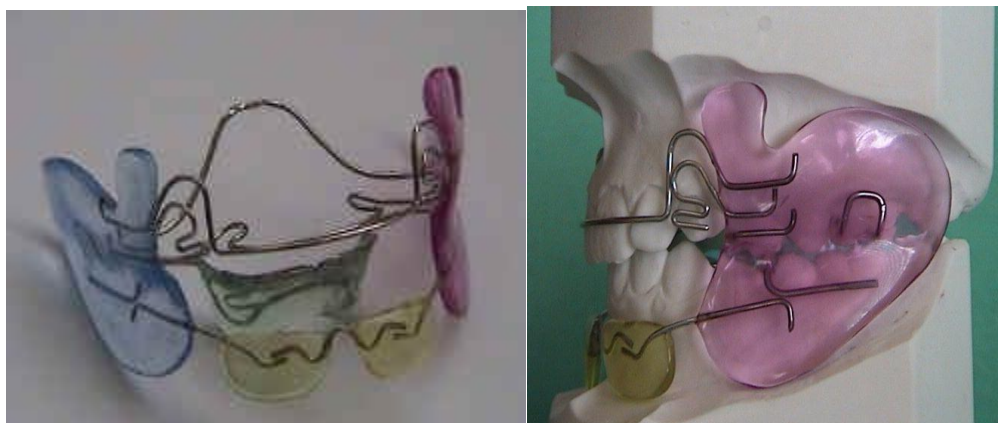
Mechanism of action: it is used as an exercise device in restraining the associated musculature and indirectly producing changes in skeletal and dentoalveolar relationship by reprogramming the CNS. It interrupts abnormal patterns of muscle activity and ultimately produces an environment in which skeletal and dental arch changes occurs such as increase in mandibular length also increase in transverse dimensions of dental arches. It is the appliance of choice in the treatment of patients with severe neuromuscular imbalances and skeletal discrepancies<sup>[4, 23]</sup>.

###### **Frankel II Effects**

Frankel II functional regulator appliance can produce maximum skeletal changes achieved with minimal unwanted tooth movement. The protecting effect of vestibular shield on dentition cause spontaneous expansion in both arches occurs. In addition to that frankelII can optimize the development of the orofacial structures, in part, by “removing restrictions or retarding in the accomplishment of growth pattern<sup>[1,2]</sup>”.

In the Anteroposterior dimension it has no or minor effect on maxillary skeletal position but has more effect on the Maxillary dentoalveolar position causing slight horizontal molar movement. In the molar vertical movement usually it is unaffected.

Frankel II cause lower incisors proclination (freed from behind the lower lip) Mandibular skeletal position; Pogmoves forward, mandibular growth, increase in posterior facial height and Y-axis closed – more horizontal vector of growth. In the Vertical dimensions increase in lower anterior facial height while in Transverse dimensions there is average in expansion of dental arches: in maxilla 4-5mm and in mandible 3-4mm<sup>[1,2,4]</sup>.



**Figure 12:** Frankel II functional appliances

#### **4.2.2 Passive tooth borne appliances**

Which use the dentitions as the primary anchorage. Passive tooth-borne appliances can be removable or fixed.

Removable appliances examples are Activator, Boater and Twin Block.

Fixed appliances examples are Herbst, fixed twin block and MARA. It causes full-time active forward positioning of the mandible and its dentoalveolar effect is greater than the skeletal effect.

#### **Twin block**

It was developed by Clark in 1977, can be removable or fixed. It consists of two components, an upper and lower unattached plate that fit tightly against the teeth, alveolus and supporting structure. The upper and lower appliances have 2 bite blocks, which gives the appliance its name: twin block. Twin block postures the lower jaw forward and encourages it to grow to its fullest potential. It has no direct effect on musculature. The upper and (sometimes lower) plate may also have an expansion screw to widen the upper arch causing expansion or a sagittal screw to cause retroclination of the max incisors when needed. The upper bite block is located posteriorly covering the molars, extending partially to the 2<sup>nd</sup> bicuspid and the lower bite block is located anteriorly usually covering the bicuspid. The inclined planes of the posterior bite blocks are oriented at 70 degrees to the occlusal plane to initiate functional shift of the mandible and to open the closed bite<sup>[1,2]</sup>.

Treatment effects of twin block:

Forward growth repositioning of the mandible, inhibition in maxillary growth, increase anterior and posterior facial height, distalization of max molars, extrusion of mandibular molars and tipping of anterior incisors (proclination of the mandible and retrusion of the maxilla)<sup>[24]</sup>.

Advantages of twin block:

Patients can wear twin block 24 hours a day and can eat comfortably with the appliance in place. It can be designed with no visible anterior wires without losing its efficiency in the correction of arch relationship. There is less interference with normal function because the mandible can move freely in anterior and lateral excursion without being restricted by bulky one-piece appliance. Patient's speech is normal as tongue movement is not restricted, as well as patient appearance and profile is noticeably improved immediately which is an excellent patient motivator.

Twin blocks may be fixed to the teeth temporarily or permanently to guarantee patient compliance. Removable twin blocks can be fixed in the mouth for the first week or 10 days of treatment to ensure the patient adapts fully to wearing them 24 hours per day. One of the added advantages of twin block is its versatility in being able to correct transverse discrepancy by incorporating midline jackscrew since a deficiency in the transverse plane is often encountered with a skeletal class II. The main advantage of twin blocks therapy is easy adaptation for the patient and ease to manipulate the vertical dimension. So it causes three-dimensional control. The twin block appliance due to its acceptability, adaptability, versatility, efficiency and ease of incremental mandibular advancement without changing the appliance has become one of the most widely used functional appliances in the correction of class II malocclusion.

Twin block is perceived by most clinicians to be easier to manipulate than Frankel III, and class II correction can be achieved readily within a 6 to 9 month period<sup>[1,2,4,25]</sup>.



**Figure 13: Twin block.**

### **Herbst appliance**

Original banded design was introduced by Herbst at the International Dental Congress in Berlin 1905 German. Popularity diminished after that until it was reintroduced by Pancherz 1979. It was one of the early attempts to produce mechanically jumping of the bite. It consists of two rigid maxillary and mandibular cast metal skeleton or acrylic cemented from maxillary first molar to mandibular canines. It is fixed so cannot be removed by the patient works 24 hours per day but can be removable also.

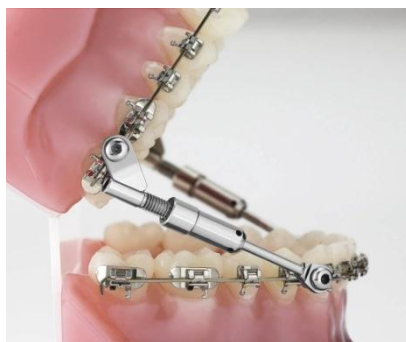Its skeletal effect is minimal. It inhibits mid facial length<sup>[4]</sup>. So they believe that it causes dental effect more than skeletal.

Its dental effects: at the maxilla it causes upward and backward vector of force, molar distalization and intrusion and distal crown tipping, Herbst treatment effect on the upper incisors remains unchanged. At the mandible it causes mesial movement and extrusion of molars and proclination and intrusion of lower incisors.

The advantages of Herbst: since it is fixed to the teeth so less or no cooperation from the patient is required. Since it works 24 hours a day so the treatment time will be relatively shorter than the other appliances.

Its disadvantages: is ease of breakage and less durable. Herbst keeps the mandible continuously in a protruded position, both on jaw closure and when the teeth are not in occlusion<sup>[26]</sup>.

The crown Herbst appliance produces greater proclination of lower incisors than acrylic splint Herbst appliance. Practitioners experience revealed treatment time usually short (about 6 to 8 months). Herbst appliance is criticized that it causes dental effect more than skeletal effect, this is especially if the patient does not cooperate by forcing his mandible forward not just do it passively.<sup>[1,2,4]</sup>



**Figure 14: Herbst appliance.**

## **4.3 Effects of functional appliances**

### **4.3.1 Skeletal effects of functional appliances**

Functional appliances stimulate growth of the mandible as some literature believes others believed it just causes acceleration of the mandibular growth. It causes also restriction of the growth of the maxilla. Functional appliances alter muscle tension or reduced condylar tissue pressure on the condyle leading the mandibular condyle out of the fossa which causes additional growth (remodeling of the glenoid fossa more anteriorly). The effect on the maxilla is small however it is observed that it restrains maxillary growth<sup>[1,2]</sup>. The anteroposterior effects on the maxilla were similar upon a clinical trial at Florida: Although functional appliances effect on the mandible is great but there is some restraint effect on the maxilla as well. Using Herbst appliances, Pancherz noted substantial rebound in the immediate post treatment effect. He recommended Herbst appliances to be used in the early mixed dentition, where he found the changes more localized to the protrusion of the mandible. Upon prospective data on Herbst appliance it showed limited skeletal effect. It causes more skeletal effect if used in the early permanent dentition. Twin block upon prospective data demonstrates limited effect on maxilla and small effect on increased mandibular length but significant. There is a claim that some downward and forward remodeling of the glenoid fossa might occur<sup>[1,27]</sup>.



#### **4.3.2 Dentoalveolar effects of functional appliances**

The dental effect of functional appliances is greater than head gear. Functional appliance has no mechanism for aligning irregular arches. Functional appliances cause retroclination of upper incisors and greater effect in proclination of lower incisors<sup>1,2</sup>. In fixed appliances like fixed twin block or Herbst the dental effect is much more because of the continuous force applied moreover Herbst cause posterior dental intrusion.

Functional appliances can be helpful in leveling curve of spee by extrusion of lower posterior teeth and inhibit lower incisors from erupting. Also functional appliances lead to treat class II cases by forward movement of teeth and rotation of the occlusal plane as a result of preventing upper posterior from erupting and moving mesially in the same time forcing lower posterior teeth to erupt and move forward.

Siqueira et al compared changes in the dentoskeletal and soft tissues after orthodontic treatment of Class II Division 1 malocclusions between the cervical headgear and the mandibular protraction appliance followed by fixed appliances. He found that cervical headgear corrected the Class II malocclusion primarily through greater action on the maxillary skeletal and dentoalveolar structures( restriction of the anterior displacement of the maxilla, improvement of the skeletal Class II relationship, decreased facial convexity )as compared with mandibular protraction appliance which corrected the malocclusion through greater action on the mandibular dentoalveolar structures<sup>[18, 27,28]</sup>.

#### **4.4 Clinical procedures using functional appliances**

When we decide to treat patient with functional appliance the patient must be in the active growth potential. This stage occurs in the mixed dentition.

There are four major situations that require preliminary orthodontic treatment<sup>[5]</sup>:

- 1- Severe maxillary constriction: we could expand the maxilla by rapid palatal expansion.
- 2- Deep impinging bite: to allow forward posturing of the mandible, it could be corrected by using a utility arch to intrude, tip, or reposition the incisors.
- 3- Maxillary incisor retroclination and mandibular incisor proclination and spacing ;over 30 %of class II patients present with retruded maxillary incisors so it must be corrected to allow appropriate mandibular advancement. In addition to that flaring and spacing in the lower incisors must be corrected to allow for maximum mandibular advancement.
- 4- Moderate to severe crowding cases; space supervision or serial extraction may be required depending on the severity of the upper and lower dental crowding<sup>[5, 29]</sup>.

After that we start making the bite registration. Well-extended upper and lower impressions are needed together with a working bite. The exact nature of the bite depends on the type of functional appliance to be used, but all of them require the mandible to be postured forward. The upper and lower centerlines should be coincident, and a degree of opening is usually necessary, with the exact amount depending upon the over-bite and design of appliance to be used.

During taking the bite registration we have to keep in mind which appliance will be used and if there is asymmetry to be corrected.

If Herbst appliance will be used bands or steel crown must be transferred to the impression before pouring the cast. If buccal shields and lingual pads will be used we should not overextend the impression to prevent soft tissue displace.

Factors to be considered while construction of the bite registration<sup>[2]</sup>:

- 1-Waxbite must be warmed to softness permit imprint all the posterior teeth .Wax should not cover the retro molar that may exaggerate the vertical opening in this area.
- 2-The downward and forward mandibular positioning must be predetermined according to the appliance design and patient tolerance. It is around 4-6 mm that will be tolerated by the patient and will not require frequent remaking. Downward positioning is usually 3-4 mm but if the patient has excessive vertical face height 5-6 mm total opening in the molar area (2-3 mm past the resting vertical position) so that soft tissue stretch against the bite block will produce continuous force opposing eruption.
- 3-Mandible must be symmetrically advanced unless there is asymmetry we need to correct it.
- 4-patient should be directed to practice the working bite position. Before delivering the functional appliance to the patient we check it on the cast if it fit correctly.

The recommended time to wear the functional appliance is like head gear during evenings and sleep 12 to 16 hours. This will give us skeletal effect more than dental effect<sup>[1,2]</sup>.

To decrease the initial discomfort of wearing the appliance we ask the patient to wear the appliance gradually until the required time. Patient should be given appointment after 1 to 2 weeks to check for any sore spots or any other complaints.

Usually after 6-12 to months we observe good positive change and after 8 months wearing period we can judge if we need further advancing of the mandible forward or even adjusting the vertical positioning<sup>[2]</sup>.

Patient compliance and motivation: Compliance while wearing the appliance is essential to get early overjet

reduction and it is achieved in three ways

- 1- By carefully explaining the treatment details to the child and parents to motivate them.
- 2- By ensuring the advantages of the appliance.
- 3- By scheduling at least 15 minutes in each visit and not squeezing in appointments because it is a removable appliance<sup>[30]</sup>.

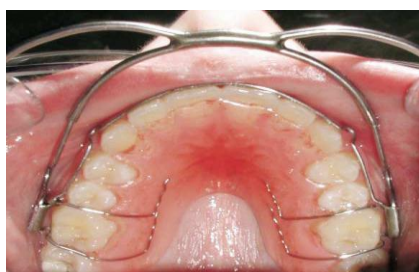#### **V. Retention and relapse after using head gear or functional appliance**

We have to keep in our mind three important things when we want to stop the treatment with headgear or functional appliance. First the age of the patient how long still he has from his active growth period. Second before we stop the treatment to achieve overcorrection to maintain the results we got and to counter affect any slight relapse. Third point is not to forget to consider when are we planning to start the phase two treatment or weather we will not do phase two treatments as in some cases<sup>[51]</sup>. It is a rule after any orthodontic treatment we have to stop it gradually to maintain what we gain, here also in head gear and functional appliance we have to stop it gradually by decreasing the time we ask the patient to wear before<sup>[1,2, and 31]</sup>.

A clinical study on 8-year-old children conducted by Wieslander that involved headgear use and the Herbst appliance showed relapse in the mandible but stable results in the maxilla. This indicated that orthopedic effects from headgear could be maintained<sup>[32]</sup>. The occlusion established early may not change despite the differential growth of the jaws. People can have greater mandibular growth than maxillary or vice versa, but the occlusion can be maintained. As such, the authors believe it is important to correct Class II Division 1 malocclusions early and maintain the Class I. If used in the early transitional dentition, it is advisable to use the headgear to retain the achieved result till the rest of the permanent teeth erupt. The same applied for functional appliance<sup>[1]</sup>. The phenomenon of the patient's fundamental growth pattern re-expressing itself following cessation of orthopedic treatment must be considered when determining the endpoint for headgear wear. Two treatment recommendations that can minimize this problem are the inclusion of overcorrection and the continuance of some degree of orthopedic treatment until maxillary growth is complete. When adequate overcorrection is present, it is advisable to discontinue the headgear or functional appliance wear incrementally while monitoring the occlusion<sup>[33]</sup>.

In some cases of maxillary excess continued growth after initial orthopedic treatment may require the nightly use of headgear until completion of adolescent growth<sup>[2, 34]</sup>.

For the headgear an alternative way a retention appliance with tubes added on to the Adams cribs for insertion of a face bow for extraoral traction will ensure combined dental and orthopedic retention (Figure 15). The Hawley is worn full-time and the extraoral force is added at night with a force of about 500 gm per side. Orthopedic retention may be instituted at night for as long as 2 to 5 years. Retention is even more important in those patients who have not achieved a solid Class I molar relationship during phase 1. Full-time wear of a retention appliance with nighttime wear of a headgear attached to the appliance may yield better retention results. It may be prudent to continue with orthopedic forces until after at least 2 to 3 years after peak height velocity (PHV), approximately age 14 to 15 years for most girls and age 16 to 17 years for most boys<sup>[35]</sup>.



**Figure 15:** The removable retainer incorporates headgear Tubes attached to the Adam's clasps on the upper molars to facilitate insertion of the facebow

#### **VI. Controversy and discussion**

As we know the prevalence of class II is high .and it is most often associated with skeletal jaw discrepancies either mandibular deficiency or maxillary excess or both. Functional appliances have become part of contemporary orthodontic practice, however, their mode of action is still controversial. The ability of functional appliances to reduce overjets by means of modifying dental relationships (incisor angulation and position) is not in dispute. The controversy surrounds the ability of the appliances to increase mandibular growth, and thus result in a long-term change in the skeletal pattern<sup>[36]</sup>. If we do not take the advantage of the growth modification potential in the growing patient we have the other last two treatment options which are dental camouflage or orthognathicsurgery. It is obviously clear that there is a lot of controversy about the best

optimal time of treatment and the efficacy of the various growth modification appliances used, we can understand now that if we choose the proper time we obtain more skeletal growth modification. There is also a lot of controversy about which appliance to use and the real effect. The reason of that could be because the current methods for distinguishing between growth and treatment changes is based on conventional cephalometrics which has many limitations and sometimes lead to errors as large as the differences to be detected. We have to emphasize that it is because lack of proper research and statistics, also one of the problems that cephalometric measurement we cannot fully depend on it because as an example point B will not move just anterior posterior but also vertically. Recently the invention of the new 3 dimensional x-ray could help us in the future researches to measure properly the effect of all the appliances and to avoid any errors. A number of studies have looked into the possibility of modifying growth with orthopedic appliances. Some retrospective studies demonstrated some average modest increase in mandibular growth (2 to 4) mm per year during treatment with functional appliances other investigators, however, did not consider the effect of functional appliances on quantitative lengthening of the mandible to be clinically significant<sup>[11]</sup>. Kloeber stated that the cervical headgear therapy with an elevated external bow and an expanded inner bow is a very useful appliance in correcting skeletal Class II in the late mixed –early permanent dentition because of the potential to displace the entire maxilla posteriorly, down and back, on the cranial base and to give a vastly improved anteroposterior jaw and dental relationship in the skeletal Class II patient<sup>[10]</sup>.

Proffit state: Although skeletal change without dental movement is usually desired when using the headgear for orthopedic purposes, it is not possible for a tooth-borne appliance to selectively alter skeletal relationships without dental change<sup>[2, 37]</sup>.

A study to evaluate the treatment changes associated with the bionator and the removable headgear splint, revealed that both effectively corrected the molar relationships and overjet of Class II patients primarily by dentoalveolar changes, the bionator showed significantly greater amount of anterior mandibular displacement than the removable headgear splint group, and there was greater maxillary molar distalization in the removable headgear splint group than in the bionator group<sup>[38]</sup>.

Ghafari et al found that both the headgear and function regulator are effective in correcting the Class II, Division 1 malocclusion of prepubertal children. The common mode of action of these appliances is the possibility to generate differential growth between the jaws. Activator and high-pull headgear combination treatment in growing patients resulted in a correction of the skeletal Class II relationship, a restriction of maxillary growth, an advancement of the mandibular structures, an increase in lower face height, a correction of the overjet, an improvement in overbite, up righting of the maxillary incisors, protrusion of the mandibular incisors, and a correction of the dental Class II malocclusion. An intrusive and distal force can be applied to all the erupted maxillary teeth if a standard facebow is attached directly to a maxillary acrylic splint or a functional appliance<sup>[2, 39]</sup>.

Proffit state that functional appliance could just accelerate the growth. But whether acceleration or improvement happen we have to consider the benefit of improving the patient psychology and self-esteem. Many studies believe that manipulating the maxilla which is spongier with a lot of bone sutures I compare with the compact bone mandible is easier so they prefer using the headgear<sup>40</sup>. In general as we can see headgear will restrict maxilla while functional appliances will enhance the mandible. All of this is in anteroposterior plane but we work in orthodontics in three planes, So what about the vertical plane? Growth modification could not just ease phase 2 treatment but also will help in the open bite and deep bite cases...Proffit suggest methods of treatment by combining the interaction of vertical and horizontal plane in treatment plan according to that<sup>[11]</sup>:

A) In the case of short face skeletal deep bite class II:

Here our objective will be to inhibit eruption of incisors teeth, control and facilitate eruption of the lower posterior teeth.

So the goal is to increase face height and correct deep bite while allowing more eruption of lower than upper so occlusal plane rotates up posteriorly

This can be treated by functional appliance, like activator -bionator or Herbst as a fixed appliance.

B) In the case of class II children with normal face height:

Here both head gear and functional appliances can be used. Straight pull or high pull head gear can be used if we want to reduce elongation of maxillary molars and to control mandibular plane.

C) In the case of long face skeletal open bite class II:

The most effective treatment is the combination of headgear and functional appliances. But we need a lot of cooperation from the patient. Another alternative way is to use interocclusal bite blocks with functional appliance.

## VII. Conclusion

Nowadays the awareness of the patients of dental treatment in general and orthodontic treatment specially has increased. Here we are trying not just to treat teeth only, we are trying to improve the facial profile taking the advantage of the growth potentials of the children, what kind of orthopedic appliances we should use? This depends on the understanding every appliance its working mechanism, the patient skeletal and dental condition we want to treat and the compliance of the patient.

## References

- [1]. Proffit W. Contemporary Orthodontics. Mosby, fourth edition.
- [2]. Bishara S. TEXTBOOK OF ORTHODONTICS. Saunders Company. 336-343,218-220.
- [3]. Nanda R, Dandajena T. The Role of the Headgear in Growth Modification. *SeminOrthod* 2006;12:25-33.
- [4]. James A McNamara Jr, William L Brudon. Orthodontics and Dentofacial Orthopedics .needham press 2001
- [5]. jeryl d english, timopeltomaki, katepham-litschel. ORTHODONTIC REVIEW. mosby 2009
- [6]. R.G. Wick Alexander, the 20 principles of the alexander discipline, quintessence publishing co, inc 2007 010518
- [7]. Roberts-Harry D, Sandy J. A clinical guide to orthodontics. *British Dental Journal* 2003; 258-261, 75-76
- [8]. Bowden D. Literature review. *BJO* 1978; 5
- [9]. Kim K, Muhl Z. Changes in mandibular growth direction during and after cervical headgear treatment. *Am J OrthodDentofacialOrthop* 2001;119:522-30.
- [10]. Filho R, Lima A, Ruellas A. Longitudinal Study of Anteroposterior and Vertical Maxillary Changes in Skeletal Class II Patients Treated with Kloehn Cervical Headgear. *Angle Orthod* 2003;73:187-193.
- [11]. Filho R, Lima A, Ruellas A. Mandibular changes in skeletal Class II patients treated with Kloehn cervical headgear. *Am J OrthodDentofacialOrthop* 2003;124:83-90
- [12]. Virkkula T, Kantomaa T, Julku J, Pirttiniemi J. Long-term soft-tissue response to orthodontic treatment with early cervical headgear—a randomized study. *Am J OrthodDentofacialOrthop* 2009;135:586-96.
- [13]. Tulloch J, Phillips C, Koch G, Proffit W. The effect of early intervention on skeletal pattern in Class II malocclusion: a randomized clinical trial. *Am J OrthodDentofacialOrthop* 1997;111:391-400.
- [14]. Mantysaari R, Kantomaa T, Pirttiniemi P, Pykalanin A. The effects of early headgear treatment on dental arches and craniofacial morphology: a report of a 2 year randomized study. *European journal of orthodontics* 2004; 26: 59-64.
- [15]. Sloss E, Southard K, Qian F, Stock S, Mann K, Meyer D, Southard T. Comparison of soft-tissue profiles after treatment with headgear or Herbst appliance. *Am J OrthodDentofacialOrthop* 2008;133:509-14.
- [16]. Ghafari J, Shofer S, Jacobsson-Hunt U, Markowitz D, Lasterb L. Headgear versus function regulator in the early treatment of Class II, Division 1 malocclusion: A randomized clinical trial *Am J OrthodDentofacialOrthop* 1998;113:51-61.
- [17]. Graber T. Orthodontic appliances and treatment philosophy. In: orthodontics, principles and practice, 2<sup>nd</sup> edition, Saunders, Philadelphia. 529-610.
- [18]. Siqueira D, Almeida A, Janson J, Brandão A, Filhoo C. Dentoskeletal and soft-tissue changes with cervical headgear and mandibular protraction appliance therapy in the treatment of Class II malocclusions. *Am J OrthodDentofacialOrthop* 2007;131:447.e21-447.
- [19]. Mars G Effects of activator and high-pull headgear combination therapy: skeletal, dentoalveolar, and soft tissue profile changes. *European Journal of Orthodontics* 2007; 29: 140-148.
- [20]. Samules R, Brezniak N. Orthodontic facebows: safety issues and current management. *Journal of Orthodontics* 2002; 29: 101-107.
- [21]. Cureton S, Regennitter F, Yancey J. Clinical versus quantitative assessment of headgear compliance. *Am J OrthodDentofacialOrthop* 1993; 104: 277-284
- [22]. Laura Mitchell. An Introduction to Orthodontics. oxford university press. 2<sup>nd</sup> edition 2001.
- [23]. Stanley Braun. The Effect of Frankel II and Modified Twin Block Appliances on the 'C'-axis: The Growth Vector of the Dentomaxillary Complex. *Angle Orthodontist*, Vol 74, No 6, 2004.
- [24]. William J. Clark. Twin Block Functional Therapy. Mosby. 2<sup>nd</sup> edition 2002.
- [25]. Clark, W. J. Twin block technique. A functional orthopedic appliance system. *American Journal of Orthodontics and Dentofacial Orthopedics*, 1988; 93, 1-18.
- [26]. Hans Pancherz, Sabine Ruf. The Herbst Appliance. Quintessence Publishing. 1<sup>st</sup> edition 2008.
- [27]. Tulloch J, Proffit W, Phillips C. Outcomes in a 2-phase randomized clinical trial of early Class II treatment. *Am J OrthodDentofacialOrthop* 2004;125:657-67.
- [28]. Thomas M. Graber, Thomas Rakoski, Alexandre G. Petrovic. Dentofacial Orthopedics with functional appliances. Mosby; 2 edition (May 1, 1997).
- [29]. Graber, vanarsdall, Vig. Orthodontics: Current Principles and Techniques .Mosby; 5 edition .May 18, 2011.
- [30]. Ravindra Nanda, Sunil Kapila. Current Therapy in Orthodontics. Mosby; 1 edition ,April 14, 2009.
- [31]. Ireland A, McDonald F. The orthodontic patient: treatment and biomechanics. Oxford Press 2003. 75-76.
- [32]. Wieslander L. Long-term effect of treatment with the headgear-Herbst appliance in the early mixed dentition. Stability or relapse? *Am J OrthodDentofacialOrthop* 1993; 104: 319-32
- [33]. Orton, H. S. Functional appliances in orthodontic treatment. Quintessence, London. 1990.
- [34]. Bishara S. Class II Malocclusions: Diagnostic and Clinical Considerations With and Without Treatment. *SeminOrthod* 2006;12:11-24.
- [35]. Wiltshire W, Tsang S. A Modern Rationale for Orthopedics and Orthopedic Retention. *SeminOrthod* 2006;12:60-66.
- [36]. A. R. Collett. Current concepts on functional appliances and mandibular growth stimulation. *Australian Dental Journal* 2000;45:(3)173-178.
- [37]. Darendeliler M. Validity of Randomized Clinical Trials in Evaluating the Outcome of Class II Treatment *SeminOrthod* 2006;12:67-79.
- [38]. Martins R, Martins J, Martins L, Buschang P. Skeletal and dental components of Class II correction with the bionator and removable headgear splint appliances. *Am J OrthodDentofacialOrthop* 2008;134:732-41.
- [39]. Isaacson, K. G., Reed, R. T., and Stephens, C. D. Functional orthodontic appliances. Blackwell, Oxford. 1990.
- [40]. Barton, S. and Cook, P. A.. Predicting functional appliance treatment outcome in Class II malocclusions — a review. *American Journal of Orthodontics and Dentofacial Orthopedics*, 1997;112, 282-6.