

## Interpretation of Macrocytes in Peripheral Blood Smears

Dr. Divya NS<sup>1</sup>, Dr. Sharat kumar B Jaikar<sup>2</sup>

<sup>1</sup>(Asst. Prof, Department Of Pathology, DM-WIMS Medical College, Wayanadu, Kerela)

<sup>2</sup>(Asst. Prof, Department Of Medicine, DM-WIMS Medical College, Wayanadu, Kerela)

---

**Abstract :** Background- 'Macrocytes' refers to larger erythrocytes with increased mean corpuscular volume (MCV) in routine blood smears. It can be either an incidental finding or may be associated with underlying disease.

Aim of the study- to identify the underlying cause for macrocytosis and also to analyse the haematological features of macrocytosis in routine haemogram and peripheral blood smear.

Results- out of 89 adult patients, alcoholism was the major etiological factor of macrocytosis, followed by Vitamin B12 deficiency and drug intake. Isolated macrocytosis without anaemia was seen in 20 cases. Peripheral smear examination revealed hypersegmented neutrophils and macro-ovalocytes predominantly in megaloblastic conditions.

Conclusions- Macrocytes on peripheral blood smears has to be evaluated even in absence of anaemia. Careful analysis of routine haemograms and peripheral blood smears assist in identifying the underlying cause for macrocytosis.

**Keywords:** Alcoholism, Macrocytes, Mean Corpuscular Volume (MCV), Megaloblastic Anaemia, Peripheral Blood Smear.

---

### I. Introduction

The term 'macrocytosis' refers to a condition in which red cell corpuscles are larger than the normal, which usually manifests as MCV more than 100 fl (normal adult range of MCV is 80-100 fl)<sup>[1]</sup>. The prevalence of macrocytosis varies between 1.7%- 3.6%<sup>[1,2]</sup>. Physiological macrocytic blood picture is commonly encountered during pregnancy, newborns and rarely as a normal variant in genetically predisposed individuals. Spurious macrocytosis is seen in conditions like reticulocytosis, hyperglycemia and delayed sample processing<sup>[3]</sup>. Macrocytosis has to be evaluated even in absence of anemia, as it may provide valuable information regarding the underlying pathology.

Aim of the study- to identify the underlying cause for macrocytosis and also to analyze the haematological features of macrocytosis in routine haemogram and peripheral blood smear in different etiologies.

### II. Methodology

This prospective study was conducted during 2012-2013, which included 100 patients. 11 of them lost the follow up; therefore only 89 patients were available for evaluation.

Inclusion criteria- adult patients with MCV >100 fl

Exclusion criteria- pregnant women, newborns and other cases of spurious macrocytosis

A detailed medical history especially on drug intake, diet and alcohol consumption was noted. Complete haemogram and peripheral blood smear examination was carried out in all cases. All patients were subjected to serum Vitamin B12 assay, serum folic acid assay, thyroid, liver and renal function tests. Bone marrow aspiration was done only when clinically indicated.

Based on haemoglobin (Hb) levels, cases were segregated as anemic macrocytosis and non- anemic macrocytosis (normal adult Hb levels: males- <13.2 g/dl; females- < 11.6 g/dl). Serum Vitamin B12 deficiency (<150 pmol/l) and serum folic acid deficiency (<10 nmol/l) were clearly defined<sup>[4]</sup>. After identifying the underlying causative factor, cases were categorized as megaloblastic and non- megaloblastic macrocytosis. Red cell parameters and peripheral blood smear findings were critically analyzed and compared between these two categories.

### III. Results

Out of 89 available patients for evaluation, underlying pathology was identified in 68 (76%) patients [Table 1]. Alcoholism was the most common cause of macrocytosis (36.5%) in the study group, followed by Vitamin B12 deficiency (24%). Drug induced macrocytosis was seen in 10 cases (11.2%) and commonly encountered drugs were reverse transcriptase inhibitors and anticonvulsants. In 10 patients, underlying cause

---

could not be ruled out. Anaemia was present in 69 cases and remaining 20 cases had isolated macrocytosis without anemia [Fig/ graph 1].

Based on haematological parameters and bone marrow evaluation, 21 cases of Vitamin B12/folate deficiency were categorized as megaloblastic macrocytosis and 32 cases of alcoholism, 8 cases of drug toxicity, 2 from hypothyroidism and 2 from liver disease were categorized as (total 44 cases) non- megaloblastic/normoblastic macrocytosis. Haematological parameters [Table2] and peripheral blood smear findings [Fig/graph 2] were documented and compared between megaloblastic and non- megaloblastic macrocytosis.

#### IV. Discussion

The MCV >100fl, is usually regarded as macrocytosis. However, this cut-off value is lower in children compared to adults [5].

The underlying mechanisms in the formation of macrocytes are diverse and complex. In nutritional deficiencies (Vitamin B12/ folic acid), nuclear maturation gets delayed whereas the haemoglobin synthesis proceeds normally, which affects the cell division resulting in larger erythrocytes i.e., macrocytes. The possible mechanism in formation of macrocytes in case of alcoholism is due to the direct toxic effect of ethanol on red cell membrane. Whereas in case of chronic liver disease and hypothyroidism, there will excessive deposition of lipids on red cell membrane [3,6]. In case of myelo-dysplastic syndrome (MDS), macrocytosis occurs as a consequence of dysplastic red cell precursors [3,6,7].

Many authors have reported that drug therapy and alcohol abuse as the most frequent cause for macrocytosis [8,9,10]. In developing nation like India, nutrition deficiencies [11] and alcoholism remains the major cause as in our study. We observed macrocytosis associated with anemia in 69 cases and without anemia in 20 cases. Isolated uniform macrocytes were commonly encountered in alcoholism [Fig 3]. Another significant observation in our study is that, 5 cases of Vitamin B12 deficiency had isolated macrocytosis which emphasizes the fact that macrocytes can be an early diagnostic harbinger.

The average value of MCV can be masked by co-existing microcytic anemia [12], therefore peripheral blood smear examination becomes mandatory. In alcoholism, MCV ranges between 100-110 fl whereas in Vitamin B12/ folate deficiency it is much higher [6]. We noted similar findings in our study. The mean red cell distribution width (RDW) was significantly higher in megaloblastic conditions when compared to normoblastic conditions which were similar to the observations made by Gupta et al [13] and Seppa et al [5]. Macro- ovalocytes and hypersegmented neutrophils are predominantly seen in megaloblastic conditions and is usually associated with increased RDW [1,14]. In non- megaloblastic conditions uniform macrocytes are seen with normal RDW [3,12,15]. In present study, uniform macrocytosis was seen in alcoholism and chronic liver disease. Macro-ovalocytes, moderate degree of anisocytosis and hypersegmented neutrophils were seen in Vitamin B12 deficiency [Fig 4].

Elevated MCV is a useful but not a specific parameter to assess macrocytosis. However, it directs the further investigations which ultimately lead to a definite diagnosis [10]. Unexplained macrocytosis in elderly patients could be an early indicator of malignancy or MDS [10,16]. Therefore, close attention has to be paid while evaluating MCV.

#### V. Conclusion

Elevated MCV needs to be thoroughly investigated even in the absence of anemia, as may be the early indicator of underlying pathology. In a resource limited country like India, peripheral blood smear examination is a simple inexpensive yet a valuable tool which assist in evaluating macrocytosis and guide the further management.

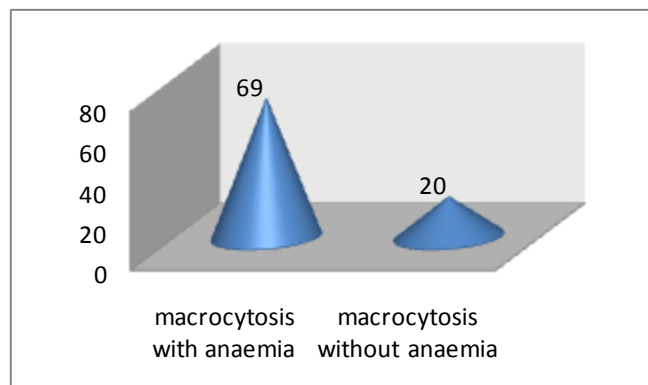
#### VI. Figures And Tables

**Table 1- Various Etiological Factors Identified In Macrocytosis**

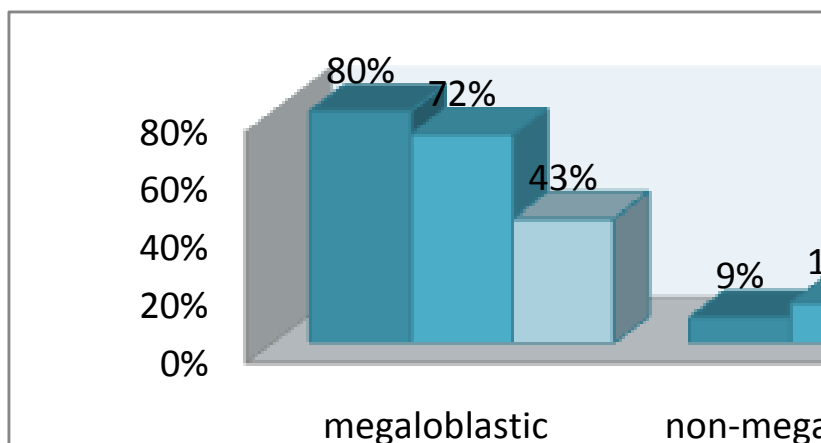
SL NO	UNDERLYING FACTOR	NO. OF CASES
1	VITAMIN B12 DEFICIENCY	21
2	ALCOHOLISM	32
3	OTHERS INCLUDE:	36
	1) FOLATE DEFICIENCY	4
	2) DRUG INDUCED	10
	3) CHRONIC LIVER DISEASE	4
	4) CHRONIC RENAL FAILURE	4
	5) HYPOTHYROIDISM	2
	6) MDS	1
	7) APLASTIC ANAEMIA	1
	8) UNEXPLAINED/ ? COMBINED DEFICIENCY	10
	<b>TOTAL</b>	<b>89</b>

**Table 2- Red Cell Parameters in Megaloblastic & Non- Megaloblastic Macrocytosis**

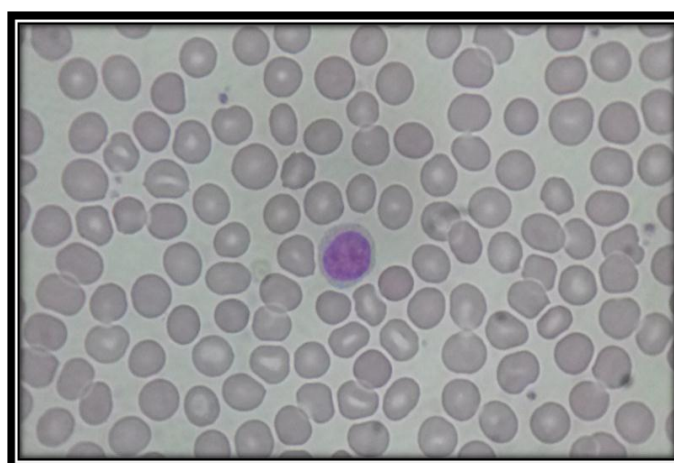
PARAMETER	Megaloblastic Category (21 Cases)	Non-Megaloblastic Category (44 Cases)
Hb g/dl	8.8 (2- 14.5)	12.6 (8.7- 16.2)
MCV fl	111.8 (100.5- 146.8)	107.8 (100.3-114)
RDW- CV % $\times 10^{12}/l$	21.6 (12.7- 46.4)	13.7 (12.3-28.4)



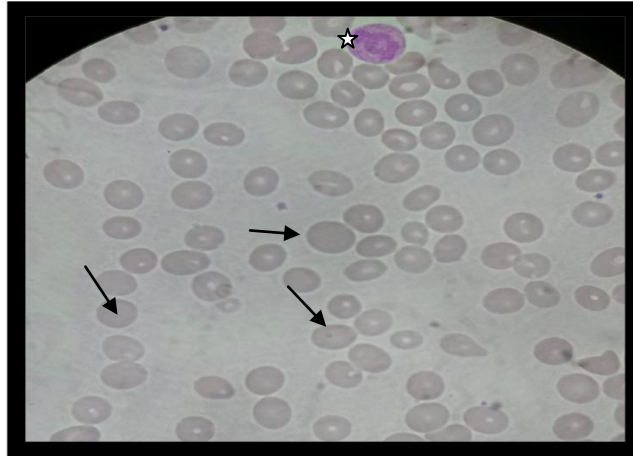
**Fig/ graph 1- showing association of macrocytes with anaemia**



**Fig/ graph 2- showing peripheral blood smear findings in megaloblastic & non-megaloblastic macrocytosis**



**Fig 3- photomicrograph of peripheral blood smear showing uniform macrocytes in a case of alcoholism**



**Fig 4- photomicrograph of peripheral blood smear showing macro-ovalocytes (arrows), anisocytosis, hypersegmented neutrophil [\*] at the top in a case of vitamin B12 deficiency**

### References

- [1] Aslinia F, Mazza JJ, Yale SH, Megaloblastic anemia and other causes of macrocytosis, *Clin Med Res*, 4(3), 2006, 236–241.
- [2] Hoffbrand V, Provan D, ABC of clinical haematology- Macrocytic anaemias, *BMJ*, 314(8), 1997, 430–433.
- [3] Kaferle J, Strzoda CE, Evaluation of macrocytosis, *Am Fam Physician*, 79(3), 2009, 203–208.
- [4] Lee GR, Foerster J, Lukens J, Paraskevas F, Greer JP, Rodgers GM, *Wintrobe's clinical hematology*, Williams and Wilkins, Baltimore, 1998.
- [5] Seppä K, Heinilä K, Sillanaukee P, Saarni M, Evaluation of macrocytosis by general practitioners, *J Stud Alcohol*, 57, 1996, 97–100.
- [6] Davidson RJ, Hamilton PJ (1978) High mean red cell volume: its incidence and significance in routine haematology, *J Clin Pathol*, 31, 1978, 493–498.
- [7] Wallerstein RO Jr, Laboratory evaluation of anemia, *West J Med*, 146, 1987, 443–451.
- [8] Savage DG, Ogundipe A, Allen RH, Stabler SP, Lindenbaum J, Etiology and diagnostic evaluation of macrocytosis, *Am J Med Sci*, 319(6), 2000, 343–352.
- [9] Keenan WF Jr (1989) Macrocytosis as an indicator of human disease, *J Am Board Fam Pract*, 2(4), 1989, 252–256.
- [10] Mahmoud MY, Lugon M, Anderson CC, Unexplained macrocytosis in elderly patients, *Age Ageing*, 25, 1996, 310–312.
- [11] Breedveld FC, Bieger R, van Wermeskerken RK, The clinical significance of macrocytosis, *Acta Med Scand*, 209(4), 1981, 319–322.
- [12] Sarma RP, Red cell indices, Walker HK, Hall WD, Hurst JW, *Clinical methods: the history, physical, and laboratory examinations*, 3rd ed, Butterworths, Boston, 1990, 720–723.
- [13] Gupta PK, Saxena R, Karan AS, Choudhry VP, Red cell indices for distinguishing macrocytosis of aplastic anaemia and megaloblastic anaemia, *Indian J Pathol Microbiol*, 46(3), 2003, 375–377.
- [14] Lindenbaum J, Roman MJ, Nutritional anemia in alcoholism, *Am J Clin Nutr*, 33, 1980, 2727–2735.
- [15] Khanduri U, Sharma A, Megaloblastic anaemia: prevalence and causative factors, *Nat Med J India* 20, 2007, 172–175.
- [16] Joseph AS, Cinkotai KI, Hunt L, Geary CG, Natural history of smouldering leukaemia, *Br J Cancer*, 46, 1982, 160.