

Eventration of Diaphragm Presenting As Recurrent Respiratory Tract Infections- A Case Report

Patel Ravisagar¹, Singh Abhinav², Mathur RM³, Sisodia Anula⁴

¹(Department of cardiothoracic and vascular surgery, SMS medical college, Jaipur India)

²(Department of cardiothoracic and vascular surgery, SMS medical college, Jaipur India)

³(Department of cardiothoracic and vascular surgery, SMS medical college, Jaipur India)

⁴(Department of cardiothoracic and vascular surgery, SMS medical college, Jaipur India)

Abstract: Eventration of the diaphragm (ED) is a relatively rare condition. Eventration of the diaphragm is an abnormal elevation of the dome of diaphragm in which all or part of the diaphragm is largely composed of fibrous tissue. Clinical manifestations range from asymptomatic to life threatening respiratory distress. Recurrent chest infections are also the presenting complaints in patients. We report a 7 year old boy who presented with recurrent chest infections with left diaphragm eventration treated by plication successfully.

Key words: diaphragmatic eventration; dyspnea; recurrent respiratory tract infection; diaphragmatic palsy; plication

I. Introduction

Diaphragmatic eventration is defined as a permanent elevation of a hemidiaphragm without defects of continuity. The muscular insertions are normal, the normal orifices are sealed and there is no interruption of the pleural or peritoneal layers [1]. The eventration may be of congenital origin, with a large unilateral elevation of the diaphragm because of secondary hypoplasia of the homolateral lung, presents with severe cardiorespiratory symptoms in the newborn. Eventration in older children and in adults is usually caused by diaphragmatic palsy and present with dyspnoea. Gastrointestinal symptoms may be present if there is migration of abdominal viscera into the thoracic cavity [2]. long-lasting diaphragm paralysis may lead to cor pulmonale [3]. There are a number of patients in whom a cause cannot be explained (idiopathic eventration). The first report of a surgical repair was published by Morrison in 1923 [4]. It is a rare anomaly with an incidence of 1 in 10,000 live births. Recurrent chest infections are the commonest presenting complaint in patients. [5]

II. Case Report

A 7 years old boy presented with chest pain, cough and fever since 1 month. There is also history of recurrent respiratory infections since 2 years of age. Chest pain increased after taking food orally. Patient was the first child, delivered as full term normal delivery. There was no history of maternal fever or erythematous rashes during pregnancy. On examination, patient had respiratory rate of 34/min. Chest examination revealed decreased movements on left infra-mammary, infra-axillary, and infrascapular areas. Tactile vocal fremitus was decreased and note was impaired on the left infrascapular area. Breath sounds were decreased in the left infra-axillary and infrascapular areas. Extensive crepitations were heard throughout the left lung field. Investigations revealed increased TLC. HIV and Mantoux test were negative. Chest X-ray showed raised dome of left diaphragm and mediastinal shift to right side, Fig 1. CT scan chest confirmed the findings of eventration of diaphragm, Fig 2,3.

Under general anaesthesia, left anterolateral thoracotomy was done through 6th intercostal space and plication of left dome of diaphragm was done, Fig 4. Repeat X-ray after plication showed left diaphragm in proper position. Child was discharged and is on regular follow up without any chest infections.

III. Discussion

Atrophy, thinned wall and progressive distension of the diaphragm represent the main characteristics of diaphragmatic eventration. Newborns usually present with acute respiratory failure, but in adulthood the most common symptoms are dyspnoea and thoracic pain. Simansky et al., in 2002, reported that the indication for surgery for all children was failure to wean from ventilatory support, while the indications for surgery in the adult group were ventilator dependency and symptomatic dyspnoea [6]. Earlier, Graham et al. also indicated shortness of breath as the main symptomatic feature of diaphragmatic paralysis [7]. DeVries et al. clearly state that phrenic nerve injury — inducing chronic diaphragmatic paralysis — leads to eventration [8]. A paralysis of the hemidiaphragm can produce significant alterations in the respiratory physiology. These include atelectasis

and ventilation—perfusion mismatch, preferential redistribution of pulmonary blood flow to the contralateral lung, shift of the mobile mediastinum to the contralateral side and paradoxical movement of the affected hemidiaphragm[9].

Diaphragmatic plication is a standard, well-described technique to treat diaphragmatic eventration[2] but there have been only a limited number of reports published, most with small series and short follow-ups. Higgs et al. described a group of 19 patients with long-term follow-up in 15 [10] and Versteegh et al. reported on 22 patients with a follow-up in 17 [3]. Both clearly proved that the main and probably most important result is the significant and long-lasting improvement in the subjective symptomatology.

Recently, diaphragmatic plication has also been performed through minimally invasive techniques, either laparoscopic [11] or thoracoscopic[5,12—14]. Most of the published papers on the use of this technique concern case reports or small series, except one that was published by Freeman et al. [5] which reports on 22 patients. We strongly believe that the diaphragm should be rendered as taut as possible, which may not be possible with a video-assisted technique because of the lack of full tactile feedback. The risk of damage to the abdominal viscera through such a thin diaphragm is present and is probably greater with a less invasive approach. To inspect the entire raised diaphragmatic cupula may be quite difficult. In any case, the incidence and intensity of post-thoracotomy pain does not seem to be very different [15]. Obviously, there are no head-to-head comparisons to date [3], and the answer to this dilemma will only come with further study. In conclusion, this case demonstrates that patients with chronic respiratory infections due to unilateral, non-malignant eventration significantly benefit from diaphragmatic plication.

IV. Conclusion

Eventration of diaphragm can present with recurrent respiratory tract infections in children, and a differential diagnosis of eventration should be kept in mind. Plication of diaphragm is the treatment of choice. In the present case also the left eventration of diaphragm was successfully treated with plication. The child is asymptomatic and in regular follow up.

References

- [1] Mouroux J, Venissac N, Leo F, Alifano M, Guillot F. Surgical treatment of diaphragmatic eventration using video-assisted thoracic surgery: a prospective study. *Ann Thorac Surg* 2005;79:308—12.
- [2] Shields TW. Diaphragmatic function, diaphragmatic paralysis, and eventration of the diaphragm. In: Shields TW, Locicero III J, Ponn RB, Rusch VW, editors. *General Thoracic Surgery*. Lippincott Williams & Wilkins; 2005. p. 740—5.
- [3] Versteegh MIM, Braun J, Voigt PG, Bosman DB, Stolk J, Rabe KF, Dion RAE. Diaphragm plication in adult patients with diaphragm paralysis leads to long-term improvement of pulmonary function and level of dyspnea. *Eur J Cardiothorac Surg* 2007;32:449—56.
- [4] Morrison JMW. Eventration of diaphragm due to unilateral phrenic nerve paralysis. *Arch Radiol Electrotherap* 1923;28:72—5.
- [5] Soni A, Singh P, Singh RJ, Sood V. Eventration of Diaphragm - Embryological basis. *J Anat Soc India*. 2005; 54: 39-41
- [6] Simansky DA, Paley M, Refaely Y, Yellin A. Diaphragm plication following phrenic nerve injury: a comparison of paediatric and adult patients. *Thorax* 2002;57:613—6.
- [7] Graham DR, Kaplan D, Evans CC, Hind CRK, Donnelly RJ. Diaphragmatic plication for unilateral diaphragmatic paralysis: a 10-year experience. *Ann Thorac Surg* 1990;49:248—52.
- [8] DeVries TS, Koens BL, Vos A. Surgical eventration caused by phrenic nerve injury in the newborn. *J Pediatr Surg* 1998;33:602—5.
- [9] Freeman RK, Wozniak TC, Fitzgerald EB. Functional and physiologic results of video-assisted thoracoscopic diaphragm plication in adult patients with unilateral diaphragm paralysis. *Ann Thorac Surg* 2006;81:1853—7
- [10] Higgs SM, Hussain A, Jackson M, Donnelly RJ, Berrisford RG. Longterm results of diaphragmatic plication for unilateral diaphragm paralysis. *Eur J Cardiothorac Surg* 2002;21:294—7.
- [11] Hu'iti TP, Wichmann MW, Reichart B, Geiger TK, Schildberg FW, Meyer G. Laparoscopic diaphragmatic plication, long-term results of a novel technique for postoperative phrenic nerve palsy. *Surg Endosc* 2004;18: 547—51.
- [12] Gharagozloo F, McReynolds SD, Snyder L. Thoracoscopic plication of the diaphragm. *Surg Endosc* 1995;9:1204—6.
- [13] Hwang Z, Shin JS, Cho YH, Sun K, Lee IS. A simple technique for the thoracoscopic plication of the diaphragm. *Chest* 2003;124:376—8.
- [14] Hines MH. Video-assisted diaphragm plication in children. *Ann Thorac Surg* 2003;76:234—6.
- [15] Rogers ML, Duffy JP. Surgical aspects of chronic post-thoracotomy pain. A review article. *Eur J Cardiothorac Surg* 2000;18:711—6.
- [16] Tiryaki T, Livanelioglu Z, Atayurt H. Eventration of the diaphragm. *Asian J Surg*. 2006; 29: 8-10

Proper informed consent was obtained from patient's parents for publication of the article.

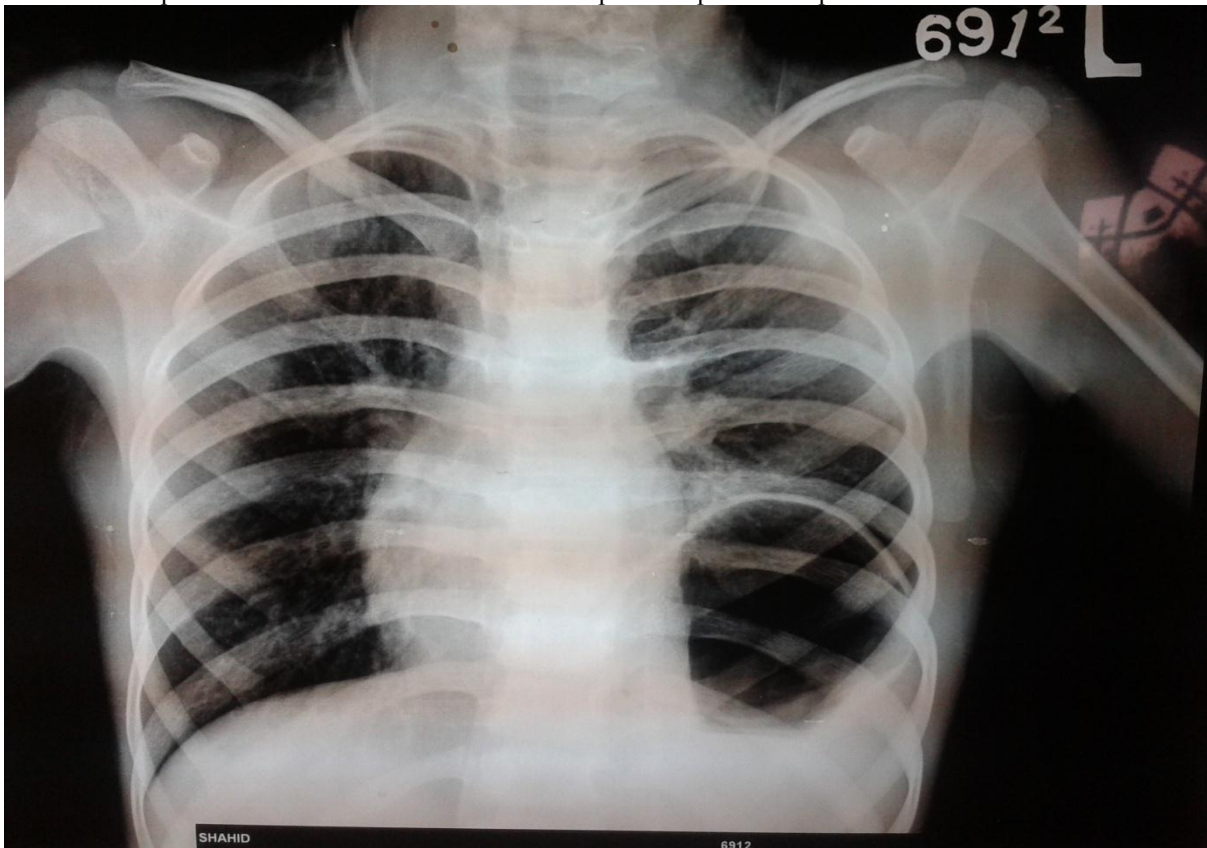


figure 1 - chest x ray showing raised left dome of diaphragm, with well defined left diaphragmatic margin

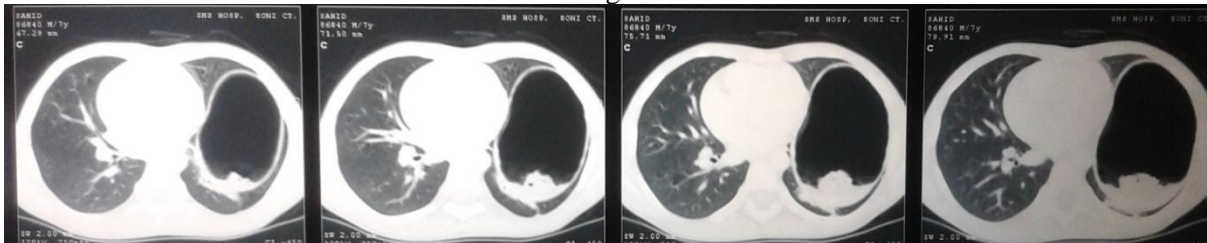


figure 2- CT chest showing eventration of diaphragm on left side

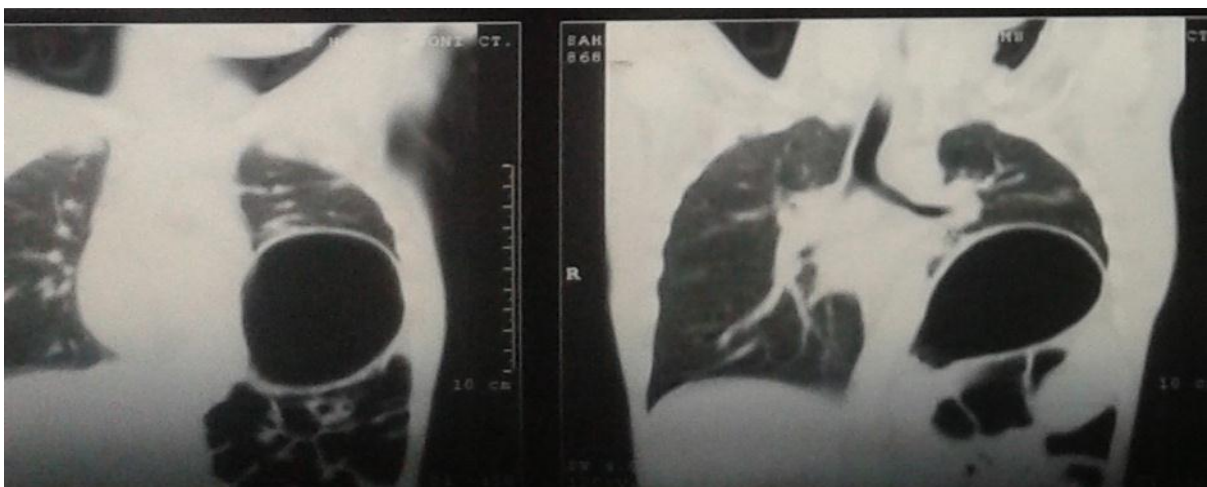


figure 3 - CT chest coronal section showing eventration of diaphragm

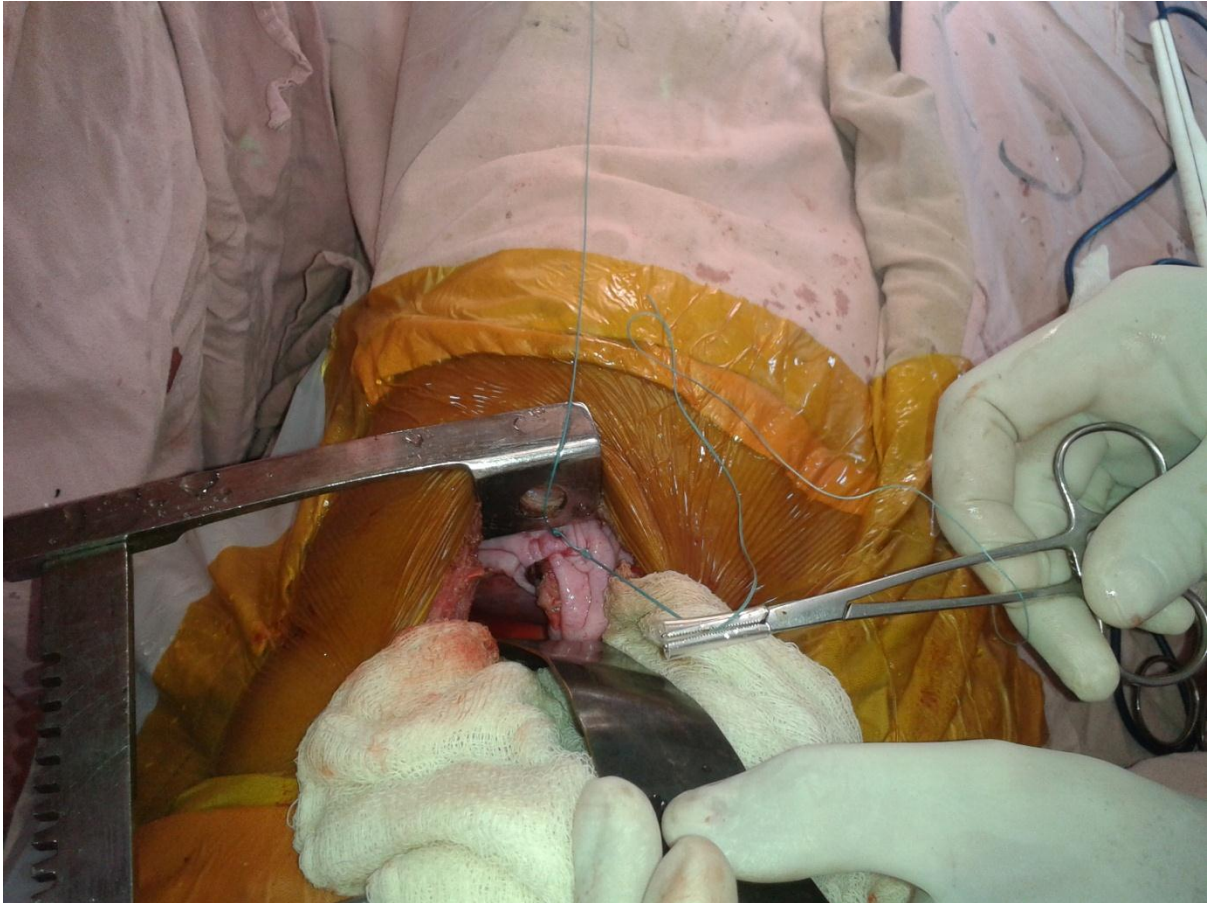

figure 4 - intraoperative photo showing placcation of the eventration of diaphragm, lax fibrosed diaphragm is evident