

Skeletal Discrepancy Correction In Class II Div 1 Malocclusion Using Fixed Twin Blocks.

Dr. Taruna Puri¹, Dr. Dolly Patel²

¹ Senior lecturer, Bhojia Dental College and Hospital, Baddi, HP, India.

² Dean, AMC Dental College and Hospital, Ahmedabad, Gujarat, India.

Abstract: *This case report describes the management of a male with a severe Class II skeletal discrepancy, Class II molar and canine relationship bilaterally, a large overjet and an impinging overbite. As the patient was in CVMI stage 4, it was planned to make use of remaining growth for correction of skeletal discrepancy and so the treatment was initiated with a fixed twin block. This promoted the growth of the mandible, restrained maxilla in anteroposterior direction which in combination with the fixed appliances for alignment and levelling of the dentition improved the convex soft tissue profile. Thus severe skeletal Class II discrepancy was successfully managed with the combination of functional correction along with comprehensive fixed mechanotherapy without any extraction resulting in acceptable soft tissue changes.*

Keywords: *Functional appliances, fixed twin block, Class II skeletal discrepancy.*

I. Introduction

Class II malocclusion occurs in about one third of the population. Class II skeletal discrepancy may be due to maxillary protrusion, mandibular retrusion or combination of both, however mandibular skeletal retrusion being the most consistent finding¹. Many functional appliances targeting different areas of the oral cavity have been used for many years in the treatment of Class II malocclusions. Alteration of maxillary growth, improvement in mandibular growth and position, and change in dental and muscular relationships are the expected effects of these appliances.²

The Twin-block appliance, originally developed by Clark is a widely used functional appliance for the management of Class II malocclusion. The appliance can be worn most of the time, with the advantage of allowing nearly a full range of mandibular movement, easy acclimation, reasonable speech and a good patient compliance. Its popularity also comes from its high patient acceptability and its ability to produce rapid results³. Despite this, sometimes compliance with twin block appliance is not good. As the patient was in the last stages of growth, so we decided to give a fixed functional appliance. As other fixed functional appliances are complex in their design and costly, a fixed twin block appliance was chosen.

II. Diagnosis

A 15-year-old male patient reported to the Department of Orthodontics, Government Dental College and Hospital, Ahmedabad with a chief complaint of upper front teeth coming out. (Fig 1).

Clinical Examination :

1. Extraoral

- He had a mesomorphic body type with normal gait and posture. On frontal view, he had a mesocephalic head, mesoprosopic face and consciously competent lips. On smiling, he

demonstrated a nonconsonant smile arc and normal gingival display. On profile view, he exhibited a convex soft tissue profile, a deep mentolabial sulcus and a recessive chin.

2. Intraoral:

Intraoral examination and study casts showed a Class II molar and canine relationship bilaterally. All permanent teeth excluding third molars were present. The patient had an overjet of 9 mm and an overbite of 6 mm. Lower dental midline was shifted to the right side in relation to facial midline. The upper arch was ovoid shaped with minor spacing in anterior region. The lower arch was also ovoid shaped with mild crowding in the anterior region and an increased Curve of Spee (3 mm). There was a tooth size arch length discrepancy of 1 mm in lower arch and 2 mm in upper arch (Fig 2). There was a need for expansion in both premolar and molar regions as indicated by pont's analysis and arch shape. Bolton's analysis showed a slight both maxillary overall and anterior excess. Both upper and lower anterior teeth were slightly proclined. The lateral cephalogram confirmed a Class II skeletal base relationship. (Table 1 and Fig 3).

Treatment Goals were To:

- 1) To correct severe Class II skeletal base relationship.
- 2) To achieve and maintain Class I molar and canine relationship bilaterally.
- 3) To improve the soft tissue profile.
- 4) To align and level upper and lower arches.
- 5) To achieve normal overjet and overbite.
- 6) To create a consonant smile arc and an esthetic smile.

Treatment Alternatives:

The plan was a 2-phase treatment. To correct the skeletal discrepancy anteroposteriorly by growth modification, a fixed functional appliance (a fixed Twin-block) was given (Fig 4). The prime goal of the treatment was to promote growth of the mandible and control the eruption of molars, to correct the skeletal Class II relationship and improve his profile. A fixed mechanotherapy (straight wire appliance) was then used for alignment, levelling, finishing and detailing of the occlusion.

Treatment Plan:

Keeping above goals in mind and to reduce the skeletal discrepancy in anteroposterior plane it was decided to treat the case with a fixed functional appliance (fixed Twin-block) for the phase 1 treatment, followed by fixed appliance for the final finishing and detailing of occlusion.

Treatment Progress

As the patient was in the cervical vertebral maturity index Stage 4, he was given a fixed twin block for correction of mandibular retrusion. The active period for the functional correction lasted for about 9 months, after which his post functional records were made (Fig 5 and 6). As the patient was a horizontal grower the construction bite for twin block had greater horizontal correction and less vertical advancement.

After the functional correction, the patient's mandible was positioned forward and the profile was greatly improved. A skeletal anteroposterior reduction was significant with 5° change in the ANB angle, partly due to mandibular advancement and partly due to maxillary growth restriction.

The functional correction was followed by fixed mechanotherapy with 0.022×0.028 inch pre adjusted edgewise appliance using MBT prescription. Wire sequencing during the treatment was initial levelling and alignment with a sequence of 0.014'',0.016'', 0.17×0.25 HANT wires followed by 0.17×0.25 SS wires upto 0.21×0.25 SS wires.Settling of the occlusion was done by giving settling elastics for a period of 2 weeks.The entire finishing phase after achieving post functional correction lasted for about 1 year.

III. Treatment Results

After the functional correction, the patient's mandible was positioned forward, and the profile was greatly improved (Fig 7 and Table 1).The intraoral examination showed improvement of the deep overbite and large overjet as well as labially inclined maxillary anterior teeth, and correction of molar relationship. After active treatment, a normal occlusion with optimal overbite and overjet was achieved(Fig 8,9). The patient was satisfied with his facial profile, which had changed from convex to straight. Lip protrusion also greatly improved. Neutrocclusion of the canines and the molars,good alignment and leveling of the maxillary and mandibular teeth, and correction of the dental midline were achieved(Fig 8 and 9). The cephalometric analysis depicted an increased mandibular length, a forward position of the mandible, restriction of maxillary growth and a good interincisal angle..

Retention Plan

The patient was given activator as a retentive appliance for 6 months followed by removable hawley's retainer for 6 months for maxillary arch and a hawley's retainer plus a fixed canine to canine bonded retainer for lower arch.

IV. Figure legends




FIGURE 1:PRETREATMENT EXTRAORAL PHOTOGRAPHS

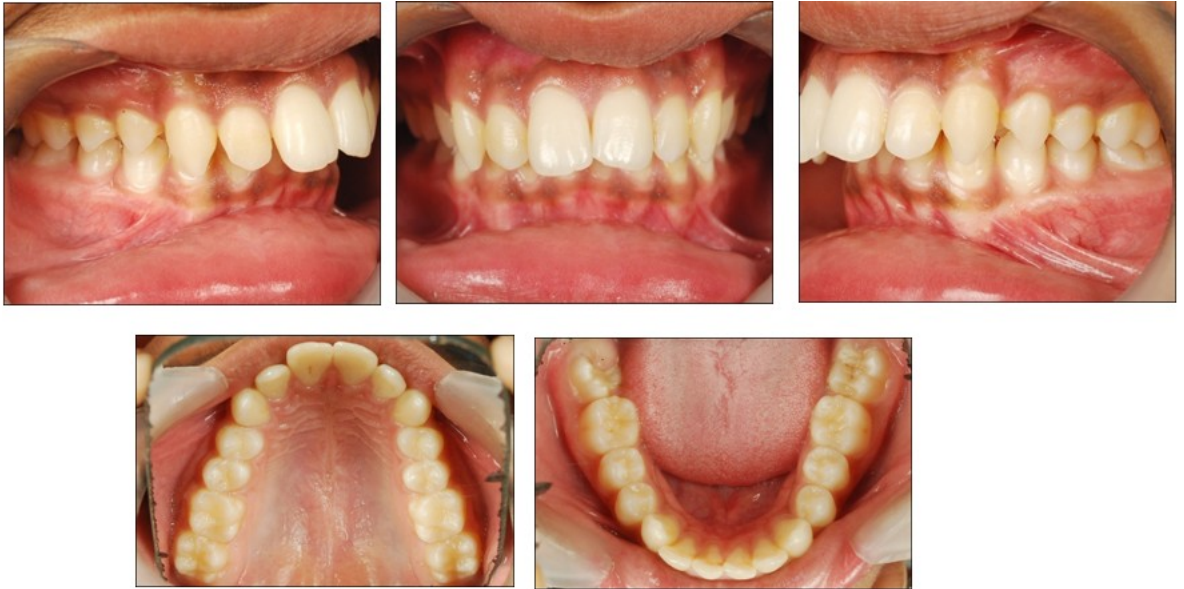

Figure 2: Pretreatment intraoral photographs.

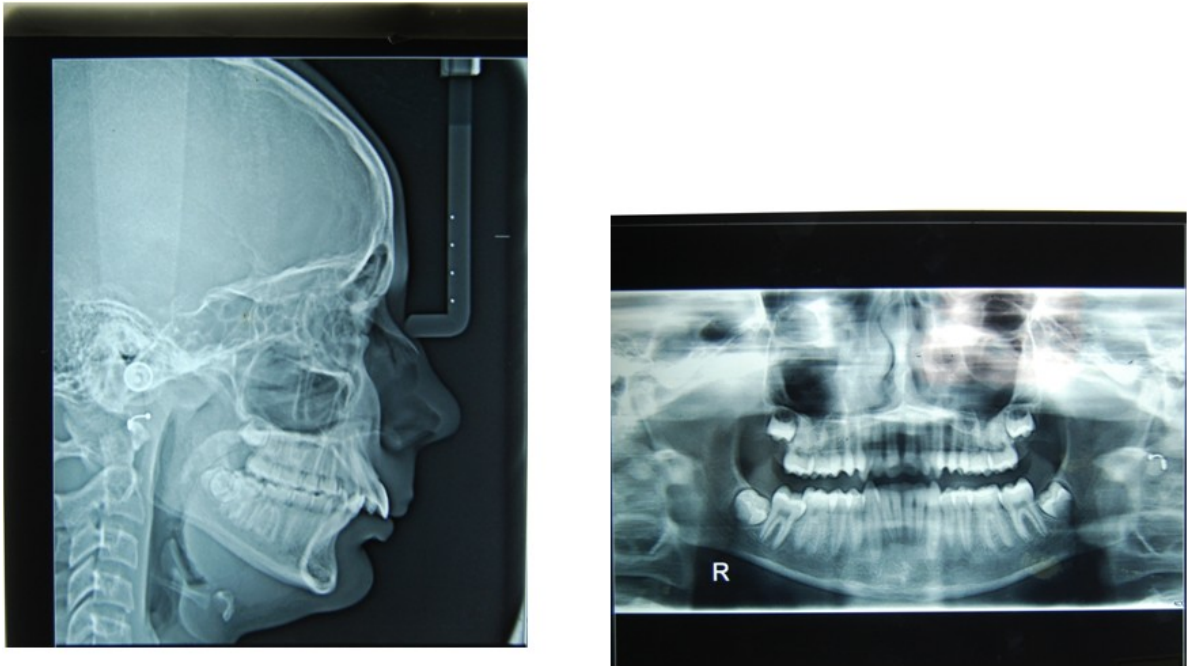


Figure 3: Pretreatment lateral cephalogram and orthopantomogram.

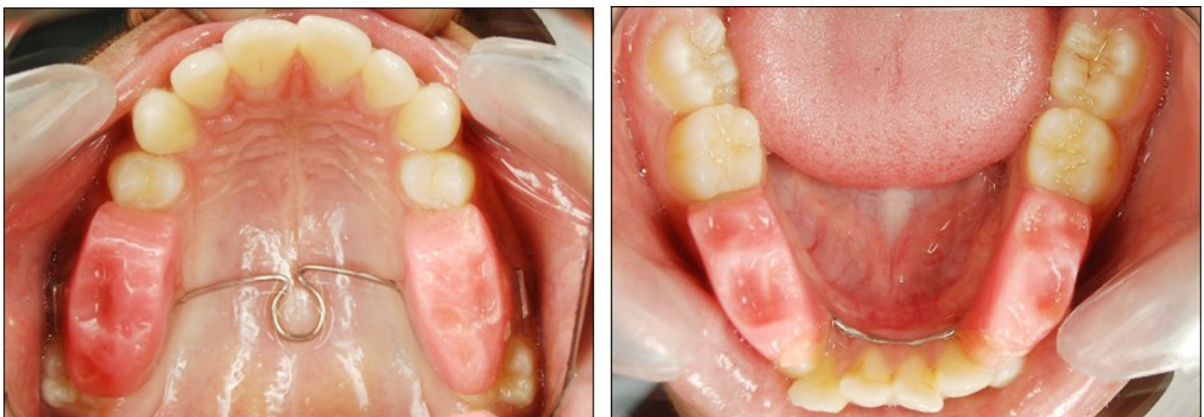

Figure 4 : Patient was given a fixed twin block.



Figure 5: Postfunctional extraoral photographs.

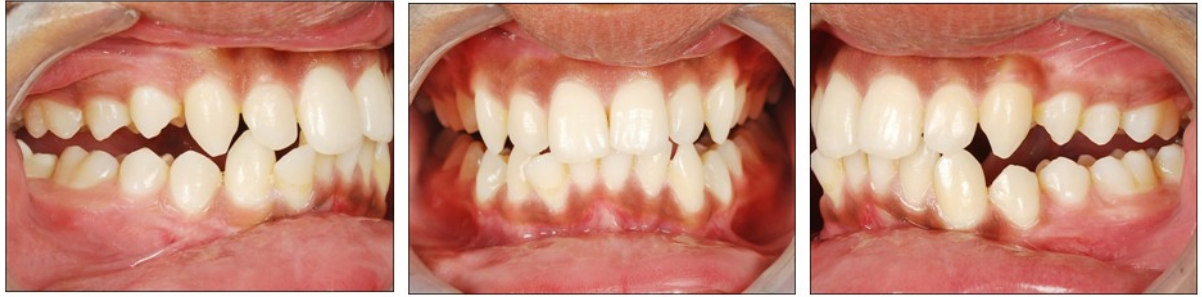

Figure 6 : Postfunctional intraoral photographs.

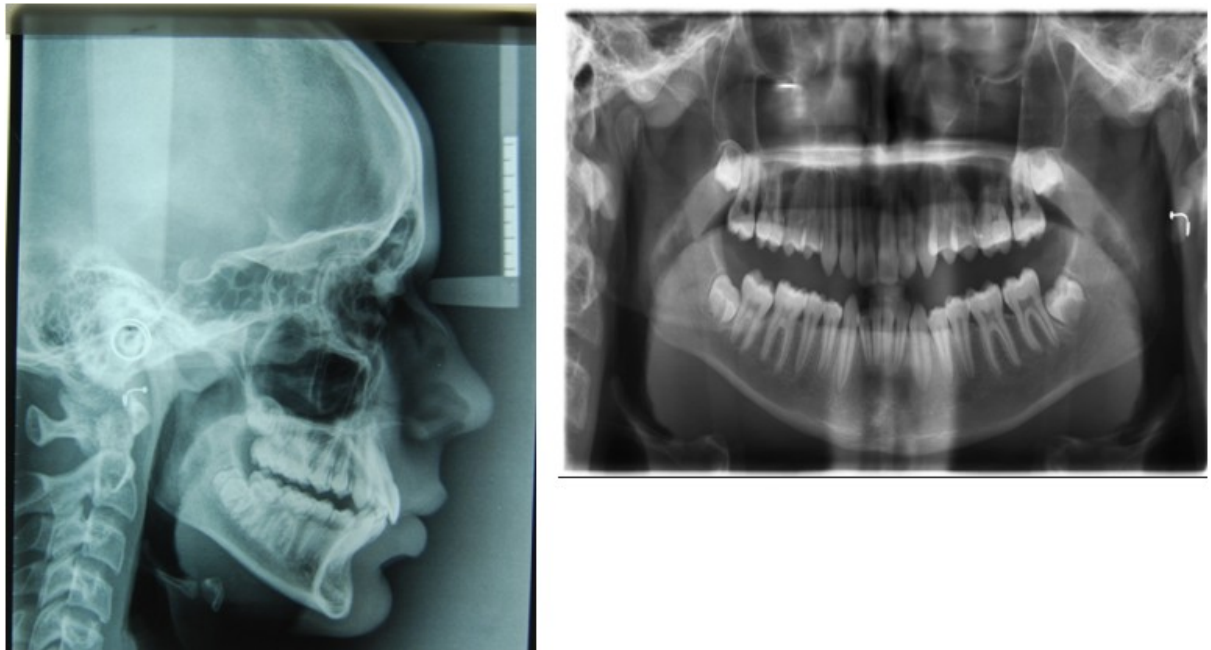


Figure 7: Post functional lateral cephalogram and orthopantomogram.

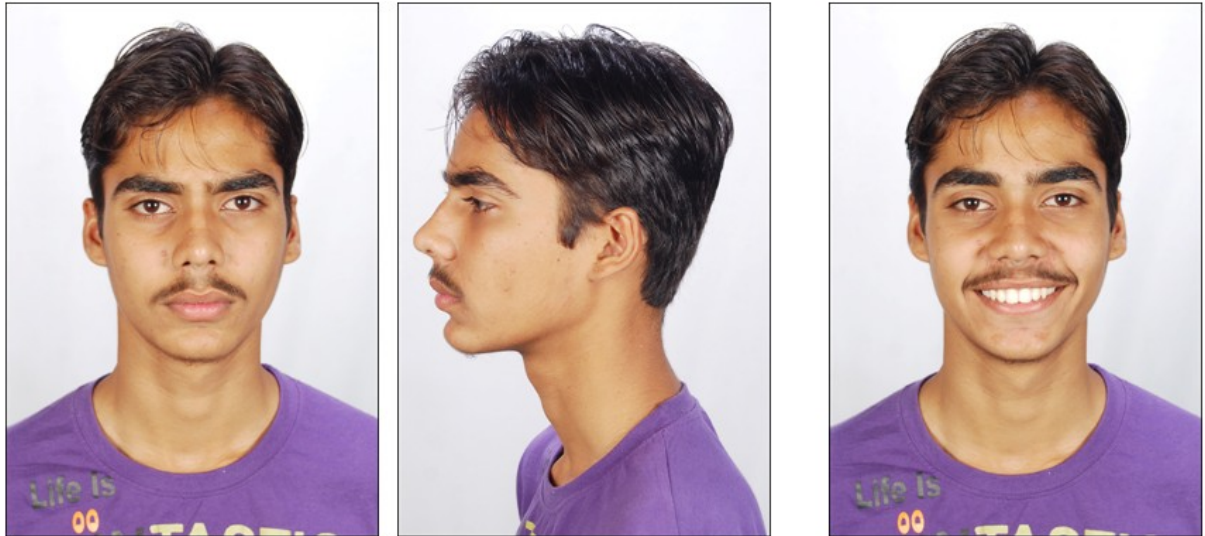

Figure 8. Post debonded extraoral photographs.

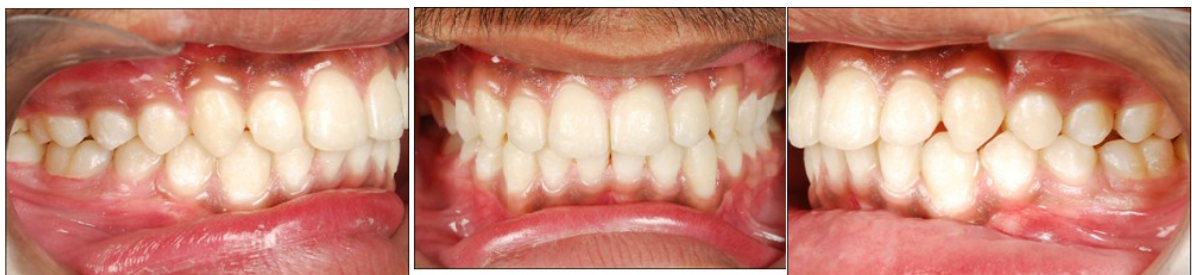

Figure 9: Post debonded intraoral photographs.

V. Table

	Normal	Pretreatment	Post functional	Prior to debonding
SNA	$82^{\circ} \pm 2^{\circ}$	83°	82^0	82^0
SNB	$80^{\circ} \pm 2^{\circ}$	76°	80^0	80^0
ANB	2°	7°	2^0	2^0
FMA	25°	23°	25^0	25^0
SN-GoGn	32°	30°	30^0	30^0
Gonial angle	128°	125°	125^0	125°
IMPA	90°	100°	101^0	101°
Interincisal angle	130°	113°	120^0	127°
LAFH	$67.2 \pm 4.7\text{mm}$	58mm	60mm	60mm
U1-NA	22°	30°	25^0	23°
U1-NA	4mm	7mm	6mm	5mm
L1-NB	25°	29^0	31^0	32°

L1-NB	4mm	5 mm	6mm	6.5mm
L1-APog	-1.2mm ± 1.4mm	2mm	3mm	3mm
E line-upper lip	-4mm	- 2.5mm	-3 mm	- 3mm
E line lowerlip	-2mm	- 2mm	-1mm	-1mm
Nasolabial angle	102° ± 8°	111°	109 ⁰	109 ⁰
Overjet	2mm	9mm	2mm	2mm
Overbite	2mm	6mm	3mm	2mm
Saddle Angle	123±5	131°	119°	120°
Articular Angle	143±6	148°	145°	145°
Gonial Angle	128±7	125°	125°	125°

VI. Discussion

Three alternatives for treating skeletal Class II malocclusions are growth modification, dental camouflage, and orthognathic surgery. Until the last three decades of the twentieth century, only the first two alternatives were possible. Growth modification of skeletal Class II problems has been undertaken with principally two types of appliances: headgears and functional appliances. Though a variety of functional appliances are available for class II correction, Twin-block appliance has 2 obvious advantages over other appliances that is greater mandibular growth because of the duration and timing when the appliance is worn and less alteration of speech. Another advantage is the apparent elongation of the mandibular ramus this could be attributed to a greater vertical activation of the appliance (bite-blocks must be at least 5 to 7 mm thick vertically).⁴ In the same manner, functional appliances may stimulate some mandibular growth acceleration, but the headgear like effect is probably necessary for successful treatment.

In this patient, intervention by functional appliances with improved compliance helped in using his growth potential to achieve stable results and improved self esteem as described in several studies.⁵⁻⁸ A much better understanding of the role of epigenetic or environmental factors on facial morphology and dental malocclusion will also be necessary for complete management of these problems. For the present, there continues to be a controversy regarding the nature of facial growth modification, its optimal timing, and the efficacy of the various appliances used. No universal appliance or cookbook formula is available for Class II therapy.

VII. Conclusion

A careful and complete diagnosis, a continued diagnostic monitoring during treatment, a careful step by step accomplishment of the treatment objectives, a number appliances in the armamentarium, and a willingness to change appliances as changing situations dictate will ensure the best possible treatment.⁹

References

- [1]. Jena AK, Duggal R, Parkash H. Skeletal and dentoalveolar effects of Twin-block and bionator appliances in the treatment of Class II malocclusion: a comparative study. *Am J Orthod Dentofacial Orthop* 2006;130:594-602.
- [2]. Yan Lv,Bin Yan,Lin Wang. Two-phase treatment of skeletal Class II malocclusion with the combination of the Twin-block appliance and high-pull headgear. *Am J Orthod Dentofacial Orthop* 2006;130:594-602,2012,142,246-255.
- [3]. Clark WJ. The twin block traction technique. *Eur J Orthod* 1982;4: 129-38.
- [4]. Schaefer AT, McNamara JA, Franchi L, Baccetti T. A cephalometric comparison of treatment with the Twin-block and stainless steel crown Herbst appliances followed by fixed appliance therapy. *Am J Orthod Dentofacial Orthop* 2004;126:7-15.
- [5]. King GJ, Wheeler TT, McGorray SP, Aiosa LS, Bloom RM, Taylor MG. Orthodontists' perceptions of the impact of phase 1 treatment for Class II malocclusion on phase 2 needs. *J Dent Res*1999;78:1745-53.
- [6]. Keski-Nisula K, Lehto R, Lusa V, Keski-Nisula L, Varrela J. Occurrence of malocclusion and need of orthodontic treatment in early mixed dentition.*Am J Orthod Dentofacial Orthop* 2003;124:631-8.
- [7]. O'Brien K, Wright J, Conboy F, Chadwick S, Connolly I, Cook P, et al. Effectiveness of early orthodontic treatment with the Twin-block appliance: a multicenter, randomized, controlled trial. Part 2: psychosocial effects. *Am J Orthod Dentofacial Orthop* 2003;124:488-94.
- [8]. Huang G. The Twin-block appliance, used during the mixed dentition in Class II Division I malocclusions, may provide psychosocial benefits. *J Evid Based Dent Pract* 2004;4:286-7.
- [9]. Textbook of orthodontics by Dr.Samir Bishara.