

Treatment of Molluscum Contagiosum with KOH in a HIV patient with Immunological and Virological failure on HAART

Dr Dipankar Chakraborty¹, Dr Samir Kumar Rama²

¹(Eye Department, Assam Rifles Composite Hospital Dimapur, India)

²(Medicine Department, Assam Rifles Composite Hospital Dimapur, India)

Abstract : *Molluscum Contagiosum is a common viral disease caused by Pox Virus (DNA Virus). 10 to 30% of patients with symptomatic HIV disease or AIDS have Molluscum Contagiosum. We report a case of Molluscum Contagiosum in a HIV patient with immunological and virological failure on first line Highly Active Anti Retroviral Therapy (HAART) who showed clinical cure of Molluscum Contagiosum lesions to local application of 10% potassium hydroxide (KOH) and second line HAART despite having persistent low CD 4 count with effective maintained HIV viral suppression after 11 months of starting second line HAART.*

Keywords: *CD 4 count, HAART, HIV, KOH, Molluscum Contagiosum*

I. Introduction

Molluscum Contagiosum is a common viral disease¹ caused by Pox Virus (DNA Virus). The virus forms part of the normal flora in the immunocompetent people. It presents as disease in immunocompromised adults. In HIV infected patients, Molluscum Contagiosum manifests itself most commonly when the immune function has been dramatically reduced.

Several studies document the Molluscum Contagiosum infection is a clinical sign of marked HIV progression and very low CD 4 count². Between 10 and 30% of patients with symptomatic HIV disease or AIDS have Molluscum Contagiosum³. Lesions of the face and neck are more common in HIV infected patients¹.

We report a case of Molluscum Contagiosum in a HIV patient which showed clinical response to local application of 10% potassium hydroxide (KOH) with no recurrence in the 11 month follow up period after suppression of the HIV viral load despite having persistent low CD 4 count on second line Highly Active Anti Retroviral Therapy (HAART).

II. Case Report

A 40 years old male patient who was detected to have HIV positive status in 2006 when he presented with cervical lymphadenopathy and was diagnosed to have tubercular lymphadenitis. Other opportunistic infection screen was unremarkable and his CD 4 count on presentation was 183cells/cumm. He was treated with ATT for 09 months and was started on HAART i.e Zidovudine 300mg twice daily, Lamivudine 150mg twice daily and Nevirapine 200mg twice daily with sulfamethoxazole + trimethoprim prophylaxis. Subsequently he was followed up six monthly with his CD 4 count showing gradual improvement to the peak value of 323 cells/cumm in 2009 with adherence to HAART more than 95%.

However in April 2013 despite having more than 95% adherence to HAART the individual reported with multiple painless skin coloured lesions which varied in size from 3 to 6 mm with central umbilication from which cheesy material could be expressed on pressure over the left cheek, four lesions over the left upper eyelid, one lesion below the lateral canthus of left eye, one lesion in the right cheek and one lesion in the right forearm (Fig 1) and these lesions were gradually progressive since Oct 2012.

According to the clinical manifestation the following differential diagnosis were thought of: Lymphomatoid Papulosis, Molluscum Contagiosum, Cryptococcosis, Coccidiomycosis, Histoplasmosis, Penicilliosis, Basal cell carcinoma and Squamous cell carcinoma.

Histopathological examination of the skin lesion on the right forearm showed large cup shaped crater lined by hyperplastic stratified squamous epithelium having intranuclear basophilic inclusions with evidence of extrusion into the crater which was consistent with the features of Molluscum Contagiosum. His CD 4 count was carried out and was found to be 22 cells/ cumm in Apr 2013. Suspecting a case of immunological failure his viral load was carried out which was 1, 99,416 copies/ ml in Apr 2013. Other opportunistic infection screen was unremarkable and hence the patient was started on second line HAART i.e Tenofovir 300mg once daily, Lamivudine 150mg twice daily and tab Lopinavir/ Ritonavir (200/ 50 mg) two tablets daily along with sulfamethoxazole + trimethoprim once daily and Azithromycin 1000mg weekly as opportunistic infection prophylaxis. He was also started on 10% potassium hydroxide (KOH) local application on the Molluscum Contagiosum lesions which was applied twice daily on each lesion. The local therapy was continued until all

lesions developed inflammation and superficial ulceration (Fig 2), the patient achieved complete clinical cure within 06 weeks of starting topical 10%KOH.

In subsequent follow-up in Aug 2013 the lesions of Molluscum Contagiosum had completely healed without any scarring (Fig 3), no new lesions were found and the individual was adherent to the prescribed second line HAART. His viral load was repeated in Aug 2013 and was found to be less than 25 copies/ ml and his CD 4 count was found to be 43 cells/ cumm.

On subsequent six month follow-up the in March 2014 his viral load remained to be suppressed less than 25 copies/ ml with no recurrence of Molluscum Contagiosum lesions though his CD 4 count in March 2014 was 40 cells/ cumm.

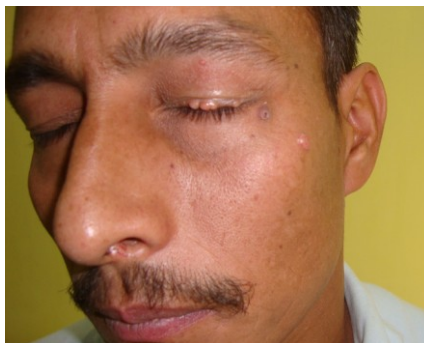

Fig 1: Initial Presentation

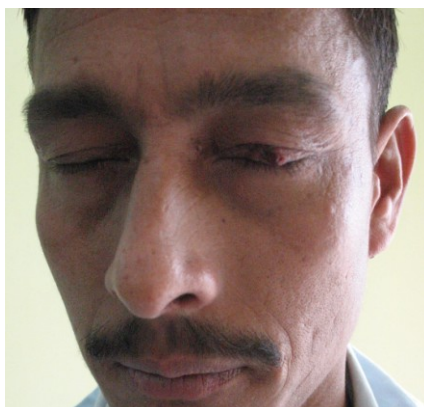

Fig 2: Inflammation and Ulceration of the lesions on 10% KOH application

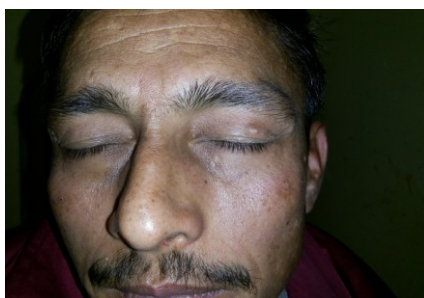


Fig 3: Post treatment

III. Discussion

Molluscum Contagiosum infection is a clinical sign of marked HIV progression and very low CD 4 counts². In our case also it was found that on immunological and virological failure lesions of Molluscum Contagiosum developed.

Studies have shown that Molluscum Contagiosum can be treated with potassium hydroxide (KOH) with evidence of complete clinical cure after mean treatment period of 30 days⁴. In our case also response of the lesions to the local treatment of KOH has been seen in 06 weeks time.

Though the immunologic recovery in our case was not very marked on starting second line HAART as the CD 4 count had increased to 43 cells/ cumm and 40 cells/ cumm only from 22 cells/cumm in three months and eleven months respectively but the persistence of HIV viral suppression of less than 25 copies/ ml even after

eleven months of second line HAART have led to prevention of recurrence of Molluscum Contagiosum lesions. Results from the SMART study⁵ suggest that the latest CD 4 count can only predict opportunistic disease in patients who are not receiving therapy. However CD 4 cell count are of limited use as a long term marker for clinical events as long as complete virological suppression is sustained⁶, which has been seen in our case also wherein sustained virological suppression despite persistent low CD 4 count have decreased the chances of new recurrences of Molluscum Contagiosum lesions.

Acknowledgements

We acknowledge the support and guidance provided by Dr Arun Kumar Mehta, Medical Superintendent, Assam Rifles Composite Hospital Dimapur, India.

References

- [1]. JJ Esposito, F Fenner. Poxviruses. In: DM Knipe, PM Howley. Fields virology. 4th ed (Philadelphia: Lippincott Williams & Wilkins, 2001. P. 2886-2921)
- [2]. A Czelusta, A Yen- Moore, M Van der Straten, D Carrasco and Sk Tyting, An overview of sexually transmitted disease: Part III, Sexually transmitted diseases in HIV infected patients, Journal of the American Academy of Dermatology, 43, 2000, 409-32.
- [3]. RJ Koopman, FC van Merriënboer, SG Vreden, WM Dolmans, Molluscum Contagiosum a marker for advanced HIV infection, British journal of dermatology, 126, 1992, 528-9.
- [4]. R Romiti, AP Ribeiro, BM Grinblat, EA Rivitti, N Romiti, Treatment of molluscum contagiosum with potassium hydroxide a clinical approach in 35 children, Pediatric dermatology, 16 (3), 1999 May- Jun, 228-31.
- [5]. JD Lundgren, A Babiker, W El-Sadr, et al, Inferior clinical outcome of the CD4+ cell count-guided antiretroviral treatment interruption strategy in the SMART study: role of CD4+ Cell counts HIV RNA levels during follow-up, Journal of infectious disease, 197, 2008, 1145-55.
- [6]. A Zoufaly, M. van der Heiden, C Kollan, et al, Clinical outcome of HIV-infected patients with discordant virological and immunological response to antiretroviral therapy, Journal of infectious disease, 203(3), 2011, 364-371.