

Primar Fibrosarcoma of Breast

Dr Sudershan Kapoor

Associate Professor, Department of Surgery, Govt. Medical College, Amritsar

Abstract: *Primary Fibrosarcoma of breast is a rare tumour. Here we report a case of Primary Fibrosarcoma of breast that presented with a huge fungating growth in a 45 yr old woman. Physical examination revealed a big foul smelling fungating growth extending over the chest wall on left side with a history of six months duration. Surgical excision was performed and histopathology report was of Primary Fibrosarcoma of breast.*

I. Introduction

Primary sarcomas of breast are a heterogenous group of malignant mesenchymal neoplasms. Fibrosarcoma is included in this group of sarcomas and this is always malignant although it varies in degree(1).

The overall incidence of Primary Fibrosarcoma of breast has not been established. Polland et al(3) reviewed only 25 cases of PBS that were diagnosed in London hospital during 80 yrs period. Among these, there were only 4 cases of fibrosarcoma. The peak incidence of PBS occurs in 5th -6th decade of life. For fibrosarcoma of breast, the peak incidence is unknown. However Roberson(2) has reviewed the literature and evaluated 49 reported patients with fibrosarcoma of breast and half of them between the age of 41 and 60. These patients presented with a complaint of lump in one breast with two to six months duration and pain was present in one third of cases. In contrary, the clinical presentation of a patient with breast sarcoma is a painless breast lump(8).

II. Case Report

A 45 yr old female presented with a huge fungating mass in left breast. The growth was extending over whole of the breast area. It was about 40 cm x 30 cm in size, a big ulcerated growth with slough and foul smelling discharge on the floor. Fixity to the underlying structures could not be judged due to huge size of the growth. The surface had a variegated appearance with nodular margin. The base was indurated. History revealed that it started as a small nodule of about 5x5 cm in size in the central part of left breast and grew to a big fungating mass in a period of six months (fig 1 and fig 2). There were no lymph nodes palpable in axilla. Investigations did not reveal any secondary deposits in chest and abdomen. Mastectomy was done. The main wound could not be approximated and left for healing by secondary intention. The specimen was sent for histopathological examination.

III. Pathology:

Gross appearance showed a big nodular tumour involving the breast tissue and muscles. Tumour has variegated appearance and foul smelling discharge at the surface.

Histopathology

H&E stained section shows round to oval to spindle shaped cells arranged in interlacing fascicles showing herring bone pattern. The nuclei are hyperchromatic, pleomorphic with prominent nucleoli. Mitosis is increased. Few bizarre looking nuclei also seen. Also of cartilaginous and osseous metaplasia identified. Features are those of fibrosarcoma breast with heterogenous components. (Fig 5 and Fig 6)

After 4 months of the primary surgery, patient again reported with the local recurrence in the form of a nodule of 7x7 cm in size (Fig 7) and two lymph nodes palpable in the anterior fold of axilla of about 2.5x2.5 cm in size hard in consistency. X-Ray chest revealed a shadow in the left lung. Ultrasonography abdomen did not reveal any secondaries.

Wide local excision was done along with the removal of lymph nodes. The nodule was extending upto the chest wall. The margins could not be approximated. Histopathology of the specimen showed again picture of fibrosarcoma breast.

IV. Discussion

Primary stromal sarcomas of breast include fibrosarcomas, liposarcomas, malignant fibrous histiocytomas, rhabdomyosarcomas, leiomyosarcomas, osteogenic sarcomas, malignant schwannomas and chondrosarcomas. Fibrosarcoma is a malignant tumour, that is composed of fibroblasts with variable degree of collagen production and classical herringbone architecture, according to WHO.(4)

The size of primary breast sarcoma(PBS)is variable and it ranges from less than 1cm to larger than 40 cm in size.PBS may spread by direct invasion and haematogenous metastasis.Axillary lymph node involvement is very rare.And the actual nodal metastasis also appears to be very low.The prognosis is usually based on the size of the tumour and the histological grade.

Blanchand et al(5) retrospectively reviewed 55 patients with PBS out of which only 2 were cases of fibrosarcomas.Adjuvant chemotherapy and radiotherapy did not improve the survival .Surgical extirpation remains the effective treatment.

Terrier et al(6) reterospectively studied 33 cases of PBS of which only 2 cases of fibrosarcoma.Immunohistochemistry has been disappointing for identifying the specific histology sub type.

In our patient,the tumour was about 40x 40 cm in size with fungating n ulcerated surface with no lymph nodes involvement in axilla and no distant metastasis.Surgical extirpation was done. After 4 months patient again reported with local recurrence in the form of a 5x5 cm nodule and axillary lymph nodes.

In short,Primary fibrosarcoma of breast is a rare tumour which is diagnosed only histologically and with rapid growth and spread.Prognosis is variable depending upon the grade of tumour and distant spread.

References

- [1]. Roberson CV: Fibrosarcoma of Breast:J.Ark Med Soc:1973;19-257-265
- [2]. Barnes I Pietruszka M.: Sarcoma of Breast.A Clinico pathological analysis of ten cases:Cancer 1977,40:1577-1578
- [3]. Polland SG, Marks PV, Thompson HH: Breast Sarcomas: A clinicopathological review of 25 cases:Cancer 1990;15:941-944
- [4]. Trent JC 2nd, Benjanin RS, Vatero v: Primary soft tissue sarcoma of breast-Curr Treat Option Oncol 2001;2:169-176
- [5]. Blanchand DK, Raynolds CA, Orant CS, Donohue JH: Primary neophylloides. Breast sarcomas: Ann J. Surgery. 2003;186-359-361
- [6]. Terrier P, Rerrier-Lacumbe MJ, Mouriessie H, Freitman S, Spielmann M: Primary Breast Sarcomas: A review of 33 cases with immunohistochemistry and prognostic factors-Breast Cancer Res Treat 1989;13:39-48
- [7]. Hassan S, Adari G: Primary Breast Sarcomas: Case Report: East Afr Med J 2004,8(7)375-7
- [8]. Nishat Afroz, Sufian Zaheer, Nazoora Khan, Amanullah Khan: Primary Fibrosarcoma of Breast. A Case Report: Iranian Journal of Pathology. 2010;5(4)204-207

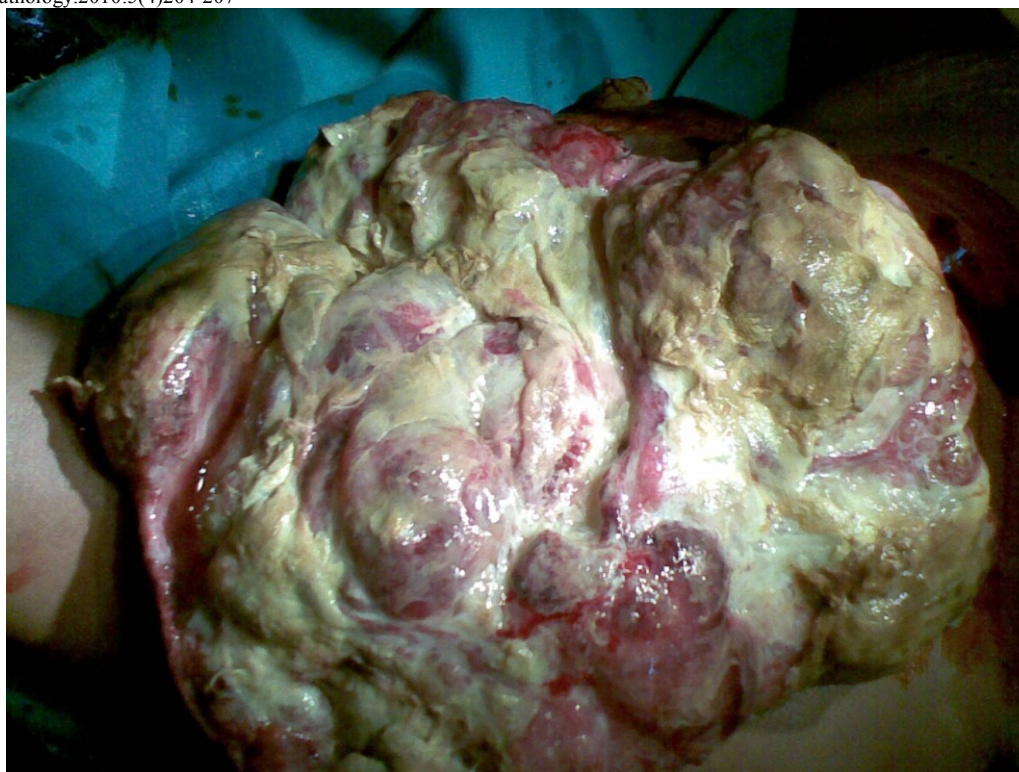

Fig 1. Primary fibrosarcoma breast

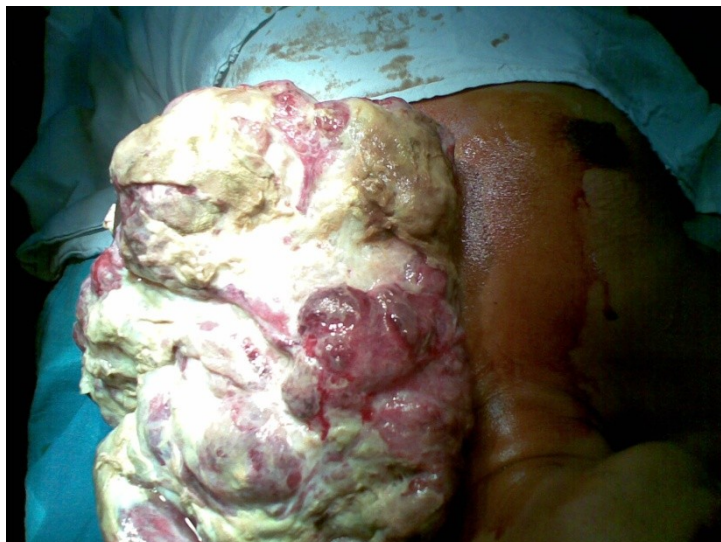

Fig 2. Primary fibrosarcoma breast

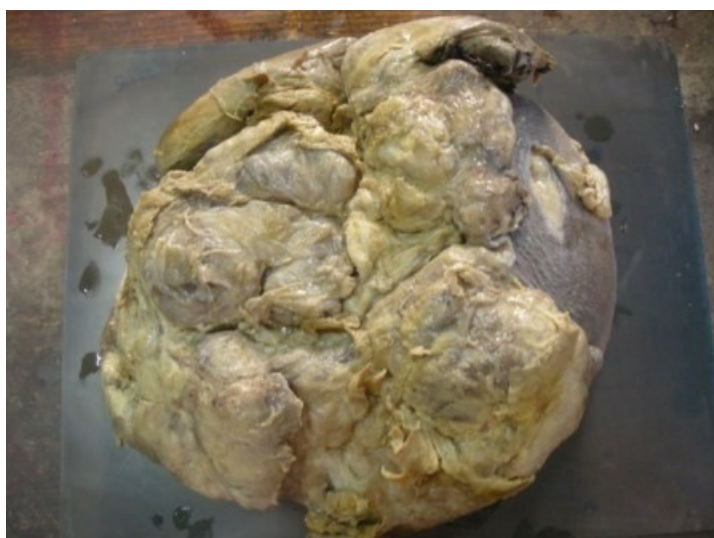

Fig 3 .Gross appearance of tumour.(Primary fibrosarcoma breast)

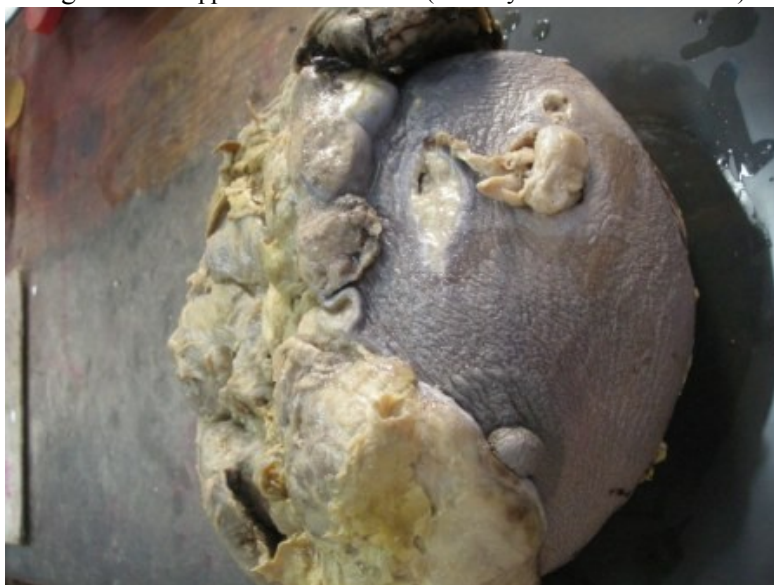

Fig 4. Gross appearance of tumour(Primary fibrosarcoma breast)

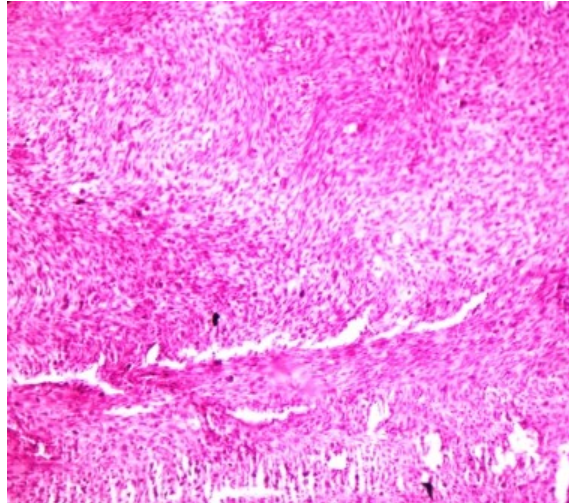


Fig 5. Histopathology of Primary Fibrosarcoma Breast showing herringbone pattern of cells(**herringbone pattern** - a pattern of columns of short parallel lines with all the lines in one column sloping one way and lines in adjacent columns sloping the other way; it is used in weaving , masonry, parquetry, embroidery)

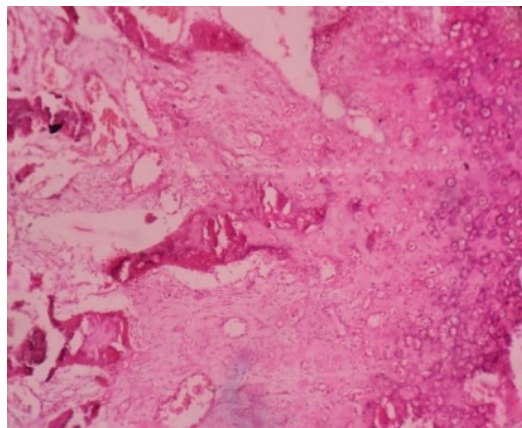


Fig 6. Histopathology of Primary fibrosarcoma breast.

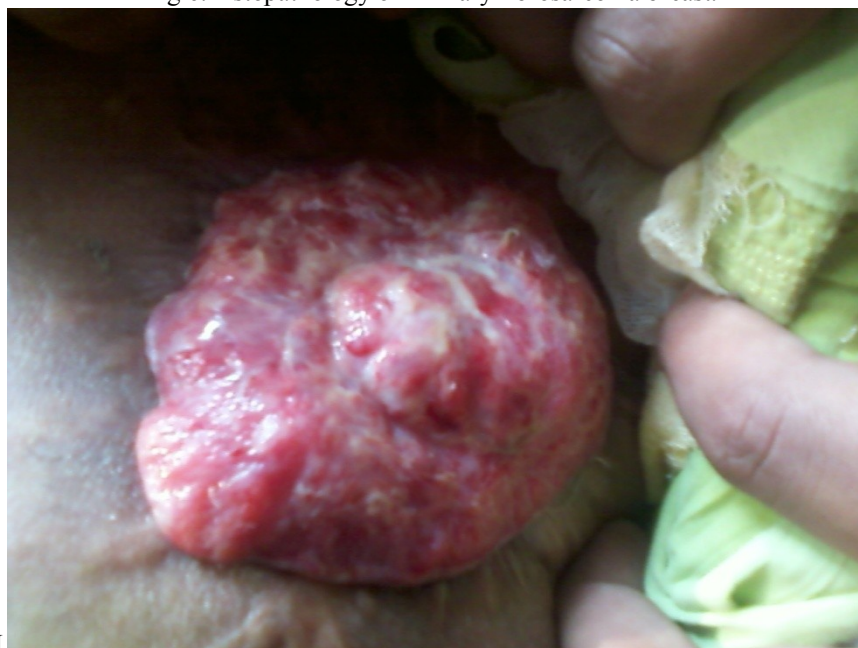

Fig. 7. Recurrence of tumour at the primary site