

## Surgical Treatment and Reconstruction for Central Giant Cell Granuloma of Mandible- Case Report and Literature Review

Dr Harjit S Kalsi, Dr Vipin Thakkar, Dr Viraj Kharkar

Department of Oral and Maxillofacial surgery, Bharati Vidyapeeth Dental College and Hospital, Navi Mumbai, Maharashtra, India

---

### **Abstract:**

**Introduction:** Central giant cell granuloma (CGCG) is a benign aggressive, highly recurrent, very vascular, rapidly growing with undefined etiology & clinically poorly defined, destructive osteolytic lesion of osteoclastic origin. The central giant cell granuloma is often found in the mandible commonly occurring in patients under the age of 30. CGCG always pose a challenge to oral and maxillofacial surgeon. Because of such a type of nature of these lesions a surgeon's treatment of choice is radical resection. However, in recent past it has been noticed that complete removal of these lesions by enucleation has not resulted in any recurrence over a period.

**Purpose:** To present a case of CGCG of the lower jaw of a young person in Department of Oral and maxillofacial surgery, Bharati Vidyapeeth Dental College and Hospital, Navi Mumbai. Although en bloc resection provides the lowest recurrence rate, only a few single case reports describe the use of this technique followed by reconstruction with autogenous bone grafts.

**Material and methods:** The medical history of a 18 years patient with a large central giant cell granuloma in the Mandible on the right side extending from canine to the ramus of the mandible. Biopsy specimen taken from the lesion showed CGCG followed by curettage with peripheral ostectomy with preservation of the continuity of the mandible and inferior alveolar bundle. Reconstruction done with titanium reconstruction plate and defect filled with bone graft material.

**Result:** At the end of 12 months clinical and radiological follow up there was no sign of recurrence and showed a well acceptance of the bone graft.

**Conclusion:** After complete healing of the graft, prosthetic rehabilitation with implants will be performed. This allows the best functional and aesthetic results.

**Key words:** Central giant cell granuloma (GCGC), irradiated cortico-cancellous alloplastic bone grafts, Titanium Reconstruction plate & screws

---

### I. Introduction

The central giant-cell reparative granuloma (CGCRG) has been defined as a localized benign aggressive osteolytic proliferation consisting of fibrous tissue with hemorrhage and hemosiderin deposits, presence of osteoclast-like giant cells and reactive bone formation.

CGCRG has been first described by Jaffe in 1953 [5] and accounts for approximately 7% of all benign tumours of the jaws. [6] It usually appears as solitary, multilocular, radiolucency, located in the mandible (anterior to the first Molars) and maxilla. It occurs at least twice as often in the mandible than in the maxilla. CGCRG most commonly occurs in patients under the age of 30, [6] the aetiology of giant cell granuloma is undefined; some describe it as an inflammatory proliferation, some lesions behave as a neoplastic process in an aggressive fashion. Jaffe considered this tumour as a locally reparative reaction of the bone due to inflammation, local trauma or haemorrhage. [5] In the literature there is little evidence of any local reparative process. The clinical behaviour of CGCG ranges from a slow growing asymptomatic swelling to an aggressive lesion that presents pain, local bone destruction, root resorption or tooth displacement. Currently, clinical signs and symptoms, radiological features and histological features are the main criteria to differentiate between non-aggressive (indolent) and aggressive lesions.

Aggressive lesions are characterized by one or more of the following features: pain, paraesthesia, root resorption, rapid growth, cortical perforation, and a high recurrence rate after surgical curettage- between 37.5% and 70% [4, 7, 10] and are mostly found in younger patients [2] are larger (over 5 cm) [1]. These aggressive type or recurrent lesions require wide en-bloc resection that leads to major defects in the jaws that can alter the facial contours [2, 3, 8] and necessitate major reconstruction. Some surgeons use autogenous bone grafts or vascularized fibula free flap for reconstruction of extensive CGCG. [3, 8] Histologically there is no strict criterion to differentiate between aggressive and non-aggressive lesions, however the number and volume of giant cells versus other components of the lesion might give an indication on its clinical behavior. [1, 2, 6, 10] Non-aggressive lesions are usually slow growing,

symptom free and the treatment includes conservative surgical procedures. Although the majority of cases were asymptomatic, the most common feature was a painless smooth swelling in the face or in the oral cavity. The lesion does not invade the perineural sheets so paresthesia is not usually observed in these patients. The other symptoms and signs are facial asymmetry, impaired nasal breathing, loosening or displacement of teeth, and pathologic fracture.[6, 9] CGCRGs usually present as an expansile radiolucency (87.5%) in X-ray films, but radiologic features vary from ill-defined destructive lesions to a well-defined, multilocular or unilocular appearance, with root resorption in 13.5% of the lesions and displacement of teeth in 18.0%. Histologically, multinucleated giant cells, in a cellular vascular stroma, and often-new bone formation are demonstrated. The osteoclast-like giant cells have a patchy distribution and are usually associated with areas of hemorrhage. Ultrastructurally, the proliferating cells include spindle-shaped fibroblasts, myofibroblasts, and inflammatory mononuclear cells.[2, 6]

## **II. Differential Diagnosis Should Be Considered:**

Aneurysmal bone cyst,  
Chondroblastoma,  
Osteoblasto-clastoma,  
Ameloblastoma,  
Fibroma non-ossificans,  
Hyper-parathyroidism,  
Odontogenic cysts etc.

The treatment of CGCG of the jaws is performed according to the following factors: aggressive versus non-aggressive behaviour, location, size and radiographic appearance. Surgical options range from large (en bloc resection) to more conservative approaches (curettage). The traditional therapy of CGCRG has been local curettage (this has been associated with a high success rate- 80%), peripheral osteotomy, excision if needed reconstruction by using an autologous bone graft. [2, 6] Surgical treatment of CGCRGs can be associated with recurrence and serious facial mutilation and loss of teeth and tooth germs. To avoid such disadvantages, a number of alternative nonsurgical therapies' including interferon alpha- 2a, calcitonin and intralesional corticosteroid injection have been advocated for the management of CGCRG. Non- surgical treatment of CGCRG is probably a good treatment option for small slowly enlarging lesions. Successful treatment of painful, large, and rapidly growing lesions is more likely achieved by surgical removal. In the literature, recurrence rates vary between 11% and 35%. [6]

## **III. Case Report**

We present 18 years old male with histopathologic examination of the lesion reported as 'giant cell reparative granuloma' of the mandible. On clinical examination the patient was without subjective complaints. Biopsy specimen taken from the lesion showed CGCG.

**Radiographic** imaging with multi-planner CBCT Scan of mandible was performed with 9x16cm FOV and isotropic resolution showed radiolucent lesion on right side of lower jaw, well-defined, extending anteroposteriorly from mesial of 44 to ramus 1cm away from posterior border, superoinferiorly from inferior border of mandible to alveolar crest os 44, 45,46,47 region and 1cm away from sigmoid notch. Lesion measures 72x37x24mm (APxCCxML) in maximal dimensions. Thinning and expansion of buccal and lingual cortex and inferior border of mandible is seen. Inferior alveolar canal is displaced inferiorly and lingually. (Fig. 1).  
Impression – A well defined, expansile, unilocular, expansile, unilocular, radiolucent lesion on the right side of the mandible is S/O benign tumor.

D/D Ameloblastoma, Odontogenic keratocyst, Fibro- osseous lesion, Central giant cell granuloma

The patient was operated under general anaesthesia. Extraoral submandibular incision on the right side was taken. The tumour mass was removed through an extraoral approach and curettage with peripheral osteotomy with preservation of the continuity of the mandible with at least a 5 mm margin was performed (fig 3 and). Teeth 44, 45, 46, 47 were extracted. The inferior alveolar nerve was preserved. Immediate reconstruction was carried out for this case with irradiated alloplastic cortico- cancellous bone graft. The continuity of the mandible was maintained and stability and chances of a pathological fracture was prevented by putting a titanium reconstruction angled plate and titanium screws (Fig. 4). No complication was observed in terms of loss of teeth, wound dehiscence, infection of the surgical site, graft incorporation, fracture or loss of plates and screws and necrosis of bone segments (Fig 5). Prosthetic rehabilitation with implants will be performed.

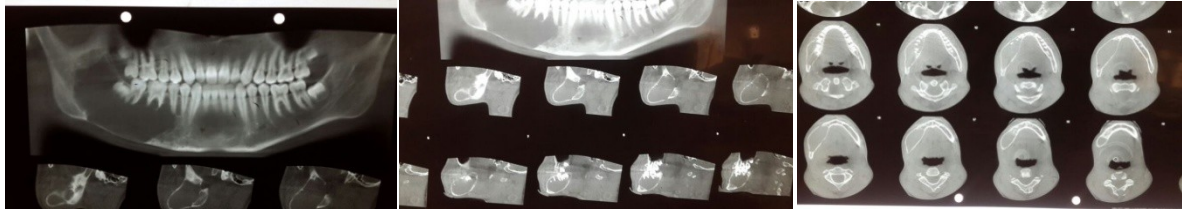

Fig. 1. Radiographic imaging showed radiolucent lesion on right side of lower jaw, well- defined, expansile, unilocular

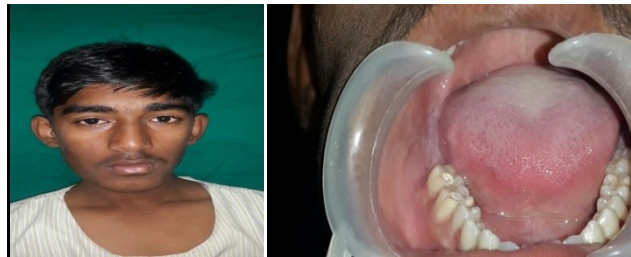

Fig 2 Showing pre-operative extraoral and intraoral views

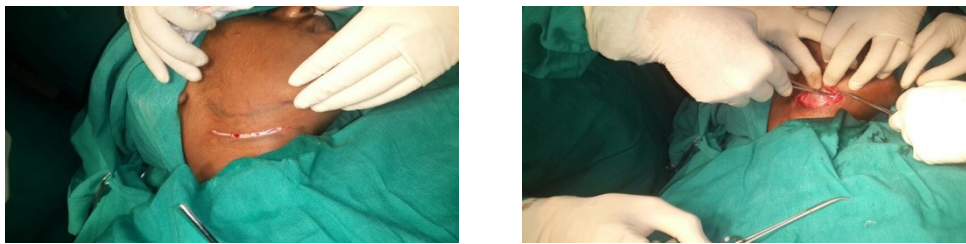


Fig 3 Showing submandibular extraoral incision taken for the surgical procedure.

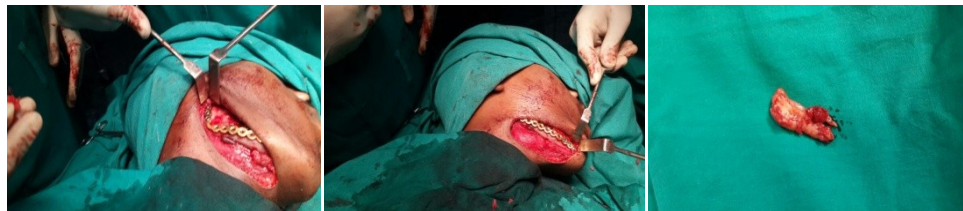

Fig. 4. Intraoperative fixation of the autogenic graft with titanium plate and four screws and removal of the bony lesion

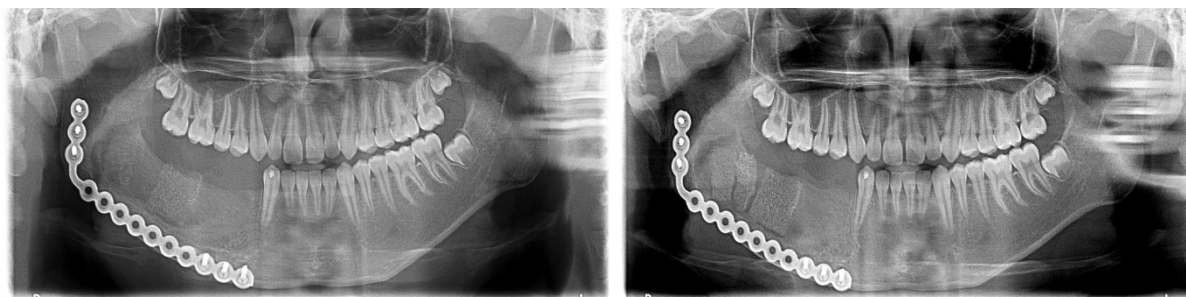

Fig. 5. Postoperative X ray

**Histopathology** report of the resected specimen showed fibrocellular connective tissue wall of mixed density, loose connective tissue in some areas and dense bundles of collagen fibres in most other places. The connective tissue shows many forming blood vessels and multinucleated giant cells (fig 6 ). There is no evidence of epithelial lining. Peripheral bone formation is evident.

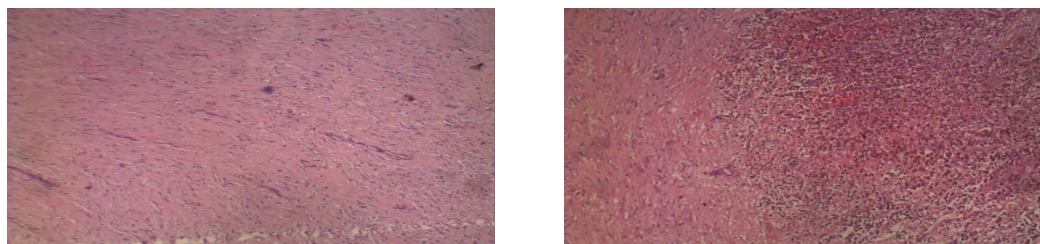


Fig .6 showing the histopathology slides of the lesion with multinucleated giant cell.

#### IV. Discussion:

The true nature of CGCG remains speculative and considerable controversy exists in the literature. Normally, it is not considered an odontogenic lesion. [8] It has been suggested that it might be an inflammatory lesion, a reactive lesion, a true tumour, or an endocrine lesion. [5, 8] one hypothesis suggests that CGCG belongs to the spectrum of mesenchymal proliferative vascular primary jaw lesions. [8] CGCG occurs predominantly in children or young adults,

With approximately 75% of cases presenting before 30 years of age (our patient is 26 years of age), however it really can occur at any age. Females are affected more frequently than males, with a ratio of 2:1 [8] and more than 70% of CGCGs occur in the mandible and less than 30% in the maxilla with a preference for the anterior portions of both bones.[8] Due to the special anatomical characteristics of the maxilla, presentation, diagnosis, progress, management, and prognosis of maxillary CGCG are different from that of mandibular lesions: the cancellous nature of the maxilla and its thin cortical plates allow the lesion to expand much earlier than in the mandible.[8] The radiographic features of maxillary

CGCGs are variable and may be confused with those of other lesions. They have been described as ranging from a unilocular to a multilocular radiolucent appearance with well- or ill defined borders.[10] In the present case of CGCGs, there was a unilocular, radiolucent perforating lesion which did involve the buccal cortical bone. Different authors [10] have classified CGCG into two types, based on clinical and radiographic features. The first is non-aggressive CGCG, which is characterized by a slow, almost asymptomatic growth that does not perforate the cortical bone or induce root resorption and has a low tendency to recur. The second is aggressive CGCG, which is characterized by pain, rapid growth, expansion, and perforation of the cortical bone, radicular resorption and a high tendency to recur. The aggressive lesions are mostly found in younger patients.[2]

Aggressive lesions were also larger in size and from the histological point of view they showed a larger fractional surface area occupied by giant cells. In aggressive lesions also can be found a higher number of giant cells. The most reliable factors which relate to an increased risk of recurrence include clinical activity of lesions (72% of recurrence in the aggressive forms, 3% of recurrence in the non-aggressive forms), young age, presence of perforation of cortical bone and tumour size. [8]

#### V. Conclusion

Currently, no biological markers are known to predict clinical behaviour, and standard histological techniques are not helpful for the clinician to determine the prognosis. Surgery has always been considered to be the traditional treatment and it is still the most accepted. If soft tissues and periosteum are preserved, and only the bony component is excised, then it is possible to reconstruct the surgical defect with irradiated alloplastic cortico-cancellous bone grafts. By doing this bone continuity is maintained and prosthetic rehabilitation via implants can be safely performed.

#### References

- [1]. Chuong R, Kaban LB, Kozakewich H, Perez-Atayde A. Central giant cell lesions of the jaws: a clinicopathologic study. *J Oral Maxillofacial Surg.* 1986 Sep; 44(9):708-713. [Pub Med]
- [2]. De Lange J, van den Akker HP, van den Berg H. Central giant cell granuloma of the jaw: a review of the literature with emphasis on therapy options. *Oral Surg Oral Med Oral Pathol Oral Radiol Endod.* 2007 Nov; 104(5): 603-615. [Pub Med] [CrossRef]
- [3]. Gonzalez-Garcia R, Naval-Gias L, Rodriguez-Campo FJ, Martinez- Chacon JL, Gil-Diez Usandizaga JL. Vascularized fibular flap for reconstruction of the condyle after mandibular ablation. *J. Oral Maxillofacial Surg.* 2008 Jun; 66(6):1133-1137. [Pub Med] [CrossRef]
- [4]. Gungormus M, Akgul HM. Central giant cell granuloma of the jaws: a clinical and radiological study. *J Contemp Dent Pract.* 2003 Aug; 4(3):87-97. [Pub Med]
- [5]. Jaffe HL. Giant-cell reparative granuloma, traumatic bone cyst, and fibrous (fibro-osseous) dysplasia of the jawbones. *Oral Surg Oral Med Oral Pathol.* 1953 Jan; 6(1):159-175. [Pub Med]
- [6]. Rachmiel A, Emodi O, Sabo E, Aizenbud D, Peled M. Combined treatment of aggressive central giant cell granuloma in the lower jaw. *J Cranio- maxillofacial Surg.* 2012 Apr; 40(3):292-7. [Pub Med] [CrossRef]
- [7]. Stavropoulos F, Katz J. Central giant cell granulomas: a systematic review of the radiographic characteristics with the addition of 20 new cases. *Dentomaxillofac Radiol.* 2002 Jul; 31(4):213-7. [Pub Med]

*Surgical Treatment and Reconstruction for Central Giant Cell Granuloma of Mandible- Case Report*

---

- [8]. Tosco P, Tanteri G, Iaquina C, Fasolis M, Rocca F, Berrone S, et al. Surgical treatment and reconstruction for central giant cell granuloma of the jaws: a review of 18 cases. *J Cranio-maxillofac Surg.* 2009 Oct; 37(7):380-7. [Pub Med]
- [9]. Ugrinov R. Oral and maxillofacial surgery, 2006. [In Bulgarian]
- [10]. Whitaker SB, Waldron CA. Central giant cell lesions of the jaws. A clinical, radiologic, and histopathologic study. *Oral Surg Oral Med Oral Pathol.* 1993 Feb; 75(2):199-208. [Pub Med]