

A Prospective, Comparative Study of Outcomes of Primary Endoscopic Dacryocystorhinostomy With and Without mitomycin-C

Santhosh Kumar Prabhakar¹, Ravishankar. C², H. S. Satish³,
Y. Mounika Reddy⁴, Nithyashree. J⁵

^{1,2,3,4,5}Department of ENT, Bangalore Medical College and Research Institute, Bangalore, India

Abstract:

Background and Objectives: Endoscopic DCR is a surgical procedure to drain the lacrimal sac in instances of postsaccular lacrimal obstruction. The most common causes of failure of dacryocystorhinostomy are obstruction at the rhinostomy site and of the common canaliculus. Various methods to prevent the recurrence of obstruction at rhinostomy site following endoscopic dacryocystorhinostomy have been tried such as silicone stent, prolene stent, and use of Mitomycin-C and steroid nasal sprays. Stenting involves more cost and more time consuming, whereas Mitomycin-C appears to be cost-effective and simple procedure to achieve the above result. So we undertook a study to compare the results of Primary Endoscopic DCR with and without Mitomycin-C application to the rhinostomy site.

Methods: The surgical outcomes of Endoscopic DCR with and without Mitomycin-C were compared in forty patients of chronic dacryocystitis who had postsaccular lacrimal obstruction. Mitomycin-C (0.5mg/ml for 15 min) was used in 20 patients, and remaining 20 patients were taken as controls. Follow-up was done at 1st week, 1month, 3months and 6months after surgery. Surgical success was evaluated subjectively and objectively after 6months and results were compared.

Results: The success rate was 90% with Mitomycin-C as compared to 80% without Mitomycin-C. There was no statistical difference in the results of two groups.

Interpretation and Conclusion: Mitomycin-C has no significant beneficial effect in preventing reclosure of the dacryocystorhinostomy stoma after primary endoscopic dacryocystorhinostomy. Meticulous, atraumatic surgical technique is gold standard in achieving a successful surgical result.

Keywords: chronic dacryocystitis, endoscopic DCR, Mitomycin-c

I. Introduction

The endonasal approach to the lacrimal sac was first described by Caldwell in 1893[1]. This approach was further modified by West in 1910[2] and Mosher in 1921[3]. This approach did not gain widespread acceptance because of poor visualization of the lacrimal sac endonasally in the absence of nasal endoscopes, further complicated by bleeding. The endonasal approach to the lacrimal sac was revived by Jokinen and Karja in 1974[4] these authors created an inferiorly based flap on the medial sac wall, which was turned downwards and inferiorly. The above authors (Jokinen and Karja) and Heermann and Neues[5] used an operating microscope for endonasal dacryocystorhinostomy, but this technique did not gain popularity. The development of the rigid nasal endoscope and the advent of functional endoscopic sinus surgery revolutionized nasal and sinus surgery, as it provided excellent visualization of endonasal anatomy, which is the most basic prerequisite for successful endoscopic dacryocystorhinostomy surgery. The application of the rigid nasal endoscope for lacrimal sac surgery was first performed by Mc Donogh and Meiring in 1989[6]. During a routine functional sinus operation, the nasolacrimal duct was inadvertently exposed. This accidental occurrence started a train of thought to apply it in patients with obstruction to the lacrimal sac.

Success rates for endoscopic dacryocystorhinostomy varies from 82% to 95% [7, 8] compared to external dacryocystorhinostomy, which has success rate of >90% [9]. But then along with the above mentioned advantages of endoscopic dacryocystorhinostomy if the success rate can also be enhanced beyond of external dacryocystorhinostomy, then endoscopic dacryocystorhinostomy will clearly be the treatment of choice.

In order to address the issue of enhancing the success rate the causes of failure must be studied in depth. Literature on this subject [10] points to reclosure of the stoma as the most frequent cause for failure of dacryocystorhinostomy. Reclosure is due to scarring, adhesions and granulation tissue formation. Topical application of Mitomycin-C an anticancer drug is said to suppress fibrosis and vascular ingrowth and possibly enhance success rates. Selig and Co-workers [10] have claimed that, when Mitomycin-C in concentrations of 0.2 mg per ml is applied topically to the dacryocystorhinostomy stomal site decreases scarring and adhesions

postoperatively. Hence stomal patency is maintained, decreasing the failure rate of endoscopic dacryocystorhinostomy [10].

Apuhan T[11] and group performed a retrospective study on effect of Mitomycin-C in endoscopic dacryocystorhinostomy, on 43 patients in Turkey, found that Mitomycin-C used in 0.5 mg/ml for 2.5 minutes intraoperatively had a success rate of 91% compared to external dacryocystorhinostomy, which had 71.5% success rate.

Very few studies regarding the efficacy of this drug have been undertaken and further studies are needed to determine and confirm the efficacy of this drug in preventing post-operative closure of the stomal site in the lateral nasal wall. Therefore an attempt is made here to determine whether Mitomycin-C can influence the success rate of endoscopic dacryocystorhinostomy.

II. Patients And Methods

This is a randomized clinical trial done on forty patients with postsaccal obstruction to the lacrimal pathway, between October 2012 and October 2014. This study was conducted at Bangalore Medical College and Research Institute, Bangalore. The subjects chosen after confirmation of obstruction after lacrimal syringing and presence of regurgitation of fluid (mucoid/purulent) on pressing over medial canthus (sac area). The study sample was randomly grouped into two groups, a case (with Mitomycin-C) group and a control (with Mitomycin-C) group. All surgeries were performed under local anaesthesia with sedation after taking informed consent. The follow-up period for patients was done at 1week, 1month, 3months and 6months of post-surgery.

2.1. Surgical technique

All cases were operated under local anesthesia. Topical anesthesia and shrinkage of the nasal mucous membrane is achieved by packing the nasal cavity with strips of cotton pledgets soaked in topical 4% lignocaine with 1:30,000 adrenaline for fifteen minutes prior to surgery. Local anesthetic soaked cotton strips which were inserted earlier are removed. The lateral nasal wall anterior to the middle turbinate is infiltrated (Fig. 1) with 2% lignocaine with 1:1, 00,000 adrenaline to provide adequate anesthesia and vasoconstriction and hence a relatively bloodless field during surgery. The anterior end of the middle turbinate and adjacent septum is also infiltrated with the anesthetic agent. After 10 min 1cm² normal mucosa just in front of middle turbinate is removed using a Blakesley's forceps and bone over the lacrimal sac exposed from nasal side. Now with straight and upturned Kerrison's punches placed in a groove just in front of uncinate process and lacrimal sac is exposed. This is confirmed by seeing movement of sac on pressure over medial canthus. Then remaining bone over the sac is removed keeping in mind that upper end of lacrimal sac usually does not cross the attachment of middle turbinate to lateral nasal wall. Punch cannot be engaged in certain cases, in them bone was removed by chisel and Hammer or by drilling.

After satisfactory exposure of sac the anterior portion of it is incised (Fig. 2) with sharp sickle knife or a 12 no. Blade and removing the medial wall of it with Blakesley's forceps. At this time lacrimal syringing is done to irrigate and remove all purulent material and confirm the free passage for the tears. In patients grouped as cases, a cotton pledgets or gel foam soaked in Mitomycin-C in a concentration of 0.5 mg per ml was placed in the stomal site for 15 minutes (Fig. 4) and later removed. A light nasal packing with ribbon gauze impregnated with Neosporin - H eye ointment was done on the operated nasal cavity.

2.2 Post-operative care and follow-up

The patient is shifted to the ward and is nursed in a semi recumbent position. A broad spectrum antibiotic was given for five days. Systemic decongestants and analgesics are prescribed for three days. The anterior nasal pack is removed after 24 hours and patient is sent home. Topical nasal decongestants applied for 4 times per day for next one week. Antibiotic steroid eye drops one drop every 2 hrs into lower conjunctiva for next 2weeks. This is followed by massage with clean fingers, from 2nd postop day. Crusts and debris in the nasal cavity are removed after 48 hours and the patient is discharged from hospital. The patient is instructed to report back to the operating surgeon after a week for review. During this review, the operated site is endoscopically visualized and any debris or crusts are gently removed atraumatically. The patient is re-examined after one month, three months and 6 months. At each follow-up, the patency of the stoma is determined by subjective resolution of symptoms of the patient and by observing a patent stoma in the lateral wall of the nose, as visualized by nasal endoscopy (Fig. 5).

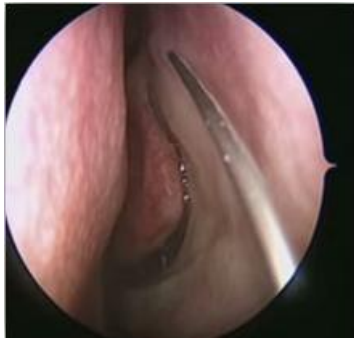

Figure 1: Infiltration of local anesthesia

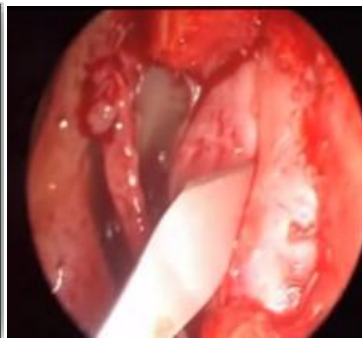

Figure 2: Incision along the sac wall

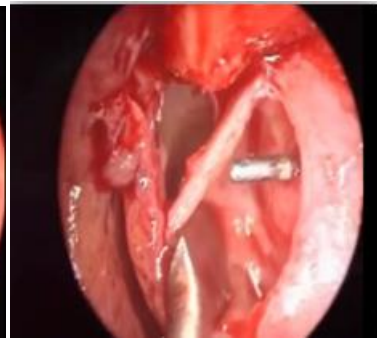

Figure 3: Bowman's probe seen through lacrimal sac opening

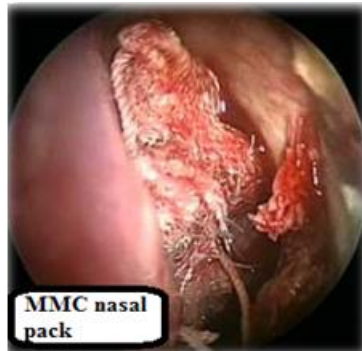

Figure 4: Nasal cavity packed with cotton gauze soaked with Mitomycin-C (MMC)

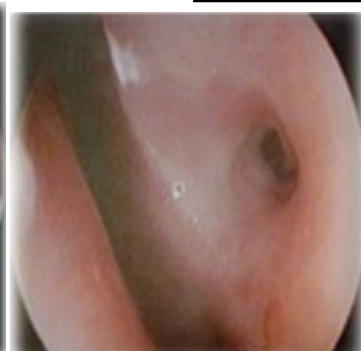


Figure 5: Patent stoma seen during follow-up

There were no major complications in any patient in our study. Synechiae were the only complication of surgery encountered in this study. A total of 6 patients developed synechiae between the lateral nasal wall and anterior end of middle turbinate or nasal septum.

Table 1: Complications

Complications	Case group (n=20)	Control group (n=20)
Synechiae	2 (10%)	4 (20%)

III. Results

After performing endoscopic dacryocystorhinostomy in both the case and control group and following up the patients, the following results were inferred.

Patients were declared a surgical success when there is subjective resolution of all symptoms of lacrimal obstruction and a patent stoma in the lateral nasal wall from which tears are seen to flow with blinking visualized during follow-up endoscopy.

Patients were termed surgical failure when there was persistence or recurrence of symptoms during the follow-up period. The surgically created stoma in the lateral nasal wall had closed during the follow-up period of six months.

The results of our study are shown in Table 2.

Table 2: Results

	Surgical success	Surgical failure
Case group (n=20)	18 (90%)	2 (10%)
Control group (n=20)	16 (80%)	4 (20%)

In the group where Mitomycin-C was applied to the stoma after endoscopic dacryocystorhinostomy (case group), the surgical rate of success following a minimum follow-up period of 6 months was 90%. The surgical success rate in the control group after a minimum follow-up period of 6 months was 80%.

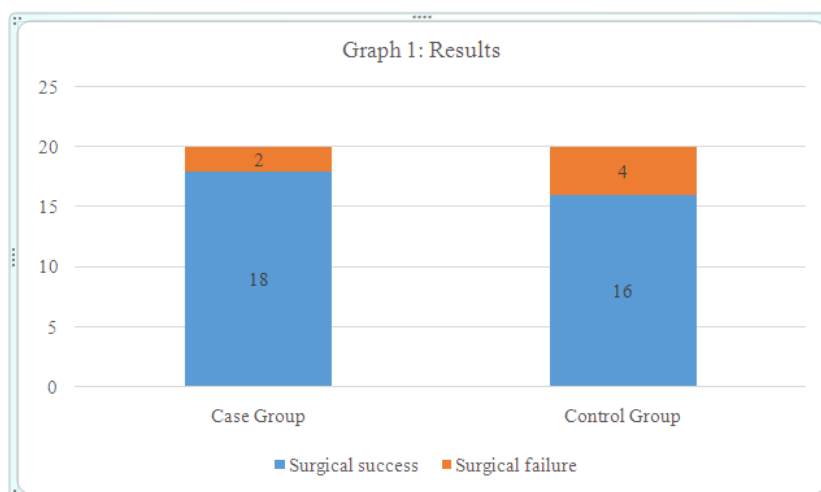


Table 3: Statistical Analysis Of Results

Category	RESULTS		Total	X ² ,p value	CI	Odds ratio
	Surgical Success	Surgical Failure				
Cases	18	2	20	X ² = 0.784 p=0.376	0.362 - 13.971	2.250
Control	16	4	20			

These results were subjected to statistical analysis, on applying Chi-square test, X²= 0.784. ‘p’ value of greater than 0.05 (p > 0.05) was obtained. Therefore the difference in the results of the case group and control group was not statistically significant. Hence these results indicate that there is no significant benefit in using Mitomycin-C as an adjunct to prevent stomal closure in endoscopic dacryocystorhinostomy.

IV. Discussion

The results of endoscopic dacryocystorhinostomy are similar to that of external dacryocystorhinostomy [7, 8] but endoscopic dacryocystorhinostomy has certain distinct advantages such as avoidance of a facial scar, noninterference with the lacrimal pump mechanism, preservation of the medial canthal ligament and simultaneous correction of any intranasal pathology contributing to nasolacrimal duct obstruction.

Failures in endoscopic dacryocystorhinostomy are due to reclosure of the stoma. The application of Mitomycin-c in the form of eye drops as adjunctive treatment for primary and recurrent pterygia after surgical excision is known to be safe and effective[12], this led to use the Mitomycin-C in endoscopic DCR to prevent reclosure of the stoma . Only a few clinical studies, evaluating the efficacy of Mitomycin-C in endoscopic dacryocystorhinostomy have been performed. Camara et al [13] studies showed the success rate of the Mitomycin-C group was statistically significant (p=0.007) and concluded by stating that the intraoperative use of Mitomycin-C in endoscopic dacryocystorhinostomy is safe and also effective. Zilelioglu [14] et al concluded that there is no benefit in using Mitomycin-C in endoscopic dacryocystorhinostomy. Thomas Prasannaraj et al [15] concluded that Mitomycin-C did not appear to influence the occurrence of granulations, synechiae, or obliterative sclerosis, nor did it alter the success rate significantly. Our study revealed no benefit in using Mitomycin-C as an adjunct in primary endoscopic dacryocystorhinostomy. Our experience is that, creating a large stoma by excising the entire medial wall of the lacrimal sac and meticulous surgical technique without causing unnecessary trauma and adjacent raw areas between the lateral nasal wall and middle turbinate/ Septum is sufficient to ensure a good surgical result in the majority of patients. Mitomycin-C can be reserved for patients who come with failure of primary endoscopic DCR surgery.

V. Conclusion

In our study, the results of endoscopic dacryocystorhinostomy with Mitomycin-C were 90% whereas endoscopic dacryocystorhinostomy without Mitomycin-C was 80% after a minimum follow-up period of 3 months. However, this difference in the results is statistically insignificant (p>0.05). Hence we conclude that Mitomycin-C has no significant beneficial effect in preventing reclosure of the dacryocystorhinostomy stoma after primary endoscopic dacryocystorhinostomy. Meticulous, atraumatic surgical technique is gold standard in achieving a successful surgical result. Mitomycin-C can be reserved for patients who come with failure of primary endoscopic DCR surgery.

References

- [1]. Caldwell GW, Two new operations for obstruction of the nasal duct with preservation of the canaliculi and an incidental description of a new lachrymal probe, NY Med J 1893 ; 57 : 581 – 582.
- [2]. West JM. A window resection of the nasal duct in cases of stenosis, Trans Am Ophthalmol Soc 1914; 12: 654.
- [3]. Mosher HP. Re-establishing Intranasal drainage of the lachrymal sac. Laryngoscope 1921; 31: 492 - 521.
- [4]. Jokinen K, Karja J. Endonasal dacryocystorhinostomy. Arch Otolaryngol 1974; 100: 41-44.
- [5]. Heermann J, Neues D. Intranasal microsurgery of all paranasal sinuses, the septum, and the lacrimal sac with hypotensive anesthesia. Ann Oto Rhino Laryngol 1986; 95: 631 - 638.
- [6]. Mc Donogh M, Meiring JH. Endoscopic transnasal dacryocystorhinostomy. J Laryngol Otol 1989; 103: 585 – 587.
- [7]. Wormald PJ. Powered endoscopic dacryocystorhinostomy. Laryngoscope. 2002; 112: 69-72.
- [8]. Eloy P, Bertrand B, Martinez M, Hoebeke M, Watelet JB, Jamart J. Endonasal dacryocystorhinostomy: indications, technique and results. Rhinology. 1995; 33: 229-33.
- [9]. Hurwitz JJ, Rutherford S, Computerized survey of lacrimal surgery patients. Ophthalmology. 1986; 93: 14-9.
- [10]. Selig YK, Biesman BS, Rebeiz EE. Topical application of mitomycinC in endoscopic dacryocystorhinostomy. Am J Rhinol 2000 ; 14(3) : 205-207
- [11]. Apuhan T, Eroglu F, Sipahier A, Yildirim YS. Effect of mitomycin C on endoscopic dacryocystorhinostomy. J Craniofac surg, 2011 Nov; 22(6): 2057-9.
- [12]. Singh G, Wilson MR, Foster CS. Mitomycin drops a treatment for pterygium. Ophthalmology. 1988; 95:813–821.
- [13]. Camara JG, Bengzon AU, Henson RD. The safety and efficacy of mitomycin C in endonasal endoscopic laser assisted dacryocystorhinostomy. Ophthal Plast Reconstr Surg 2000; 16: 114 - 118.
- [14]. Zilelioglu G, Ugurbas SH, Anadolu Y, Akiner M, Akturk T. Adjunctive use of mitomycin C on endoscopic lacrimal surgery. Br J Ophthalmol 1998; 82: 63 - 66.
- [15]. Thomas Prasannaraj, MS, B.Y. Praveen Kumar, DLO, Indira Narasimhan, MS, K.V. Shivaprakash, DLO. Significance of adjunctive mitomycin C in endoscopic dacryocystorhinostomy. American journal of otolaryngology, 2012; 33: 47-50.