

Evaluation of Internal Fixation with Locking Proximal Humerus Plate in Osteoporotic Proximal Humeral Fractures

Dr. Rajeeb Banik¹, Dr. Soumyajit Mondal²

¹(Department of Orthopaedics, North Bengal Medical College, Darjeeling, West Bengal, India)

²(Department of Orthopaedics, North Bengal Medical College, Darjeeling, West Bengal, India)

Abstract:

Objective: To assess the functional outcome of shoulder, time taken for return of activities of daily living, post-operative range of motion and post-operative complications after locking plate fixation of proximal humerus fracture in osteoporotic patients.

Methods: All patients selected for OT underwent pre-operative bone mineral density assessment by ultrasound evaluation of os calcis & grading of osteoporosis according to Singh's index. After proper reduction of main fracture fragments and tuberosities and meticulous repair of rotator cuff, the fractures were fixed with Locking Proximal Humerus Plate (LPHP).

Results: 31 patients (13 male, 18 female) were followed up in this study for 48 months. Constant-Murley scoring system was used. In 27 patients (87%) fracture united within 20 weeks, 4 patients (13%) had delayed union. Majority of patients (75%) returned to activities of daily living (ADL) within 5 months.

Conclusion: The implant was designed to improve screw fixation and minimize soft tissue dissection. Locking Proximal Humerus Plate attempts to achieve these aims through a combination of multidirectional locking screws for head, precontoured plate, and locking screws in the shaft. So internal fixation of proximal humeral fractures with use of the LPHP yields satisfactory results when utilized correctly.

Keywords: Osteoporotic, Bone mineral density assessment, Singh's index, Constant-Murley scoring, Locking Proximal Humerus Plate.

I. Introduction

Proximal humeral fractures account for approximately 5% of all fractures. More than 70% of patients with these fractures are older than sixty years of age, and 75% are women. In the elderly population, most of these fractures are related to osteoporosis. Proximal humeral fractures have a dual age distribution occurs either in young people following high energy trauma or in those older than 50 years with low velocity injuries like simple fall [1,2]. Three fourths of the fractures occur in older individuals with an occurrence three times more often in women than in men [1,3]. The ultimate goal of treatment should be minimum shoulder pain and maximum range of motion.

Non-displaced/Minimally displaced/Stable proximal humeral fractures can be treated non-operatively successfully with early rehabilitation. But severely displaced and comminuted fractures warrant surgical management for optimum shoulder function. Treatment of this complicated fracture is guided by bone quality, fracture pattern, degree of comminution as well as patient factors such as age and activity level. Surgical options include closed reduction and percutaneous pinning (CRPP), transosseous suture fixation (TOSF), open reduction and internal fixation with either conventional or locking plate and hemiarthroplasty. Locking Proximal Humerus Plate (LPHP) is precontoured to the anatomy of the lateral aspect of the proximal humeral metaphysis and functions to assist internal fixation by securing an anatomic reduction with angular stability. The objective of the present prospective observational study is to evaluate the functional outcome and the complication rate after internal fixation of proximal humeral fractures of osteoporotic patients with the Locking Proximal Humerus Plate.

II. Materials & Methods

A total of 34 cases (15 male, 19 female) attending either outdoor or emergency were selected on the basis of selection criteria. 3 patients (2 male, 1 female) were lost during follow up. Ultimately 31 patients (13 male, 18 female) were evaluated in this study during 2009-2013.

Patients with Singh's index of osteoporosis grade II to IV and t score below (-1) were included in the study having displaced two-part, three-part and four-part proximal humerus fractures. Non-displaced stable fractures (Angulation < 45° and displacement < 1cm), fractures with minimal displacement involving only the greater or lesser tuberosity, open fracture, pathological fracture, concomitant ipsilateral fracture of the distal part of the humerus, fracture-dislocation of shoulder, old and debilitated patients with co-morbid conditions were

excluded from the study. After admission thorough history was taken particularly mode of injury and associated other injury and detailed clinical examination was done. Trauma series X-ray was done to determine the fracture pattern.

All patients selected for the operation underwent pre-operative bone mineral density (BMD) assessment by ultrasound evaluation of os calcis & grading of osteoporosis according to Singh's index. All patients received a prophylactic dose of 1.5gm cefuroxime intravenously preoperatively.

The operation was done under general anesthesia in a radiolucent table in supine position with small sand bag under shoulder.

Fracture was exposed through delto-pectoral approach. Fracture fragments were reduced without stripping periosteum to maximum possible achievable anatomical position and reduction was held with Kirschner wires. Reduction was checked under image intensifier. Definitive fixation with locking proximal humeral plate was done with plate positioned lateral to bicipital groove sparing tendon of long head of biceps and 1 cm distal to the upper end of greater tubercle to avoid subacromial impingement & rotator cuff damage. Plate was fixed with screw at longitudinal dynamic hole. After achieving near anatomical reduction, multidirectional screws were used to fix proximal fragments. Subchondral placement of the proximal screws and the quality of the reduction was confirmed with fluoroscopy. For fractures with medial comminution, a superiorly directed oblique locked screw in the infero-medial region of the proximal fragment provided medial column support and prevented varus malposition.

Meticulous repairs of the rotator cuff, capsule and subscapularis muscle tears/avulsions were carried out, if found pre-operatively. Lesser tuberosity was fixed with a separate screw/wire if found avulsed. Range of motion of shoulder was checked on the table for impingement. Wound was closed under negative suction, which was removed after 48 hours.

The post operative rehabilitation protocol included active and passive range of motion exercises as early as the pain subsides followed by passive and active assisted range of motion exercises up to 60° of abduction and elevation with no forced external rotation for 6 weeks in an arm pouch sling. Active exercises were started at 6 weeks depending on the stability of osteosynthesis and quality of bone.

The patients were followed up at 15 days, then monthly for minimum 6 months & then 6 monthly intervals up to 48th month. Radiographs were obtained and evaluated for bony healing, non-union, malunion, loosening of implant, loss of reduction and avascular necrosis of head of humerus. Assessment regarding loss of reduction was done comparing the immediate postoperative radiographs and those taken at the time of the final follow-up. Assessment and analysis of any complications including axillary nerve injury and impingement due to plate was done. Functional outcome was assessed according to Constant-Murley score. This scoring system consists of four variables that are used to assess the function of the shoulder. The right and left shoulders are assessed separately.

The subjective variables are pain (15 pts) and ADL (20 pts) which give a total of 35 points. The objective variables are range of motion (40 pts) and strength (25 pts) which give a total of 65 points. Range of motion consists of forward flexion, abduction, ext. rotation & int. rotation having 10 points each. The Constant-Murley score was graded as poor (0-55 points), moderate (56-70), good (71-85), or excellent (86-100).

III. Results And Analysis

31 patients (13 male, 18 female) were followed up for 48 month (2009-2013) in the study. Majority of patients (35%) were in the age group 61-65 & male: female ratio was 1:1.38. Most of fractures (52%) were caused by fall. Rests were caused by road traffic accident, seizure. Majority of fractures (45%) were 2-part fractures, 42% of all patients had Singh's grade II osteoporosis, 46% all patients (14 out of 31) had t score < (-3). Most of the patients (55%) were operated within 2 weeks.

All fractures united without any secondary operation. In 27 patients (87%) fracture united within 20 weeks, 4 patients (13%) had delayed union.

Majority of patients (75%) returned to activities of daily living (ADL) within 5 months. Most patients obtained reasonably well post-operative range of motion, painless mobility, and fair strength of shoulder. According to Constant score 10% had excellent result, 52% had good result, 32% had moderate outcome & 6% had poor outcome.

Final result according to Constant score--when the results were related to fracture classification, two-part fractures had the higher average Constant-Murley score (81 points) as compared to three-part fractures (69 points) & four part fractures (62 points).

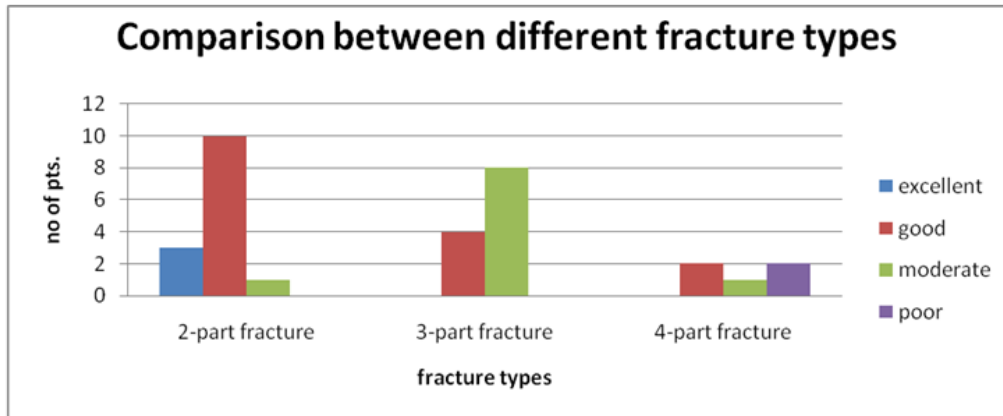
Table 1 : Average mean Constant score according to grade of osteoporosis in Singh`s index

Singh`s grades of osteoporosis	Approx. mean Constant score	Result
IV	83	Good
III	75	Good
II	64	Moderate

One way ANOVA shows significant difference in mean Constant score among 3 groups (F=13.39, df=30, p=0.001).

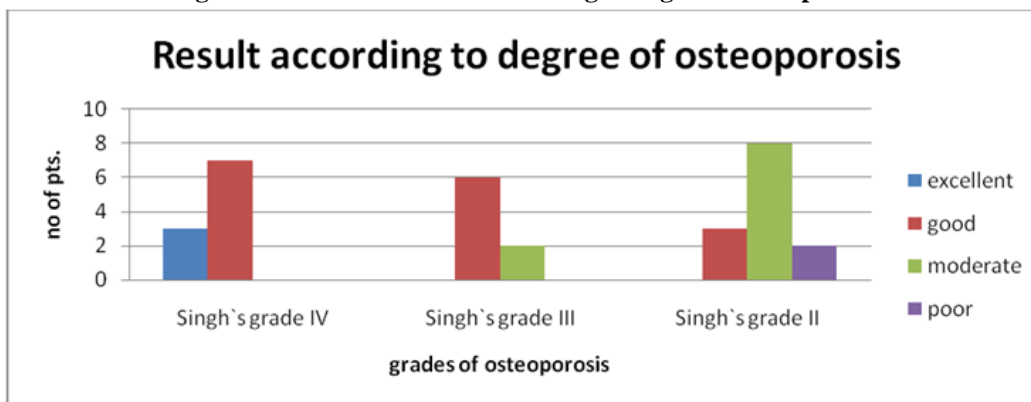
According to BMD assessment, mean constant score was 83,74,71,61 respectively in (-2.5) < t score < (-1), (-3) ≤ t score ≤ (-2.5), (-3.5) ≤ t score < (-3), t score < (-3.5). One way ANOVA shows significant difference in mean Constant score among 4 groups (F = 9.746, df =30, p = 0.000).

Fig.1: Constant score of different fracture



Chi square test suggests significant association (chi square = 23.39, df = 6, p= 0.001).

Fig 2: Final Constant score according to degree of osteoporosis



Chi square test suggests significant association (chi square = 19.43, df = 6, p= 0.003).

Whereas lower t score (-2.5<t score<-1) shows 3 excellent and 7 good result, higher t score (t score < -3.5) obtains only 1good, 4 moderate and 2 poor results. Chi square test shows significant association between BMD category & result. (Chi square = 22.28, df = 9, p=0.008).

Out of 31 patients, 3 patients (10%) had primary varus fixation during operation, 3 patients (10%) had wound infection. No patients had axillary nerve palsy or humeral head necrosis till follow up. Loss of reduction was observed in 1 patient (3%) due to implant failure. However the fracture united without the need of refixation. In 23 patients (74%) fracture healed uneventfully.

Better results were obtained in 2-part fractures, Singh`s grade IV, t score between (-1) to (-2.5). Poor outcome was obtained in 2 patients with 4 part fractures with advanced osteoporosis (Singh`s grade II) and t score < (-3.5) and complicated by wound infection.

Table 2: Final outcome at 48th month

Patient nos.	Fracture type (Neer`s)	Singh`s index	BMD Estimated (t score)	Abduction (terminal)	Flexion (terminal)	Int. Rotation	Mean Strength percentage	Mean Constant Score	Average time taken for union
6	2-part	Grade IV	-2.43≤t≤ -1.55	150°	140°-150°	thumb touching T7	81.33%	87.33	4 months
2	3-part	Grade IV	-1.98≤t≤ -1.26	150°	135°-150°	thumb touching T12	68%	77.5	5 months
2	4-part	Grade IV	-2.22≤t≤ -1.76	120°-140°	120°-150°	thumb touching T12	72%	74.5	4 months
6	2-part	Grade III	-3.03≤t≤ -2.73	120°-150°	120°-150°	thumb touching T12	71.33%	78.33	4months
1	3-part	Grade III	-2.98	120°	120°	thumb touching L3	64%	64	6months
1	4-part	Grade III	-2.78	120°	120°	thumb touching L3	64%	68	6 months
2	2-part	Grade II	-3.47≤t≤ -3.11	100°-120°	100°-120°	thumb touching T12	72%	70.5	5months
9	3-part	Grade II	-3.69≤t≤ -3.12	100°-135°	100°-135°	thumb touching T12	64.89%	67.33	5months
2	4-part	Grade II	-3.85≤t≤ -3.57	90°	90°	thumb touching L3	48%	46	6 months

IV. Discussion

Proximal humeral fractures represent an increasing challenge for the health-care system because of the increasing proportion of elderly individuals in the population. As estimated by a Finnish study group, the number of fractures may triple by the year 2030 [4].

The majority of patients with these fractures are more than sixty years old and most of the proximal humeral fractures in this population are related to osteoporosis. Displaced proximal humeral fractures in elderly patients pose a challenge to treatment when associated with osteoporosis and comminution. Osteoporosis predispose to low energy fractures which often have a complex pattern [5]. Poor bone quality makes screw purchase and fixation less secure [6]. The decreased healing capacity in osteoporosis is reflected in a dramatic increase in the rate of failure of implant fixation [7].

Some authors have reported excellent results after conventional plate osteosynthesis of proximal humeral fractures (Wanner et al. 2003) [8]. This method has also been associated with a high complication rate, however, particularly in elderly patients with comminuted fractures (Cofield 1988) [9]. The technique often requires an extensive soft tissue stripping which may compromise the vascular supply to the humeral head. On the other hand less invasive methods such as closed reduction and percutaneous pinning require advanced skills and good bone quality, minimal fracture comminution and a cooperative patient (Herscovici et al. 2000) [10]. In the elderly population with osteoporosis, this method has also yielded poor outcome.

There was a prospective study performed by Ramchander [11], a total of 25 patients (12 males and 13 females) with displaced proximal humeral fractures were operated using LPHP. According to Constant score, 28% had excellent outcome, 64% had good functional outcome, and 8% had moderate outcome. When the results were related to grades of osteoporosis, grade IV osteoporotic fractures had highest average Constant-Murley score (83 points, range 78–88 points), followed by grade III osteoporotic fractures (80 points, range 71–92 points), followed by grade II osteoporotic fractures (78 points, range 66–88 points). Varus malalignment and subacromial impingement were observed in 8% patients. Loosening of implant and loss of reduction were observed in 4% patients. Superficial infection was observed in 4% patients.

Another retrospective study by Frangen [12] involved 92 patients (57 women and 35 men, mean age 75.4 years, range 70-96 years) were followed-up clinically and radiologically. Of the 92 followed patients 48 had a 3-part fracture, and 44 patients had a 4-part fracture. They underwent primary internal fixation with an angle-stable plate (Königsee, Aschau, Germany). The mean Constant-Murley score was in the upper range of a satisfactory final result : 69.8(± 20) points (range 22-94 points). The mean age-adjusted Constant-Murley score was 75.2% ±13 % (range 47.5-94.0%).

In our study 31 patients (13 males & 18 females) were included. According to Constant score, 10% had excellent result, 52% had good result, 32% had moderate outcome & 6% had poor outcome. Only 2 patients with 4 part fracture and low BMD (t Score< -3.5) or Singh`s index of grade II had poor outcome (Constant score < 56). 2 patients who had poor outcome also had infection which later controlled by wound debridement & antibiotics. The functional outcome was better in the 2 or 3 fragment fracture group than in patients with 4-part fractures in our series. Also, as expected, the mean Constant score declined with increasing severity of osteoporosis (Singh`s grade II) and t score < (-3.5).

Poor result in 6% patients in our study may be due to inadequate fracture reduction especially of the tuberosities in 4 part fractures and unstable fixation or incorrect positioning of the fixation devices in fairly advanced osteoporotic patients (Singh's index grade II) and t score < (-3.5).

V. Conclusion

There is consensus in the literature that, regardless of the procedure and the implant chosen, a good functional final result depends decisively on anatomical reduction of the fracture combined with a stable fixation, and early initiation of functional rehabilitation of the shoulder.

The main challenge in the operative treatment of proximal humeral fractures is to achieve effective stabilization of an adequately reduced fracture in order to maximize the functional result. If an adequate reduction is not achieved and medial buttressing is insufficient, especially with a varus malreduction, secondary loss of reduction and subsequent screw perforation or plate breakage is possible [13]. The locking of the screws onto the plate prevents the screws from backing out. So, if the fracture collapses, the screws may penetrate the articular surface. This penetration may be more likely if the screws are placed very close to the articular surface or if the articular surface was penetrated during drilling.

This suggests that LPHP is associated with satisfactory results in fractures of proximal humerus of osteoporotic patients. Although the small number of patients in our series is a limitation, poorer outcome was observed in fractures with fairly advanced osteoporosis (Singh's index grade II) as compared to fractures with mild osteoporosis (Singh index grade IV). This suggests that there is need for further improvement in management of osteoporotic proximal humeral fractures.

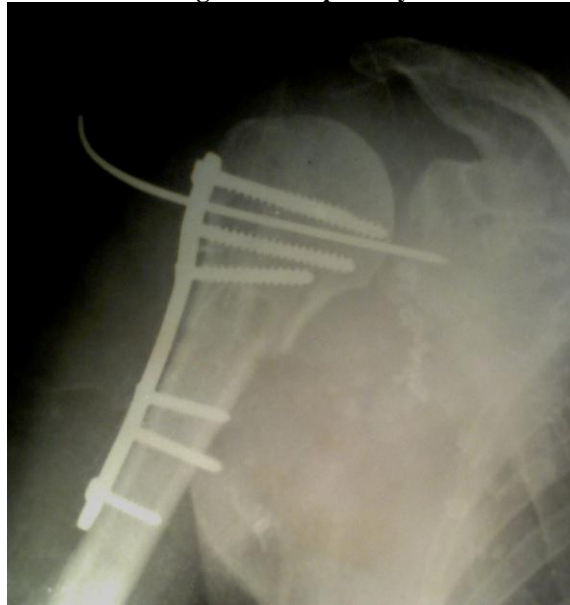
References

- [1]. Chu SP, Kelsey JL, Keegan TH, et al. Risk factors for proximal humerus fracture. *Am J Epidemiol.* 2004 ;160:360–367.
- [2]. Broadbent MR, Will E, McQueen MM Prediction of outcome after humeral diaphyseal fracture. *Injury.* 2010 Jun;41(6):572-7.
- [3]. Lind T, Kroner K, Jensen J. The epidemiology of fractures of the proximal humerus. *Arch Orthop Trauma Surg.* 1989;108(5):285–.
- [4]. Palvanen M, Kannus P, Niemi S, Parkkari J. Update in the epidemiology of proximal humeral fractures . *Clin Orthop Relat Res.* 2006 Jan;442:87-92.
- [5]. Hertel R (2005) Fractures of the proximal humerus in osteoporotic bone. *Osteoporos Int* 16(Suppl 2) :S65–S72
- [6]. Szyszkowitz R, Seggl W, Schleifer P, Cundy PJ (1993) Proximal humeral fractures.Management techniques and expected results. *Clin Orthop Relat Res.* 1993 Jul;(292):13-25.
- [7]. Giannoudis PV, Schneider E (2006) Principles of fixation of osteoporotic fractures. *J Bone Joint Surg Br.* 2006 Oct;88(10):1272-8.
- [8]. Wanner GA, Wanner-Schmid E, Romero J, Hersche O, von Smekal A, Trentz O, Ertel W. Internal fixation of displaced proximal humeral fractures with two one-third tubular plates. *J Trauma.* 2003 Mar;54(3):536-44.
- [9]. Cofield R H. Comminuted fractures of the proximal humerus. *Clin Orthop Relat Res.* 1988 May;(230):49-57.
- [10]. Herscovici D Jr, Saunders DT, Johnson MP, Sanders R, DiPasquale T. Percutaneous fixation of proximal humeral fractures . *Clin Orthop Relat Res.* 2000 Jun;(375):97-104.
- [11]. Ramchander Siwach, Roop Singh ,Rajesh Kumar Rohilla, Virender Singh Kadian ,Sukhbir Singh Sangwan , Manjeet Dhanda Internal fixation of proximal humeral fractures with locking proximal humeral plate (LPHP) in elderly patients with osteoporosis. *J Orthopaed Traumatol* (2008) 9(3):149–153
- [12]. Thomas Manfred Frangen, Ernst Josef Müller, Marcel Dudda, Stephan Arens, Gert Muhr, Thomas Kälicke .Proximal humeral fractures in geriatric patients. Is the angle-stable plate osteosynthesis really a breakthrough ?. *Acta Orthop. Belg.,* 2007, 73, 571-579.
- [13]. Agudelo J, Schürmann M, Stahel P, Helwig P, Morgan SJ, Zechel W, Bahrs C,Parekh A, Ziran B, Williams A, Smith W. Analysis of efficacy and failure in proximal humerus fractures treated with locking plates. *J Orthop Trauma.* 2007 Nov-Dec;21(10):676-81.

Fig 3: 3-part fracture (Rt), 55yr, female

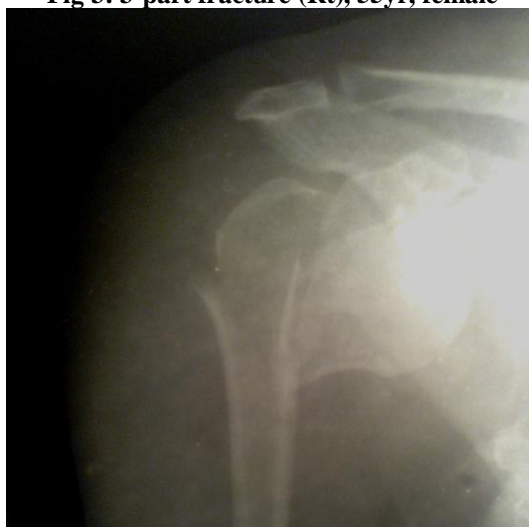

Fig 4: Post-op X-ray



5: 4-Part fracture (Rt), 58 year, male

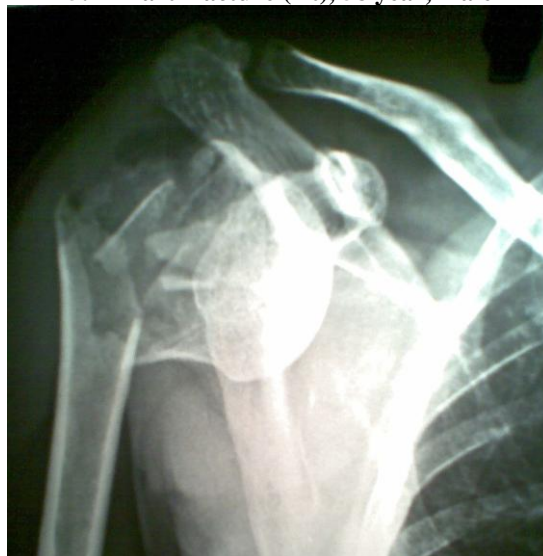

Fig 6: Post-op X-ray

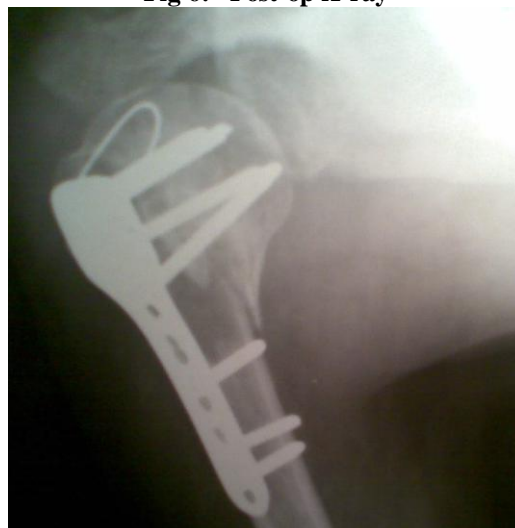

Fig 7: 2-Part fracture(Rt), 60year, male

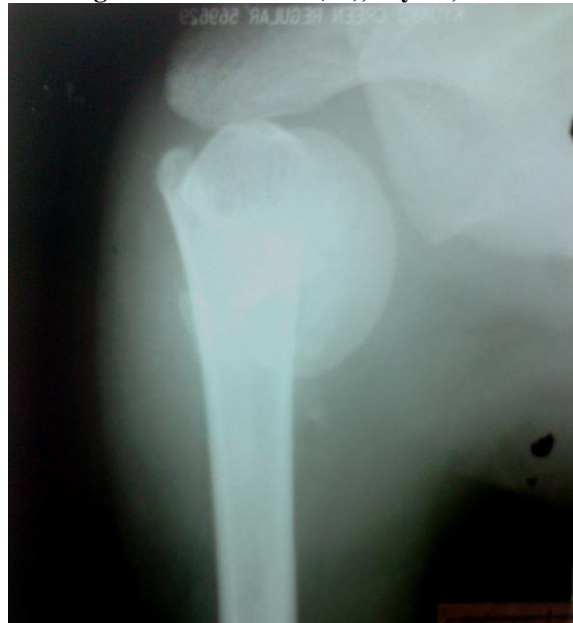

Fig 8: Follow-up after 3 year

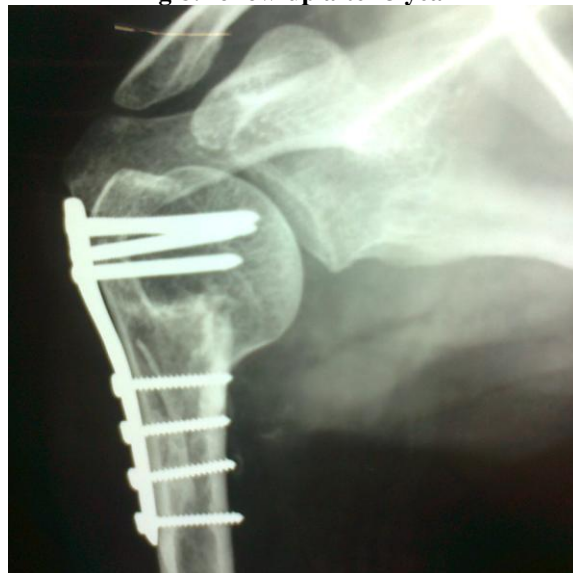

Fig 9: Clinical photographs after 48th month



