

Study Ofmanagement of Epistaxis in a Tertiary Care Hospital

Dr. M. Deepthi¹, Dr. G. V. R. N. Krishna Kanth², Dr. Ch. Abhinandandutt³

Kamineni Institute Of Medical Sciences Narketpally, Nalgonda District -508254 ;

Mgm Hospital, Warangal, Andhra Pradesh, India.

Abstract:

Objective: To study the Management of the patients presenting with Epistaxis.

Methods: An observational study was conducted among randomly selected 200 patients presented with epistaxis to a tertiary care hospital in south India. After the initial resuscitation of patients ,they are investigated to identify the etiology and grouped according to further management.

Results: Age and sex distributions among various etiologies of Epistaxis was studied and was found to be more common in males when compared to females (male : female = 2.7 : 1).Epistaxis is seen in all age groups more so in the adolescents and young adults .Most common cause is Trauma(37%), next common is Idiopathic(29.5%).Hypertension was the most common systemic cause for epistaxis , followed by Bleeding diathesis .Most (71%) of the cases are managed conservatively, next common intervension is Anterior nasal packing.

Conclusion: All patients of epistaxis should be evaluated to find the cause by taking proper history and investigations. Routine investigations must include complete haemogram ,coagulation profile ,liver function tests and renal function tests and Diagnostic Nasal Endoscopy in every case of epistaxis.Treatment of severe epistaxis can encompass many modalities depending upon its site, severity and etiology.

Keywords: Epistaxis Management, Nasal packing.

I. Introduction

Epistaxis (Greek for nosebleed) is the relatively common occurrence of hemorrhage from the nose, usually noticed when the blood drains out through the nostrils. There are two types: anterior (the most common), and posterior (less common, more likely to require medical attention). Sometimes in more severe cases, the blood can come up the nasolacrimal duct and out from the eye. Fresh blood and clotted blood can also flow down into the stomach and cause nausea and vomiting.

The arterial supply to nasal cavity involves branches from both the external (ECA) and internal (ICA) carotidarteries [1] (Fig. 1A,1B). The ECA contributes most of its supply via the internal maxillary (sphenopalatine and greaterpalatine branches) and facial arteries. The ophthalmic artery, usually a branch of the ICA, can supply the nasal cavity via the anterior and posterior ethmoidal arteries. The sphenopalatine artery serves as the major vessel supplying via the lateral and medial branches. The lateral branches supply the inferior, middle, and superior turbinates; the medial or septal branches supply the nasal septum .Kiesselbach's plexus, also known as Little's or Kiesselbach's area, is a localized region of mucosa of the anteroinferior nasal septum. It is supplied by branches of the Anterior Ethmoidal, sphenopalatine, greater palatine, and facial arteries and is the site of most anterior epistaxis (Fig. 1A).

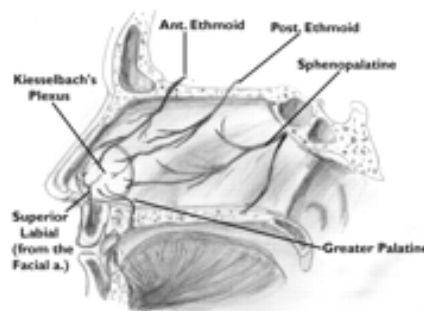


Fig. 1A. Showing Arterial blood supply of nasal septum. Ant. = anterior, Post. = posterior, a. = artery.

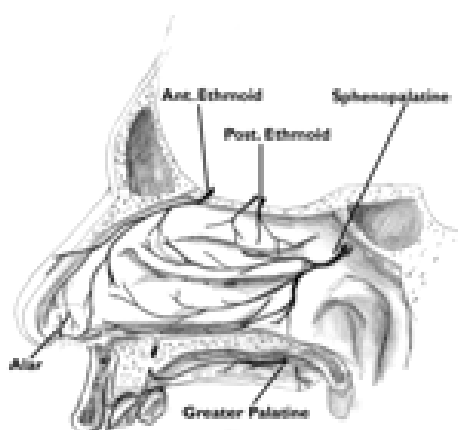


Fig. 1B.Showing Arterial blood supply of lateral nasal wall. Ant. = anterior, Post. = posterior, a. = artery.

Treatment:

Most hemorrhage from the nose stops spontaneously by the natural processes of vessel wall contraction and blood clotting, only few ask for medical aid. Such aid may be enlisted to stop recurrent minor bleeds or to control a serious persistent epistaxis[2]. A variety of methods of conservative treatment of persistent epistaxis are available, one of the measures must surely work and that if all fails then a surgical intervention must certainly do the deed[3].

Initial management

It depends on a number of factors including duration, amount, location of the source of bleeding, the presence of co-factors such as coagulopathy and hypertension and previous treatment. Increase the humidification of the mucosa and application of an ointment to the anterior nose at morning and night, to allow the bleeding site to heal. This is based on the assumption that dryness is one of the most important factors causing epistaxis. In between ointments nasal saline is sprayed every 2 to 3 hours. Treatment is usually focused on the cause of the nosebleeds, and may include [4]:

- Controlling blood pressure
- Closing the blood vessel using heat, electric current, or silver nitrate sticks
- Nasal packing
- Reducing a broken nose or removing a foreign body
- Reducing the amount of blood thinners or stopping aspirin

If the above measures fail then specific investigations are done.

First Aid Measures Include TROTTER'S MANOUVRE where Stable patients after initial resuscitation are asked to sit up and should be instructed to pinch the nose to compress the soft tissues against the nasal septum, maintaining continuous pressure for at least 10 minutes. This is called as **Hippocratic Technique**[5]

Treatment Options:

- Medical management
- Nasal packing using
 - Traditional anterior pack
 - Nasal sponges
 - Gelfoam
 - Traditional posterior pack
 - Nasal balloon
- Caution
 - Silver nitrate
 - Endoscopic Electro cauterization
 - Laser cautery
- Embolization
- Ligation
 - Transantral ligation of internal maxillary artery

- External ligation the ethmoid arteries
- Endoscopic ligation of the sphenopalatine artery
- Ligation of the external carotid artery
- Surgery
- Septoplasty
- Septaldermoplasty
- Excision of tumors

Management protocols for acute epistaxis:

Anterior bleeding can be divided into mild, moderate and severe bleeding.

- **Mild:** cauterize/ medical therapy. Packing is not usually necessary but may need to be performed in case of failures.
- **Moderate and severe bleeding:** initial therapy is to cauterize and then place a pack.
- **Severe life threatening epistaxis or epistaxis that requires multiple transfusions:** vessel ligation or embolization should be considered as an initial option.

Posterior bleeding can be divided into mild, moderate and severe bleeding.

- **Mild:** medical treatment alone or cauterization can be performed for those in whom medical treatment is unsuccessful.
- **Moderate:** endoscopic cautery is appropriate.
- **Severe:** place a pack to control the bleeding initially and then perform ligation or embolization.

Management protocol for chronic and recurrent epistaxis:

If the bleeding source is identified: this can be again classified into **anterior or posterior bleeds.**

- **Anterior bleeding:** medical therapy is tried first. If this fails then cautery followed by placement of an anterior pack and if this fails then ligation is recommended.
- **Posterior bleeding:** medical therapy is tried first. If this fails then endoscopic cautery is attempted and if this fails then feeding vessel ligation or Embolisation is recommended.

If the site of bleeding has not been definitively identified, Nasal Endoscopy is indicated. If this fails to identify the bleeding site then a trial of medical therapy is indicated. If this approach fails to stop the bleeding then a CT scan is indicated to document the presence or absence of tumours. In the absence of a diagnosis and continued bleeding despite medical therapy, placement of an anterior pack with or without posterior pack followed by bilateral vessel ligation is indicated.

Initial treatment attempts may include chemical or electric cautery of distal branches and the bleeding site [6]. When cautery is unsuccessful, nasal packing may be necessary. The relatively high failure rate of anterior nasal packing for superior and posterior epistaxis is not surprising because the posterior extent of an anterior nasal packing is limited and may not tamponade the posterior turbinates. More aggressive use of posterior packing with inflatable balloon packs tamponades more of the nasal fossa. However, packing has a reported failure rate of 26-52% [7,8]. In addition, posterior nasal packing has caused severe complications such as alar and septal necrosis, aspiration, sinusitis, exacerbation of sleep obstructive apnea, and pack-induced hypoxia [6,7,8]. Alternatively, studies of posterior endoscopic cauterization report success rates of 80-90% [6].

Studying endovascular therapy for idiopathic intractable epistaxis in 30 patients, Vitek [9] found an 87% success rate after embolization of the internal maxillary artery and a 97% success rate (with a 3% complication rate) after embolization of the internal and facial arteries. Embolic materials frequently used for treatment of epistaxis include Gelfoam (Upjohn, Kalamazoo, MI) pieces, polyvinyl alcohol particles (149-250 µm), platinum coils or a combination of materials [10]. Failure of endovascular treatment of epistaxis is often related to continued bleeding from the ethmoidal branches of the ophthalmic artery. Embolization of these branches is contraindicated because ophthalmic artery embolization carries a high risk of blindness. However, the surgeon can ligate the ethmoidal vessels as they perforate the medial wall of the orbit [6]. The idiopathic or spontaneous form of epistaxis is the most common cause, often related to cigarette use, hypertension, and atherosclerotic disease. Although hypervascularity is commonly seen, angiographic demonstration of the bleeding point (extravasation) is rare [11].

Juvenile angiofibroma is the most common benign tumor arising from the nasopharynx and comprises 0.5% of all head and neck neoplasms [12]. Angiography and embolization before surgery can reduce surgical blood loss, improve visualization of the surgical field, and result in a more complete and uncomplicated resection. A solitary fibrous tumor of the nasopharynx is a rare cause of epistaxis. This spindle cell tumor has pathologic features similar to those of angiofibromas, hemangiopericytomas, and fibrous histiocytomas [13].

II. Aims And Objectives

1. To study the Age distribution of patients of Epistaxis referred to MGMH Warangal during the study period of 1½ years ie; from January 2009 to July 2010 .
2. To determine distribution of various Etiologies of Epistaxis among the study group.
3. To study distribution of various modalities of Management among various Etiologies.

III. Material

Patients referred to MGMH Warangal among inpatient ,out patient and Emergency departmentwith complaint of Epistaxis during the period of one and half year ie; between January 2009 to June 2010.

- ENT instruments .
- Hopkins rod rigid nasal endoscopy instruments with 0 degree and 30 degree scopes with camera attachment and cold light source.
- Digital camera

Methods

TYPE OF STUDY : Observational study.

CRITERIA OF SELECTION :

Inclusion criteria :Random selection of patients coming to MGMH with complaints of Epistaxis, to Out patient department , Emergency and Inpatient departments.

Exclusion criteria :

- Absconded patients.
- Patients refusing Admission and those not consenting for surgical intervention.

Methods:

The study group of patients are selected randomly and those requiring admission are admitted for management. Patients are examined after the initial measures to control bleeding .All admitted patients both in ENT department and Other departments with complaint of Epistaxis are subjected to routine tests like-Complete blood picture with total leucocyte count and platelet count and Bleeding and Clotting time estimation ,Erythrocyte Sedimentation tests, Renal function tests like Blood urea and Serum creatinine, Random blood sugar ,X –Ray Paranasal sinuses, Diagnostic nasal endoscopy using 0 and 30 deg scopes , and HIV and HbsAg tests . Those patients with suspicion of specific cause are subjected to specific tests to diagnose the cause of bleeding like Liver function tests ,Ultrasonogram of abdomen ,CT scan of Paranasal sinuses. All patients of Idiopathic and Hypertensive Epistaxis and those patients whose bleeding is not controlled by conservative measures and nasal packing are subjected to additional tests like- Coagulation profile ,and if found abnormal, serum levels of specific clotting factors are estimated. Patients with tumour causing epistaxis were treated by exision of tumour and biopsy sent for histopathological examination to know the type of tumour.

IV. Results

In the present study 200 cases of epistaxis referred to out patient ,inpatient and casualty blocks of Mahatma Gandhi Memorial Hospital, warangal ,were studied during the period from January 2009 to July 2010.

Among the study group (200 cases),**Male : Female = 146 : 54 = 2.7 : 1.** Here the majority of cases (86) were in the age group of 21-40 yrs emphasizing that epistaxis is a problem more common among adolescents and young adults and more common among males.

Fig 2:

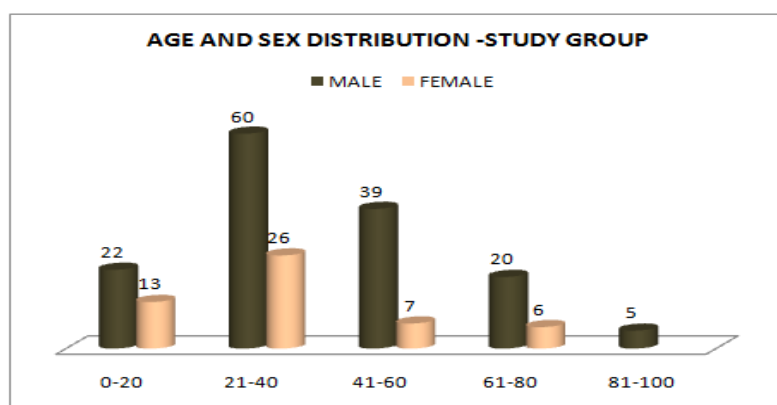
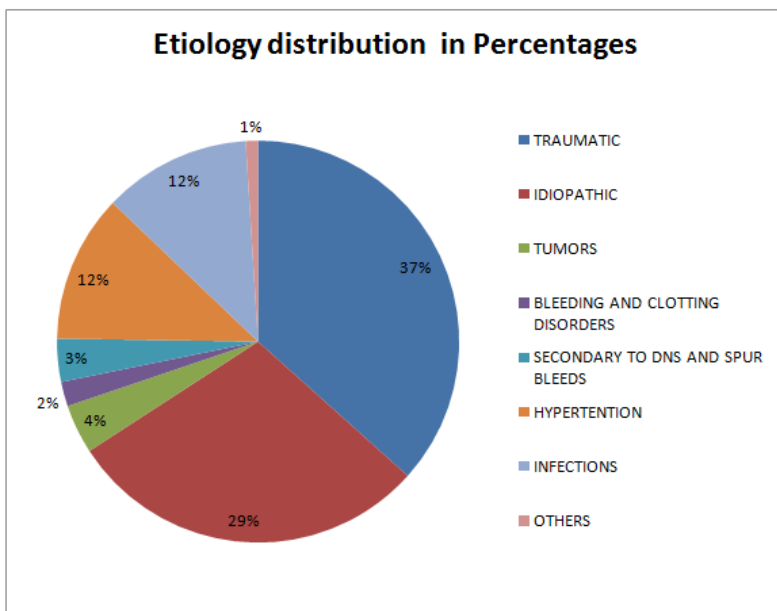


Fig 3: Etiology Distribution



A) **Traumatic Cases:** Finger nail trauma (12 cases) is observed among 0- 20 year age group ie; among children and adolescents. blunt trauma (62 cases) is more common in 21-40 year age group ie; adolescents and young adults.

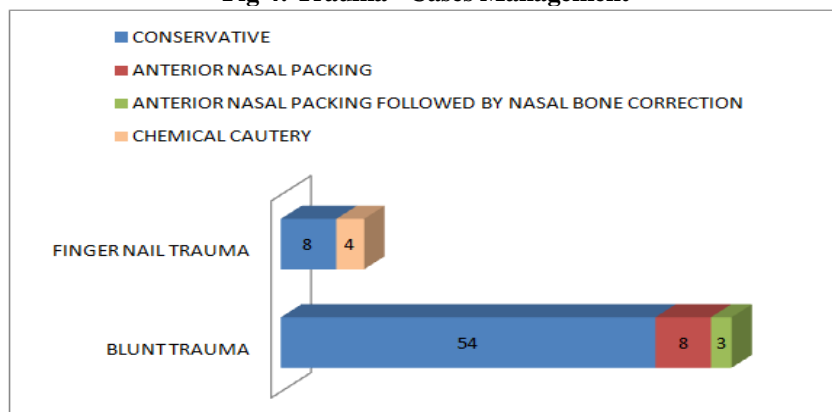
Table I: Trauma Cases Management:

TYPE OF TRAUMA (NO. OF PTS)	CONSERVATIVE			CHEMICAL CAUTERY			ANTERIOR NASAL PACKING ALONE			ANTERIOR NASAL PACKING FOLLOWED BY NASAL BONE CORRECTION LATER		
	M	F	T	M	F	T	M	F	T	M	F	T
BLUNT TRAUMA (62)	46	8	54	-	-	-	6	2	8	2	1	3
FINGER NAIL TRAUMA (12)	4	4	8	3	1	4	-	-	-	-	-	-
TOTAL (74)	50	12	62	3	1	4	6	2	8	2	1	3

M - MALES ; F - FEMALES ; T - TOTAL

Most of the cases of blunt trauma are managed conservatively. Only 6 patients had fracture in the nasal bones, all of them required anterior nasal packing. But only 3 of them required both anterior nasal packing and nasal bone correction 2 or 3 days later. Out of 12 cases of finger nail trauma, only 4 of them required chemical cauterisation of bleeder in the out patient department.

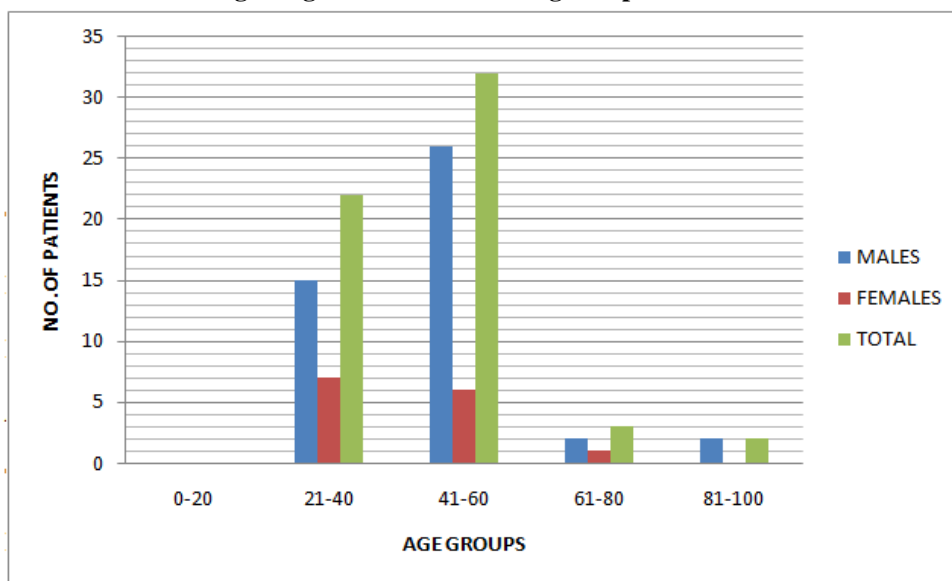
Fig 4: Trauma Cases Management



B) Idiopathic Cases:

Among the study group of 200 cases , 59 cases (Male : female = 45 :14) are labelled as Idiopathic, seen commonly among 41-60 years ie; middle age group

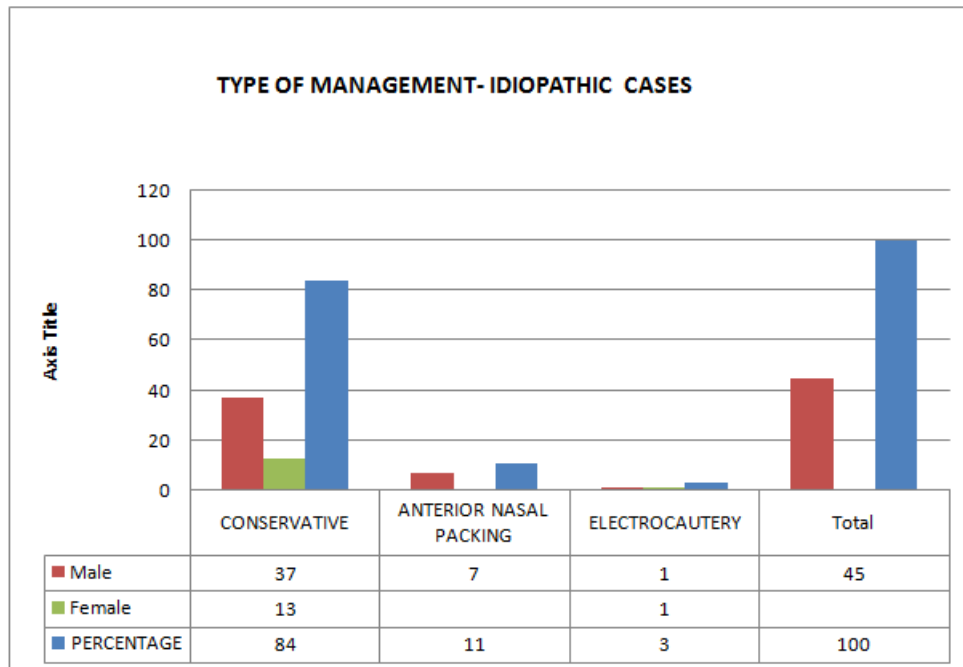
Fig 5: Age Distribution Among Idiopathic Cases



Treatment options : Idiopathic Cases

- Out of 59 cases , 50 cases (84 %) required only conservative management .7 patients (11%) required anterior nasal packing . 2 patients (3%) required electro cauterisation with bipolar insulated nasal cautery

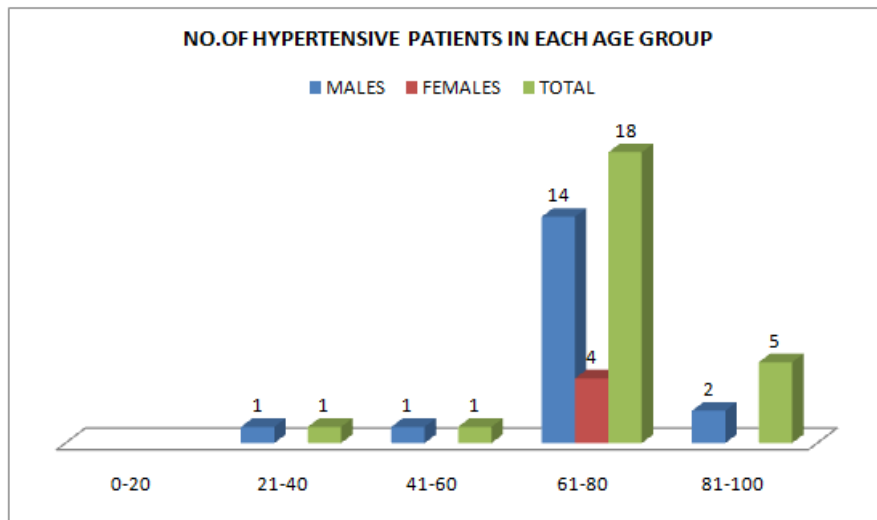
Fig 6 : Management Of Idiopathic Cases



C) Hypertension Epistaxis

Hypertension is more common in 61 -80 year age group, and common among males (Males : Females = 18 : 4 = 4.5 : 1). Among 22 patients of epistaxis, 13 were managed conservatively. 8 patients required anterior nasal packing . One patient required both anterior and posterior nasal packing.

Fig 7 : Age Distribution Among Hypertensive Patients

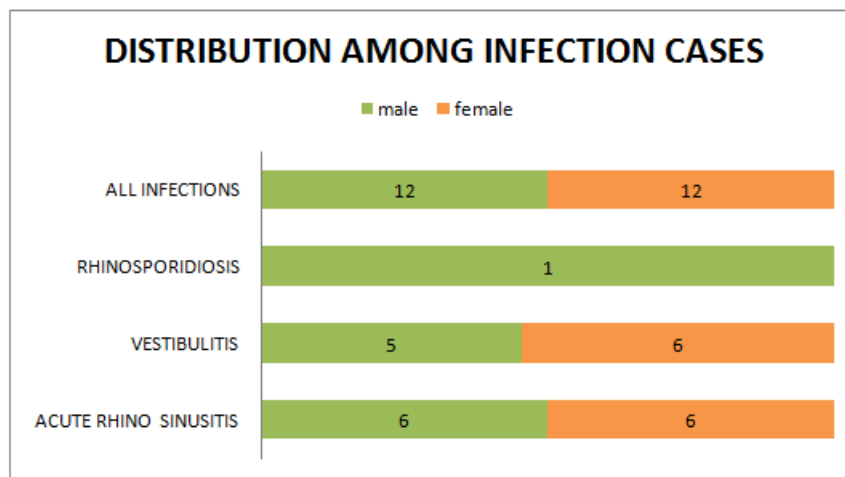


D) Infections Causing Epistaxis :

Total number of cases are - 24 ;male : Female = 1:1.

These include acute rhino sinusitis ,vestibulitis ,and Rhinosporidiosis

Fig 8 : Number Of Patients - Infections



Among 12 patients of acute rhino sinusitis ,all were managed conservatively. Among 11 patients of vestibulitis , all of them belong to 0 -20 year age group. Almost all of them were managed conservatively (medically), except 2 patients of vestibulitisrequired Chemical Cauterisation in the out patient department. Bleeding and coagulation disorders were seen in 4 patients . seven patients presented with septal spur ,septoplasty was done for them.Eight patients presented with tumours (2,3, 2 ,1 number of cases of Nasopharyngeal Angiofibroma,Haemangioma,Maxillary sinonasaladeno carcinoma , Inverted papilloma respectively).All tumoursare managed by Trans Nasal Endoscopic Excision and Cauterisation whenever necessary .

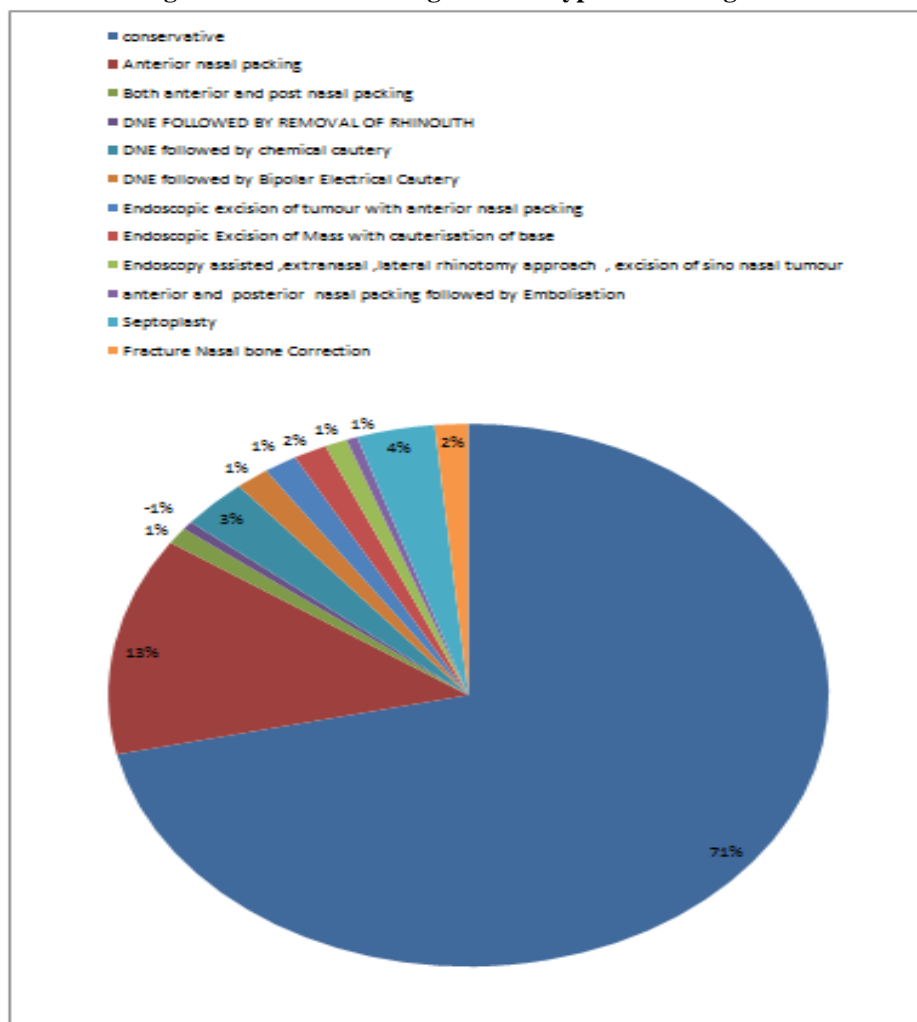
Table II: Distribution Among Tumours

TUMOUR TYPE	MALE	FEMALE	TOTAL
Nasopharyngeal Angiofibroma	2	-	2
Haemangiomas	2	1	3
Maxillary sinonasaladeno carcinoma	2	-	2
Inverted papilloma	1	-	-

General examination revealed rise of blood pressure in 22 patients with hypertension, was in the range of 180 – 220 mm Hg systolic and 90 – 130 mmHg diastolic. Moderate to severe anemia was present in 3 patients who had recurrent and persistent bleeding for more than 3 to 4 months.

Routine investigations, Diagnostic Nasal Endoscopy and Coagulation profile were done in all cases except those of finger nail trauma and vestibulitis who are treated on Out patient department. X Ray ParaNasalSinuses , X Ray Nasal Bones ,Computed Tomography (CT) of PNS were done to whomever necessary. Angiography was performed in one patient with intractable epistaxis with the diagnosis of post septoplasty epistaxis. This was followed by embolization by interventional radiologist, and the bleeding was controlled. Biopsy was taken in all patient with mass nasal cavity and excision biopsy in cases of rhinosporidiosis and Nasopharyngeal Angiofibroma and Haemangioma.

Fig 9: Distribution Among Various Types Of Management



Conservative medical management without any surgical intervention was performed in 143 patients (50 ,62 ,21,13 cases among Idiopathic,trauma, infections ,Hypertension group respectively). Trotter’s manoeuvre and cottonpledgets soaked in normal saline or topical vasoconstrictive agents (botro clot) was placed in the causality as an emergency procedure.

Anterior nasal packing was done for 26 cases of epistaxis in the casualty. This group includes 4 ,8,7,7 number patients of bleeding diathesis ,hypertensive ,idiopathic ,trauma respectively. This does not include 19 postoperative patients in whom an anterior nasal pack was placed to achieve hemostasis immediately after nasal surgery for tumors ,nasal bone fractures and septal spur bleeds.

Both Anterior and Posterior nasal packing was done in 2 patients (1 case of Hypertensive epistaxis other was Mid face Lefort fracture with fracture nasal bones). One patient of post septoplasty required Anterior and Posterior nasal packing followed by Embolisation of internal maxillary artery.

Diagnostic nasal endoscopy followed by bipolar Electro cauterization was done for 3 patients. It helps in easy and instant diagnosis of the patient and avoids the discomfort of the anterior nasal pack . Endoscopic

excision of the mass followed by cauterization of its base was done for 2 patients of haemangioma septum. Chemical cauterization was done for 6 patients (2, 4 number of patients of vestibulitis, finger nail trauma respectively)

Septoplasty was done in 7 patients. Nasal bone correction were performed in 3 patients. 2 Patients of Sinonasal tumour was treated with Extranasal Lateral rhinotomy approach excision.

V. Conclusions

From the present study we come to the conclusion that epistaxis is a problem seen in all age groups more so among young males (male : female = 2.7 : 1). Trauma is the most common (37%) cause of epistaxis, next common is Idiopathic. Among children and adolescents, common causes of epistaxis are finger nail trauma and Vestibulitis. Among younger adults (21- 40 yrs), blunt trauma, acute infections and spur bleeds are common. Among middle age group, Idiopathic and trauma are common. Among elderly age group (61-80 yrs), Hypertension and tumours are the common causes.

Little's area is the commonest site of bleeding but the site of bleeding was undetermined in a large majority of patients even after the use of the endoscope.

Most of the bleeds can be controlled by Conservative or Medical management (71%) but those with active bleeders can be managed by cauterisation, Packing, embolisation and or surgery. Anterior nasal packing (13%) was the most common intervention in our study. Endoscopic cautery can be used to control the bleeding in cases of idiopathic epistaxis if the bleeding point is visualized. This modality of treatment causes less discomfort to the patient and less hospital stay. We should manage a case of epistaxis in an orderly manner and every effort should be made to find out the cause before deciding to go to the next modality of management.

References

- [1]. Osborn A. The nasal arteries. *AJR* 1978;130:89-97[Abstract]
- [2]. Johnson F: The control of adenoid hemorrhage with a Foley catheter. *Archives of otolaryngology*. 63, 295; 1956.
- [3]. Mayer D.M; Swanker W.A: postoperative nasal bleeding. *Archives of otolaryngology*. 54, 384 – 389; 1951.
- [4]. Zohar, Yuva et al: surgical management of epistaxis in hereditary hemorrhagic telangiectasia. *Archives of otolaryngology*. 113 No. 8; 754 – 757; 1987.
- [5]. Gerald W McGarry, Scott-Brown's Otorhinolaryngology, Head and Neck Surgery, 7th Edition, VOL.2-A; Part 13,126; 1596 1599,1603 -1604.
- [6]. Emanuel JM. Epistaxis. In: Cummings CW, Fredrickson JM, Harker LA, Krause CJ, Richardson MA, Schuller DE, eds. *Otolaryngology head and neck surgery*, 3rd ed. St. Louis: Mosby, 1998:852-865
- [7]. Wang L, Vogel DH. Posterior epistaxis: comparison of treatment. *Otolaryngol Head Neck Surg* 1981;89:1001-1006[Medline]
- [8]. Schaitkin B, Strauss M, Houck JR. Epistaxis: medical versus surgical therapy—a comparison of efficacy, complications, and economic considerations. *Laryngoscope* 1987;97:1392-1396[Medline]
- [9]. Vitek JJ. Idiopathic intractable epistaxis: endovascular therapy. *Radiology* 1991;181:113-116[Abstract/Free Full Text]
- [10]. Kagetsu NJ, Berenstein A, Choi IS. Interventional radiology of the extracranial head and neck. *Cardiovasc Intervent Radiol* 1991;14:325-333[Medline]
- [11]. Lasjaunias P, Marsot-Dupuch K, Doyon D. The radio-anatomical basis of arterial embolization for epistaxis. *J Neuroradiol* 1979;6:45-53[Medline]
- [12]. Davis KR. Embolization of epistaxis and juvenile nasopharyngeal angiofibromas. *AJNR* 1986;7:953-962
- [13]. Zukerberg LR, Rosenberg AE, Randolph G, Pilch BZ, Goodman ML. Solitary fibrous tumor of the nasal cavity and paranasal sinuses. *Am J Surg Pathol* 1991;15:126-130[Medline]