

## Case Report- Intra Uterine Pregnancy with 3<sup>rd</sup> Degree Uterine Prolapse with Placenta Previa

Arohan Sapkota<sup>1</sup>, L. Ranjit Singh<sup>2</sup>, Swati Sharma<sup>1</sup>.

1 Postgraduate trainees, 2 Professor, Department of Obstetrics and Gynaecology, Regional Institute of Medical Sciences, Manipur university, lamphelpat, Imphal, 795004 Manipur, India

**Abstract:** Uterine prolapse that occurs during pregnancy is a rare condition. Fewer than 300 cases have been reported in the literature. Incidence of uterine prolapse in pregnancy is 1 in 10 000-15 000 deliveries worldwide. Although a rare occurrence, there is still a need for obstetricians to be aware of the management of uterine prolapse which allows for an uneventful pregnancy, labour and delivery. Here we present a case of uterine prolapse in pregnancy and the issues surrounding her management.

**Keywords:** Uterine prolapse, placenta previa,

### I. Introduction

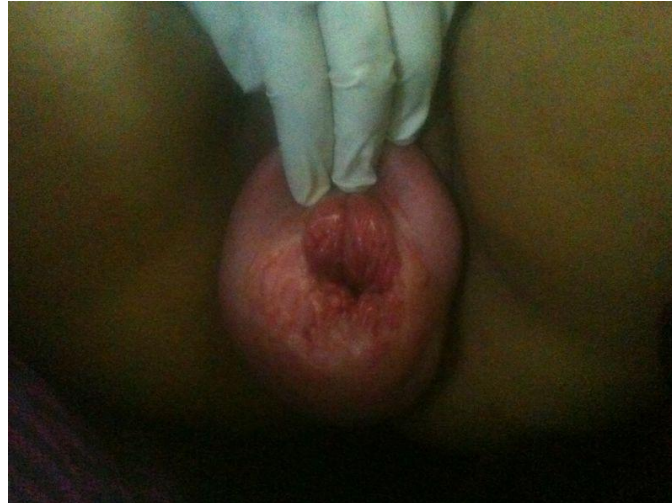Uterine prolapse that occurs during pregnancy is a rare condition. Fewer than 300 cases have been reported in the literature. Incidence of uterine prolapse in pregnancy is 1 in 10 000-15 000 deliveries worldwide [1]. It is hypothesised that the descent of the uterus is initially associated with prolongation of the cervix followed by descent of the body of the uterus [2]. Although a rare occurrence, there is still a need for obstetricians to be aware of the management of uterine prolapse which allows for an uneventful pregnancy, labour and delivery. Currently, there is no clear guidance on the management of this condition. Here we present a case of uterine prolapse in pregnancy and the issues surrounding her management.

### II. Case Report

A 31 year old Indian lady gravida 3 para 1, with 1 preterm delivery, with 1 living issue, at period of gestation 28 week with uterine prolapse with placenta previa. Her 1<sup>st</sup> child was delivered vaginally 12 years back at 7<sup>th</sup> month pregnancy, baby had hydrocephalus, died after birth. Second child was delivered vaginally 8 years back. The patient had no history of uterine prolapse prior to the current pregnancy. In the 27<sup>th</sup> week of gestation, patient noticed a protrusion from her vagina. The patient had no other symptoms regarding bladder and bowel habits. The patient was able to reduce the protrusion regularly. The patient presented with complaint of protrusion per vaginum, with spotting. The os of the prolapsed cervix was closed and elongated. At maximal straining, the prolapse was approximately 8 cm below the level of the hymen. There was no active bleeding on inspection, the patient was admitted and kept under observation.. After one day the patient started having active bleeding per vaginum, and the patient was taken up for emergency caesarean section under general anaesthesia. Intraoperatively placenta was anterior low lying reaching the OS, with approximately 150 ml retroplacental clots. A single live male baby was delivered, apgar score at birth was 4/ 10 and baby was admitted in NICU. A total of 2 packed rbc was transfused. Post operative period was uneventful, prolapsed returned normal postpartum and patient was discharged on 5<sup>th</sup> postoperative day.




Fig .1 Prolapse with Gravid Uterus



**Fig 2.** Mild Blood stained spotting



**Fig 3.** Prolapse gravid uterus with features suggestive of low lying placenta

### **III. Discussion**

Literature review of uterine prolapse in pregnancy describes clinical features of pelvic pressure, lower back pain, urinary tract symptoms (e.g. acute retention, incontinence), cervical inflammation and cervical mucosal ulcerations. Similarly, complications reported range from patient discomfort, cervical desiccation and ulceration, urinary tract infection, acute urinary retention to miscarriage and even maternal death[3].

Traditional Chinese methods of treating prolapse involved the Chinese Native doctors saturating the protruding portion of the cervix with kerosene oil and setting fire to it. The resulting dense scar tissue of the cervix required multiple incisions to deliver the babies with forceps[3]. Undeniably, we have come a long way in the management of uterine prolapse coincident with pregnancy.

The prolapsed uterus is usually managed by reducing the prolapse and bed rest in a slight Trendelenberg position. These methods have shown to protect the cervix from trauma and desiccation and decrease the incidence of preterm labour[5]. This has been widely recommended in several papers, including Piver and Spezia[9] and Daskalakis et al.[3]. After reduction is accomplished, authors such as Sawyer[8] and Piver & Spezia[9] recommend placement of a well-fitting lever or doughnut pessary, which will often allow the patient to continue with the pregnancy without much trouble[3].

However, in this case with Mrs XYZ as the patient presented with placenta previa with bleeding, the patient was taken up for caesarean section immediately. It is apparent that over the years, normal vaginal deliveries have increased and the need for forceps has decreased[9]. Literature review shows that the majority of women are delivered by normal vaginal delivery.

Uterine prolapse coincident with pregnancy & mode of delivery (1968-2008)

Figure 4

Author & ref no	Year	No of patients	Delivery	Infant	Complications
Piver MS & Spezia J <sup>2</sup>	1968	8	SVD	Alive	Cervix & 3 <sup>rd</sup> perineal lacerations
			SVD	Alive	Cervical lacerations
			SVD	Alive	Cervical lacerations
			C.section (emergency)	Alive	2 <sup>nd</sup> inertia; puerperal endometritis
			SVD	Alive	Cervical laceration; retained placenta
			SVD	Alive	0
			SVD	Alive	0
Lavery JP <sup>12</sup>	1973	1	SVD	Alive	Prolonged labour
Hill PS <sup>3</sup>	1984	1	SVD	Alive	PROM
Brown HL <sup>6</sup>	1997	2	SVD	Alive	Preterm labour
			SVD	Alive	Preterm labour + PROM
Matsumoto <sup>7</sup>	1999	1	SVD	Alive	0
Sawyer D <sup>8</sup>	1999	1	SVD	Alive	Induced labour at 40+1 weeks
Yogev Y <sup>4</sup>	2003	2	C. section (elective)	Alive	Cervical lacerations, desiccations + oedema
			C. section (elective)	Alive	Cervical lacerations, desiccations + oedema
Guariglia L <sup>1</sup>	2005	1	SVD	Alive	0
Daskalakis G <sup>1</sup>	2007	1	C. section (elective)	Alive	0
Partsiavelos GA <sup>2</sup>	2008	1	C. section (emergency)	Alive	0

However, it is essential for the obstetrician to look out for the presence of cervical inflammation or oedema which may complicate a vaginal delivery, especially if there is inadequate time for sufficient antepartum treatment. Daskalakis[3] in 2007 suggested elective Caesarean section near term to avoid further pelvic floor damage, especially where the cervix is oedematous and elongated. Therefore, obstetricians need to look out for these complications in a timely manner. If there are no such complications the decision ultimately lies with the patient[3],[4].

#### IV. Conclusion

Uterine prolapse in pregnancy is a rare occurrence and best managed conservatively. This is usually attained with bed rest and placement of an appropriate pessary.. When considering the mode of delivery, obstetricians should look out for cervical inflammation and oedema which may complicate an otherwise normal vaginal delivery.

#### References

- [1]. Yogev Y, Horowitz ER, Ben-Haroush A, Kaplan B. Uterine cervical elongation and prolapse during pregnancy: an old unsolved problem. Clin Exp Obstet Gynecol 2003; 30(4): 183-5
- [2]. Partsiavelos GA, Mesogitis S, Papantoniou N, Antsaklis A. Uterine prolapse in pregnancy: a rare condition an obstetrician should be familiar with. Fetal Diagn Ther 2008; 24(3):296-8
- [3]. Daskalakis G, Lymberopoulos E, Anastasakis E, Kalmantis K, Athanasaki A, Manoli A, Antsaklis A. Uterine Prolapse complicating pregnancy. Arch Gynecol Obstet 2007 Oct; 276(4): 391-2
- [4]. Guariglia L, Carducci B, Botta A, Ferrazzani S, Caruso A. Uterine prolapse in pregnancy. Gynecol Obstet Invest 2005; 60(4): 192-4
- [5]. Hill PS. Uterine prolapse complicating pregnancy. A case report. J Reprod Med 1984 Aug; 29(8):631-3
- [6]. Brown HL. Cervical prolapse complicating pregnancy. J Natl Med Assoc 1997 May; 89(5):346-8
- [7]. Matsumoto T, Nishi M, Yokota M, Ito M. Laproscopic treatment of uterine prolapse during pregnancy. Obstet Gynecol 1999 May; 93(5 Pt 2):849
- [8]. Sawyer D, Frey K. Cervical Prolapse During Pregnancy. J Am Board Fam Pract 13(3):216-218, 1999
- [9]. Piver MS, Spezia J. Uterine prolapse during pregnancy. Obstet Gynecol 1968;32:765-9
- [10]. Keettel WC. Prolapse of the uterus during pregnancy. Am J Obstet Gynecol 1941;42:121-6
- [11]. Tomezsko JE, Sand PK. Pregnancy and intercurrent diseases of the urogenital tract. Clin Perinatol 1997;24:343-68
- [12]. Lavery JP, Boey CS. Uterine prolapse with pregnancy. Obstet Gynecol. 1973 Nov;42(5):681-3{full\_citation}