

Severe Posterior Open Bite by Posterior Folding of the Retrodiscal Tissue: A Case Report

Fumihiro Matsumoto¹, Yukihiro Momota¹, Hideyuki Takano², Keiko Aota¹, Koichi Kani¹, Chika Kondo¹, Tomoko Yamanoi¹, Nao Takase¹, Yuki Miyamoto¹, Shinji Ono¹, Yoshiko Yamamura³, Hidehiko Hosoki⁴

¹(Department of Oral Medicine, Institute of Biomedical Sciences, Tokushima University Graduate Faculty of Dentistry, Japan)

²(Oral Health Management Center, Tokushima University Hospital, Japan)

³(Department of Oral Surgery, Institute of Biomedical Sciences, Tokushima University Graduate Faculty of Dentistry, Japan)

⁴(Department of Oral and Maxillofacial Radiology, Institute of Biomedical Sciences, Tokushima University Graduate Faculty of Dentistry, Japan)

Abstract: We report a case of sudden mouth-closing disturbance during the final phase of occlusion in a 32-year-old woman who visited the Department of Oral Medicine, Tokushima University Hospital, with a chief complaint of a bilateral posterior open bite with pain in her right temporomandibular joint (TMJ). After a big yawn in March 2010, the patient was unable to occlude her posterior teeth. Magnetic resonance imaging revealed posterior folding of the retrodiscal tissue, normal disk position, and slight joint effusion in the right TMJ. The posterior open bite was not improved with non-surgical methods (i.e., diet modification, resting of the jaw, and medications). Five days after the initial visit, the patient was treated with the pumping manipulation technique to the upper joint cavity of the right TMJ. The treatment was effective for moderate reduction of the posterior open bite and the patient showed almost complete recovery in the fourth week.

Keywords: Magnetic resonance image, Posterior folding of the retrodiscal tissue, Posterior open bite, Pumping manipulation technique, Temporomandibular joint

I. Introduction

Displacement of the temporomandibular joint (TMJ) disk is a well-known characteristic of internal derangement in temporomandibular disorders (TMDs)[1,2]. Magnetic resonance imaging (MRI) is usually employed to discern the direction of disk displacement, and the most common form of internal derangement is anterior disk displacement (ADD)[3-5]. However, the frequency of TMD with posterior disk displacement (PDD) is low [6-9]. Furthermore, it has been reported that in ADD, the retrodiscal tissue within TMJ is enlarged forward and received mechanical stimulation. In such cases, mechanical stimulation occurs between the mandibular condyle and mandibular fossa, resulting in the formation of excess fibrous connective tissue[10]. On the other hand, there are several reports on mouth-closing disturbances caused by disk displacement, such as PDD[6-9] or fibrotic retrodiscal tissue[11-13]. Here, we report a rare case of an acute severe posterior open bite caused by sudden recapture of the disk and posterior folding of the retrodiscal tissue (PFRT).

II. Case Report

A 32-year-old woman visited the Department of Oral Medicine, Tokushima University Hospital because of bilateral posterior open bite with severe pain in her right TMJ. While yawning one day in March 2010, she reported that she “thought her jaw was going to pop off” and subsequently quickly closed her mouth. At that moment, she heard the characteristic TMJ clicking sound and was unable to occlude her posterior teeth. She immediately consulted a neighboring dental clinic and was diagnosed with subluxation of the TMJ. It was suggested that she visit our clinic on the same day. Although she did not remember the period of being aware of clicking, she reported a history of clicking in the right TMJ with chewing or yawning. Otherwise, the patient had no significant medical history.

Physical examination revealed a maximal interincisal distance of 40 mm with tenderness and severe pain in the right TMJ on mouth closing. An intraoral view showed an edge-to-edge bite, a bilateral posterior open bite of approximately 5-6 mm at the level of the right first molar and deviation to the left of the mandible median line (Fig. 1a, b, c). Radiographic examination showed a bilateral posterior open bite and wider posterior space of the mandibular condyle in the right TMJ than in the left (Fig. 2 and 3). As primary care, the patient was treated with non-surgical methods, including diet modification, resting of the jaw, and non-steroidal anti-inflammatory drugs. These treatments decreased the magnitude of severe pain on mouth closing to some extent

but did not alleviate the posterior open bite.

Two days after onset, MRI revealed PFRT, normal disk position, and small joint effusion (JE) in her right TMJ (Fig. 4 a, b, c), and no abnormal finding in her left TMJ (Fig. 5 a, b). Five days after onset, the patient was treated with a pumping manipulation technique [14]. After routine disinfection, approximately 3 ml of 1% lidocaine was injected into the upper joint cavity of the right TMJ, the patient's mandible was manipulated in the conventional manner [2], and normal saline with corticosteroids was injected to alleviate intracapsular inflammation. Subsequently, the patient's edge-to-edge bite was slightly improved to an overjet of 3 mm and an overbite of 2 mm, but she was still unable to occlude her posterior teeth. On the next day of treatment, she was able to achieve partial contact of her posterior teeth on mouth closing. The treatment was effective for moderate reduction of the posterior open bite and the patient showed almost complete recovery and regained her original occlusion in the fourth week (Fig. 6 a, b, c).

III. Figures

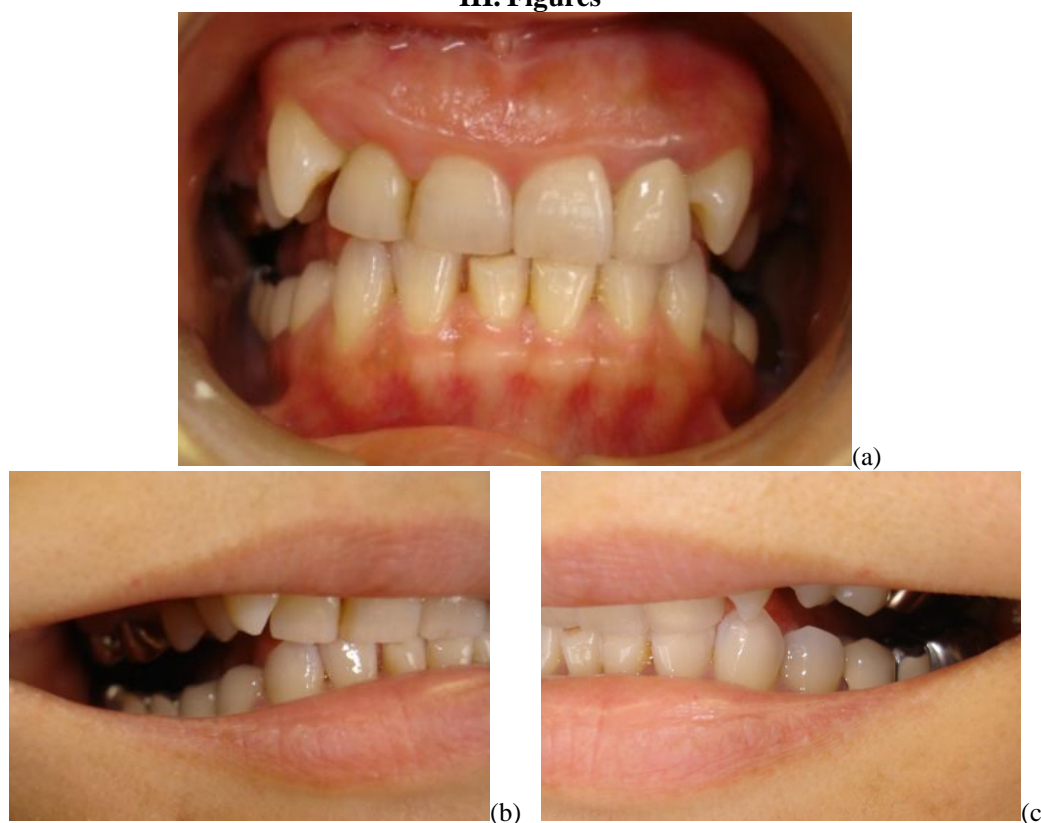

Figure 1a,b,c. Intraoral views showing an edge-to-edge bite, bilateral posterior open bite and deviation to the left of the mandible median line.

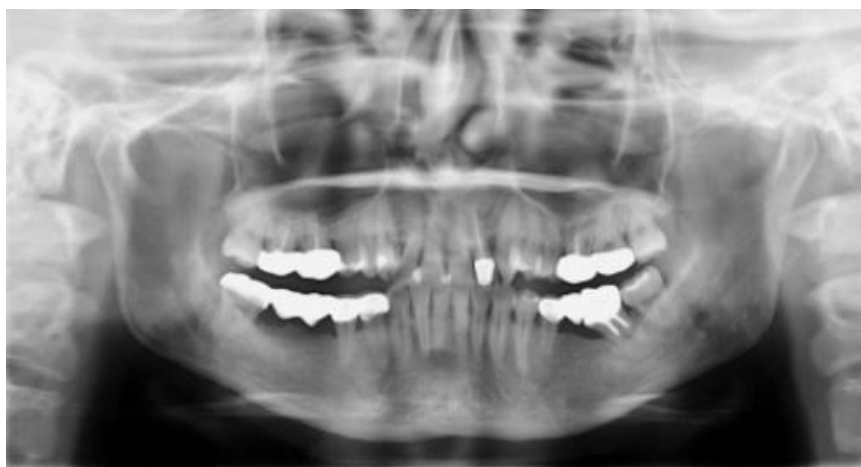

Figure 2. Orthopantomography in the closed mouse position showing a bilateral posterior open bite.

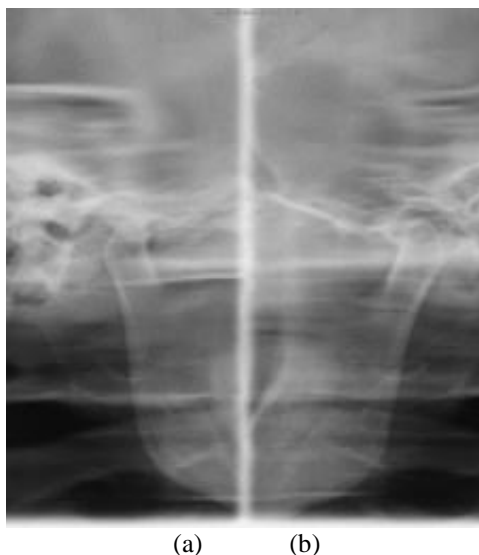


Figure 3. Panoramic tomography of the TMJ in the closed mouth position showing that the posterior space of the mandibular condyle in the right TMJ(a) was wider than that in the left TMJ(b).

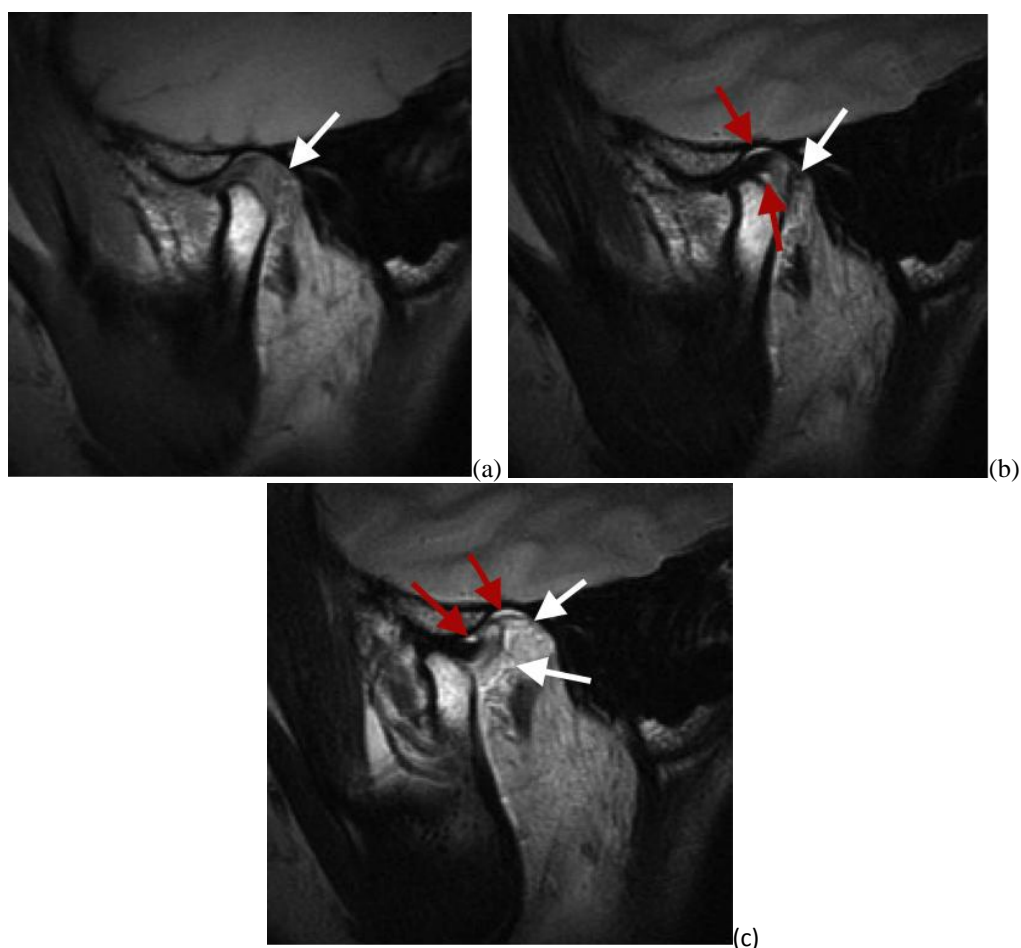


Figure 4. Oblique sagittal T1-(a) and T2- (b,c) weighted images of the right TMJ in the closed (a,b) and open(c) mouth positions showing PFRT(white arrows), normal disk position, and JE within both the superior and inferior joint compartments(red arrows).

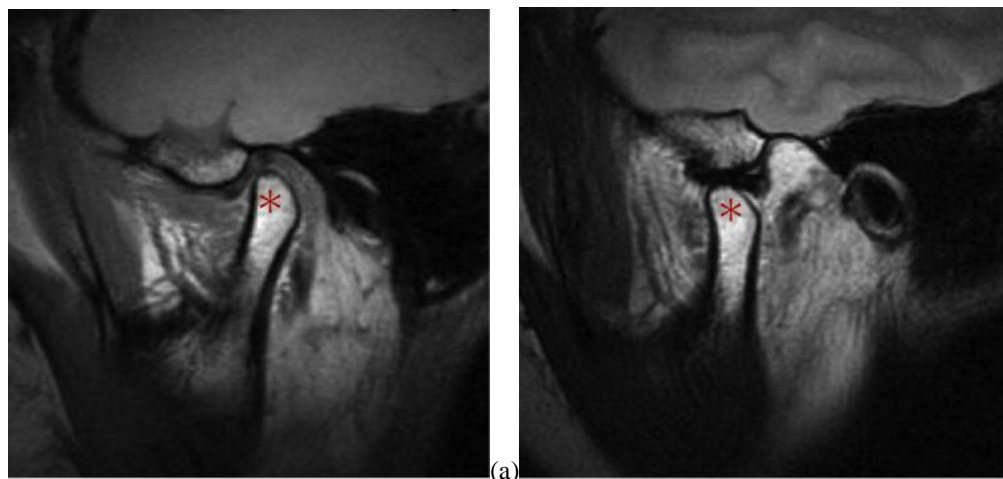


Figure 5. (a) Oblique sagittal T1-weighted image of the left TMJ in the closed mouth position showing that the articular disk has normal biconcave appearance and disk position. (b) Oblique sagittal T2-weighted image of the left TMJ in the open mouth position showing normal anterior translation of the condyle(asterisk) and little JE within the joint compartments.

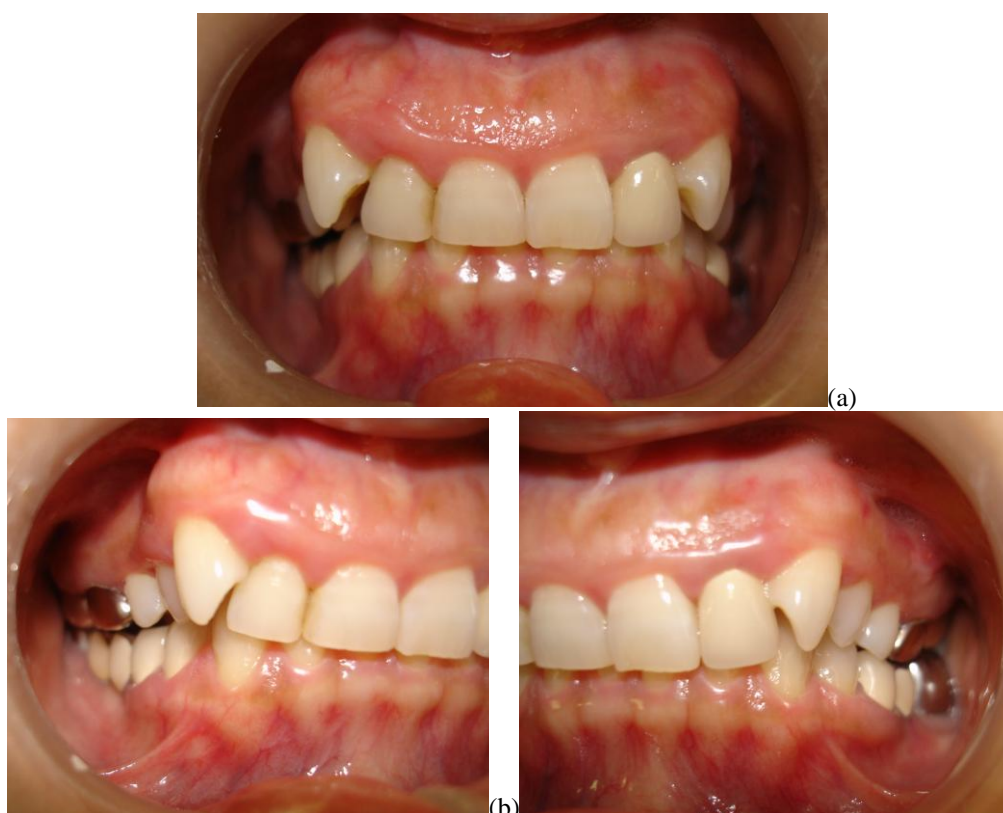

Figure 6. Intraoral view after the final treatment showing reduction of the posterior open bite, resulting in a deep bite. The patient was able to open her mouth smoothly up to 38 mm without pain.

IV. Discussion

A few studies of mouth-closing disturbances during the final phase of occlusion have reported PDD, PFRT, arthritis, synovial chondromatosis and thickening of the retrodiscal tissue as potential causes [6-13]. The initial clinical findings in the present case suggested that the posterior open bite was caused by PDD or PFRT with arthritis in the right TMJ. The final diagnosis by MRI confirmed that the posterior open bite in this case was due to PFRT with arthritis. It also has been documented that posterior open bite was seen in patients who were treated with the anterior repositioning splint [15]. Furthermore Fukumoto et al. have reported that a past history of reciprocal clicking is important to distinguish between PFRT and PDD [11]. Although the patient did not remember the period of being aware of clicking, she had a history of clicking in the right TMJ that occurred

with chewing or yawning. We suspected that the patient had ADD in her right TMJ before onset. Recapture of the disk, induced by a big yawn, and PFRT, caused by a secondary sudden mouth-closing movement that disturbed her right temporomandibular condyle from the habitual position within TMJ, resulted in the inability to close the posterior teeth into the intercuspal position.

There are relatively few studies describing the treatment options for PFRT[11-13]. Fukumoto et al. have reported that distension of the upper joint cavity provoked by pumping or manipulation is an appropriate treatment for PFRT [11]. In our case, pumping manipulation effectively improved the posterior open bite and alleviated the severe pain. Before employing the pumping manipulation technique, it is important to arrive at a differential diagnosis of PFRT via MRI. However, if a patient complains of sudden posterior open bite and severe pain on mouth closing, along with a past history of reciprocal clicking, and shows anomalies such as an enlarged posterior space of a mandibular condyle on panoramic tomography of the TMJ, earlier pumping manipulation without MRI can be performed to improve the patient's quality of life.

It is generally believed that the etiology of TMD is multifactorial, consisting of occlusal factors, anatomic factors, parafunctional habits, trauma, and psychosocial factors that initiate and propagate TMD [16]. In the present case, the patient was a housewife before onset, but was scheduled to start a new job. Her PFRT was initiated by a big yawn, although psychosocial factors may have some influence on the intracapsular condition with internal derangement.

V. Conclusion

We have described a rare case of sudden bilateral open bite caused by PFRT of the right TMD. The pumping manipulation technique effectively improved the posterior open bite and severe pain.

Conflict of interest statement

The authors declare no conflicts of interest associated with this report.

Acknowledgements

The authors would like to thank Enago (www.enago.jp) for the English language review.

References

- [1] W.B.Farrar, Diagnosis and treatment of anterior dislocation of the articular disk. *The New York Journal of Dentistry*,41(10), 1971, 348-351.
- [2] W.B. Farrar, W.L. McCarty, A clinical outline of temporomandibular joint diagnosis and treatment,7th Ed.(Montgomery: Walker Printing Co., 1983).
- [3] F. Matsumoto, T. Ishikawa, H. Takeuchi, K. Fujisawa, H. Hosoki, M. Hada, M. Nakano, Correlation between magnetic resonance image evaluation and clinical findings in patients with temporomandibular disorders, *Shikoku Dental Research* 22 (2), 2010,167-172.
- [4] S. Matsuda, Y. Yoshimura, Magnetic resonance imaging assessments of the temporomandibular joint in disk displacements. *International Journal of Oral and Maxillofacial Surgery*, 23(5),1994, 266-270.
- [5] T. Sasaki, T. Aomura, K. Tamura, H. Miyata, K. Namioka, K. Kudo, Correlation of clinical symptoms and magnetic resonance imaging evaluation in disc displacement of temporomandibular joint, *Journal of The Japanese Society for Temporomandibular Joint* 11(1), 1999,18-23.
- [6] J. Blankestijn, G. Boering, Posterior dislocation of the temporomandibular disc. *International Journal of Oral Surgery*,14(5),1985,437-443.
- [7] D.M. Gallagher, Posterior dislocation of the temporomandibular joint meniscus: report of three cases, *The Journal of the American Dental Association*,113(3), 1986, 411-415.
- [8] J.J.R.Huddleston Slater, F. Lobbezoo, N. Hofman, M. Naeije, Case report of a posterior disc displacement without and with reduction, *Journal of Orofacial Pain*, 19(4), 2005,337-342.
- [9] K. Kakudo, Y. Higashino, R. Shirasu, T. Shibata, A case report of posterior disc displacement without reduction of TMJ, *Journal of The Japanese Society for Temporomandibular Joint*, 3(2),1991,137-142.
- [10] J.V. Manzione, R.H. Tallents, Pseudomeniscus sign: Potential indicator of repair or remodeling in temporomandibular joints with internal derangements. *Radiology* 3,1992,677-679.
- [11] Y. Fukumoto, M. Sugisaki, S. Iwamoto, S. Shigematsu, Y. Takigawa, H. Ohtsuru, Mouth closing disturbance caused by the disc of the temporomandibular joint, *Japanese Journal of Oral & Maxillofacial Surgery*,48(5), 2002, 284-287.
- [12] Y.Takayama, R.Takagi, H. Ajima, M. Nagata, Disturbance at mouth closing to posterior band of reduced articular disc associated with internal derangement of TMJ: a case report, *Journal of The Japanese Society for Temporomandibular Joint*, 20(1) ,2008,16-19.
- [13] N. Oheda, T.Kawakami, M. Baba, J. Ogawa, M. Tsuzuki, N. Ohkochi, T. Kirita, A case of posterior open bite by a thickness of retrodiscal tissue, *Journal of The Japanese Society for Temporomandibular Joint*, 14(2), 2002,237-241.
- [14] K. Murakami, M. Matsuki, T. Iizuka, T. Ono, Recapturing the persistent anteriorly displaced disk by mandibular manipulation after pumping and hydraulic pressure to the upper joint cavity of the temporomandibular Joint, *The Journal of Craniomandibular Practice*, 5(1), 1987, 18-24.
- [15] S. Kai, H. Kai, O. Tabata, H. Tashiro, The significance of posterior open bite after anterior repositioning splint therapy for anteriorly displaced disk of the temporomandibular joint, *The Journal of Craniomandibular Practice*, 11(2), 1993, 146-152.
- [16] W.E. Bell, *Temporomandibular disorders. Classification, diagnosis, management*. 3rd Ed. (Chicago: Year Book Medical Publishers, 1990)