

Role of Pediatric Dentist - Orthodontic In Cleft Lip and Cleft Palate Patients

Muhamad Abu-Hussein*, Nezar Watted** Omri Emodi ***
Edlira Zere****

*Department of Pediatric Dentistry, University of Athens, Greece

**Clinics and Policlinics for Dental, Oral and Maxillofacial Diseases of the Bavarian Julius-Maximilian-University Wuerzburg, Germany

*** Department of Oral and Maxillofacial Surgery, Rambam Health Care Campus, Haifa, Israel

****Orthodontic and Craniofacial Department, School of Graduate Dentistry, Rambam Health Care Campus, Haifa, Israel

Corresponding Author; Dr.Abu-Hussein Muhamad DDS,MScD,MSc,Cert.Ped,FICD .123Argus Street,
10441 Athens, Greece
abuhusseinmuhamad@gmail.com

Abstract: Cleft Lip and Palate is severe birth defect occurring one in 700-1000 newborn infants. Cleft lip and palate together account for 50% of all cases whereas isolated cleft lip and palate occur in about 25% of cases. Management of Cleft Lip and Palate is carried out by multi disciplinary team approach. When ever a child is born with cleft lip and palate or one of them, it interferes with feeding and speech and hampers esthetic severely. Consequently it is psychologically traumatic to both patients as well as for their family members. Patients with cleft lip and palate are also are at high risk for dental diseases. So in such situation proper education, guidance, motivation and encouragement are required. Pre and post surgically pediatric dentist and orthodontics helps the patient by providing functionally and esthetically acceptable occlusion, good oral hygiene and preventive dental care. This paper describes the treatment protocol of pediatric dentistry and orthodontic with cleft lip and palate.

Key words: Cleft Lip And Palate, Pediatric Dentist, Orthodontic Multi Disciplinary Team

I. Introduction

Clefts are among the most common congenital malformations worldwide. Typically, they require complex multidisciplinary treatment throughout childhood and can have lifelong medical and psychosocial implications for affected individuals. The two main types of oral clefts are cleft lip and cleft palate[1]. Cleft lip is the congenital failure of the maxillary and median nasal processes to fuse, forming a groove or fissure in the lip (**FIG 1**). Cleft palate is the congenital failure of the palate to fuse properly, forming a grooved depression or fissure in the roof of the mouth (**FIG 2**). Clefts of the lip and palate can occur individually, together, or in conjunction with other congenital malformations (**FIG 3a, b**)

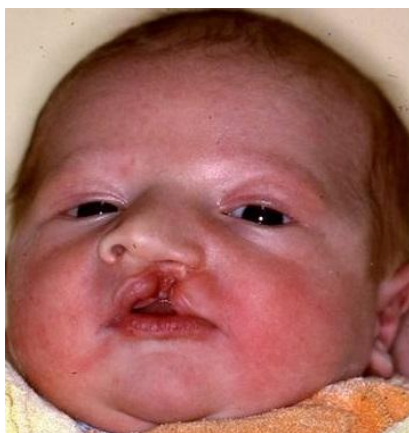

Fig. 1: Patient with left-sided cleft lip

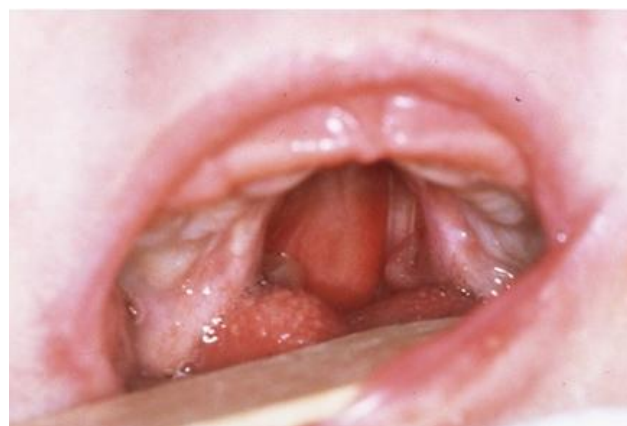

Fig. 2: Patient with cleft palate

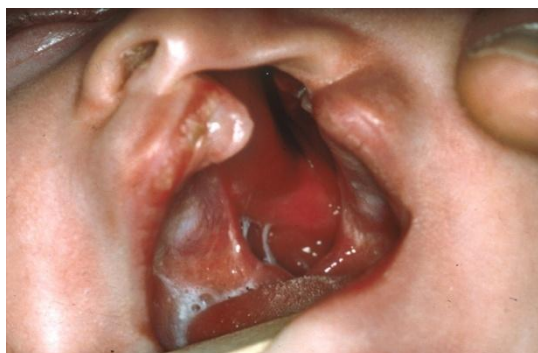

Fig.3a: Patient with left-sided cleft lip and palate

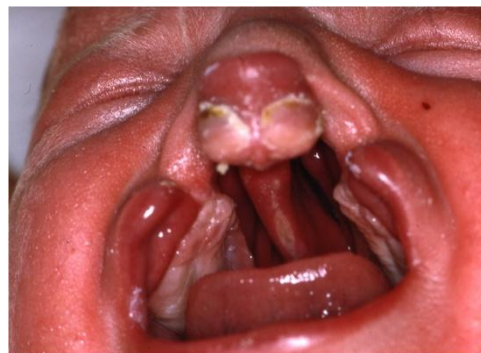

Fig.3b: Patient with bilateral cleft lip and palate

Epidemiologic studies of isolated (i.e., without other malformations or syndromes) cleft lip and/or cleft palate have been conducted worldwide, often resulting in varying prevalence rates. Differences in geographic and ethnic distributions may account for some but not all of the variations. Other factors contributing to the diverse figures are the inclusion criteria used to group cleft types (i.e., CL ± P versus CP) or define the cleft population (i.e., all cases of cleft including other birth defects versus cases of isolated cleft).[1,2]

Cleft of the lip, palate, or both is one of the most common congenital abnormalities. The average prevalence of cleft lip with or without cleft palate is 7.75 per 10,000 live births in the United States and 7.94 per 10,000 live births internationally.[1,2]

The Centers for Disease Control and Prevention (CDC) recently estimated that each year 2,651 babies in the United States are born with a cleft palate and 4,437 babies

are born with a cleft lip with or without a cleft palate. Cleft lip is more common than cleft palate. About 70% of all orofacial clefts are isolated clefts.[3]

Cleft lip with or without cleft palate is observed more frequently in males, while isolated cleft palate is more typically seen in females [1,2]. High rates of cleft lip with or without cleft palate are seen in Latin America, China, and Japan, but are relatively low in Israel, South Africa and southern Europe. Isolated cleft palate rates are high in Canada and parts of northern Europe, but low in Latin America and South Africa [1,2]

Clefts in unborn babies are often detected with an ultrasound examination during a routine antenatal appointment. This antenatal scan typically takes place at around 20 weeks (**FIG 4**). The accuracy of sonography for prenatal diagnosis of cleft lip and palate is highly variable and dependent on the experience of the sonographer and the type of cleft. Reported rates of detection for cleft lip and palate range from 16% to 93%. Isolated cleft palate is rarely identified prenatally. Furthermore, even when a cleft lip is visualized sonographically, it is difficult to determine whether the alveolus and secondary palate are also involved.[4]

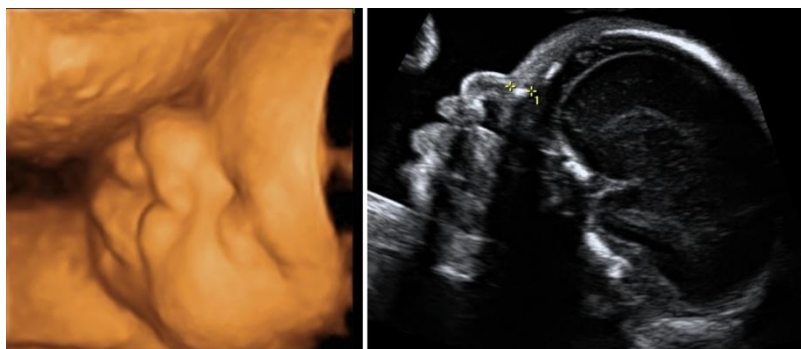

Fig. 4 : Timeliness developed fetus with left-sided cleft lip and palate

MRI is used increasingly for evaluation of fetal abnormalities that are difficult to identify on sonography alone. Fetal MRI is less dependent than sonography on optimal amniotic fluid volume, fetal position, and maternal body habitus. Additionally, visualization of small structures on MRI is not limited by bone shadowing. [4,5]

If a cleft lip or palate is not picked up during an antenatal appointment, the cleft is nearly always diagnosed after the baby has been born. However, in some cases, for example a submucous cleft palate where the cleft is hidden in the lining of the mouth, a diagnosis may not be made for several months or even years, when speech problems develop.[5,6]

Patients with orofacial clefts are best cared for by an interdisciplinary team of specialists with experience in this field. Generally, there are two variations in specialized teams that provide services to

individuals with cleft lip and/or palate [3]. The Cleft Palate Team (CPT) provides coordinated and interdisciplinary evaluation and treatment to patients with cleft lip and/or cleft palate; while The Craniofacial Team (CFT) provides coordinated and interdisciplinary evaluation and treatment for patients with a wide range of craniofacial anomalies or syndromes[1,2,6].

In dental rehabilitation, the pediatric dentistry provides oral health information and should be able to follow the child with cleft lip and palate of the mixed dentition, craniofacial growth and dentition development. The orthodontist monitors the craniofacial growth and development and corrects the malocclusions, which are more complex compared to patients without clefts. A great part of individuals present marked skeletal discrepancies in anteroposterior, transverse and vertical directions. This evidences the fundamental role of the maxillofacial surgeon working together with the orthodontist[1,2,5,6]. This paper describes the treatment protocol of pediatric dentistry and orthodontic with cleft lip and palate.

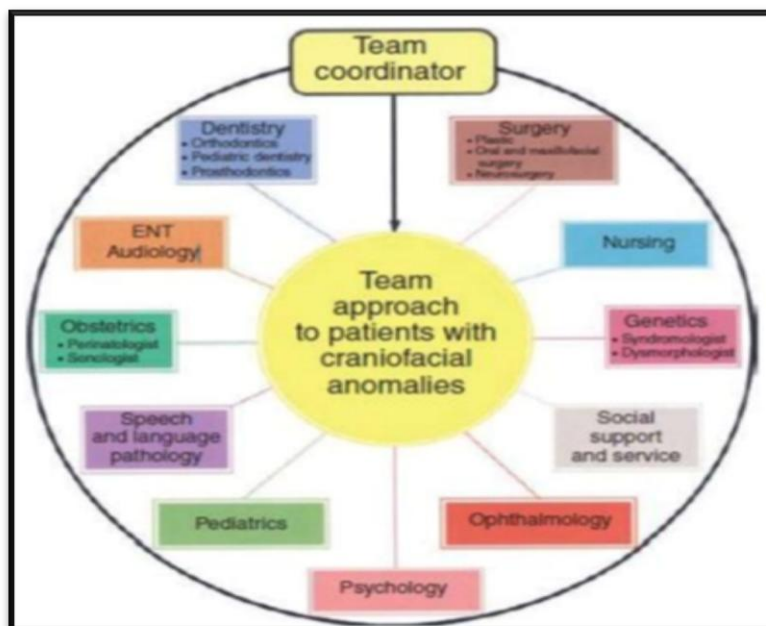


Fig.5; Multidisciplinary team with congenital abnormalities

II. Pediatric Dentistry

Pediatric dentistry plays a critical role in creating a proper plan of care for oral health and overall nutrition . Dentists as members of the cleft palate team provide assistance to maintain healthy dentition and gums, monitor craniofacial growth and development, and correct jaw relationships and dental occlusion to achieve proper function and appearance . Feeding appliances and presurgical infant orthopedic appliance impressions are most frequently provided by the pediatric dentist on cleft palate teams at most hospital-based programs .[7]

Dental treatment is necessary in the case of (cleft lip and palate) the oral cavity of these children is characterized by supernumary teeth, missing teeth, impaction and crowding, and delayed eruption. The maxilla is affected and the mandible has an abnormal shape and size. The dentist works closely with the orthodontist to time adjustments to the oral cavity and dentition. The researchers point to two significant findings: a delay of 0.96 years vs. a normal timeline of dentition, as well as a marked slowdown in dental maturity that slows more notably with age. This means that the dentist must time their involvement with the patient along these parameters. They will work on extraction of supernumary teeth and impaction and crowding, but the work is done at different ages as normal children. The dentist also works closely with the orthodontist and plastic surgeon to assess dentition all the while that processes are worked on for closing the alveolar ridge after age 5;0 as well as palatal closure and velopharyngeal port surgeries[1,2,7].

Pre and post surgically pediatric dentist helps the patient by providing functionally and esthetically acceptable occlusion, good oral hygiene and preventive dental care[1,2,8,9].

Treatment part divide in to two groups according to age of patient:-

- 1) From birth to mixed dentition.
- 2) The mixed dentition stage through early adolescence and young adulthood.

1) From birth to mixed dentition:

A) Medical history: The child with a cleft may have an associated syndrome or sequence, such as Pierre Robin, or have additional medical problems. An understanding of underlined medical problem is necessary to allow for appropriate dental management and treatment planning. Young child with cleft lip and palate often have associated middle ear problem and consequent hearing difficulties.

B) Social history: An appreciation of the family situation is important to allow for the optimum delivery of dental care. Each patient and their family own particular needs and these gradually have their relationship is built with the dentist.

C) Dental examination: The easiest way to examine a baby is with its head gently lowered on to the dentist's lap and the parent sitting facing the dentist, supporting and controlling the child's arms and legs. The use of a small dental mirror is helpful in tiny mouths especially in the patient with a cleft.

Particularly care is needed when examining the palatal cleft area as teeth are easily missed out in this region.

There may be missing teeth, commonly the upper primary lateral incisor or there may be supernumerary teeth present in the cleft area.

D) Behaviour management: These patients may be shy, nervous, or have behavioural problem. The reasons are multi-factorial but frequent hospital visits and previous hospitalization may play a part. Children may also be influenced by their parent's behavior, which is some times anxious and over protective. The pediatric dentist needs patience to establish good communication, especially in the early years.

E) Preventive management:

a) Diet: Feeding difficulties are a common problem for babies with a cleft palate and few mothers are successful with breast feeding in Children with feeding difficulties we can give feeding plates (obturators). Obturator helps in feeding, speech and prevents repeated infections of upper respiratory tract.

Specialized feeding bottles such as the Haberman feeder and Mead Johnson bottle have helped to overcome some of the feeding problems. Parents should be recommended milk and cooled boiled water as the only suitable dentally-safe drinks for use in a feeding bottle. They should be made aware that fruit drinks and squashes, including baby fruit juices, have an erosive potential. Sugar-containing and acidic drinks should be kept to a minimum and given at meal times only.

b) Use of fluoride

Professional fluoride application, Fluoride supplement; Topical fluoride gel application, fluoride varnish application twice-yearly is very useful preventive measure for teeth that are at high risk from caries.

2) The mixed dentition stage through to early adolescence and young adulthood:

Mixed dentition and permanent dentition stage:

a) Preventive management: Dietary counseling is best achieved with a three-day diet diary. Worries about bleeding from inflamed gingiva around cleft region should be identified, especially following alveolar bone grafting. Oral hygiene prior to bone grafting must be of a very high standard as gingival inflammation can cause loss of the new bone. A 0.2% chlorhexidine mouth wash is useful for short periods following surgery or to help stabilize gingival health in severe cases of gingival inflammation, where the patient is anxious about the bleeding gingival tissues and very nervous to brush. Baby sized tooth brush is still useful even at this age. Pit and fissure sealants are an important consideration for this group of patients. Fissure sealing should be carried out as soon as the teeth have erupted sufficiently to allow adequate moisture control. Application of topical fluoride periodically is a valuable preventive measure.

b) Restorative care and pulp therapy: If carious teeth are present, it is essential that they are restored as soon as possible with the most suitable materials. Pulp therapy is required for teeth which having caries very close to pulp, dento alveolar abscess, immature permanent tooth (apexogenesis or apexification).

c) Space management: Space maintainers are given to maintain the space after extractions of deciduous teeth. Space regainers are required to gain the space which was lost by drifting of adjacent tooth.

d) Minor orthodontic treatment: Anterior and posterior crossbite correction and arch expansion (before alveolar grafting and cleft palate surgery)

e) Extractions: Non restorable teeth require extractions.

f) Communication with cleft team: Good communication with cleft team is essential for accurate exchange of information.

According to the literature, individuals with cleft lip and palate may present alterations in the deciduous dentition at the cleft area, especially affecting the maxillary lateral incisor. The oral cavity of the newborn may present gingival and

palatal cysts of the newborn, natal and neonatal teeth at the region of complete unilateral and bilateral cleft lip and palate, which may be lateral incisors of

the normal series or supernumerary teeth. These mobility, thus their extraction is indicated because of the risk of aspiration, due to the communication between the oral and nasal cavities in this type of cleft.[1,2,9,10]

Tooth eruption may be delayed up to two years in complete cleft lip and palate. The deciduous dentition may present alterations proportional to the extent of the

cleft, with greater involvement in more extensive clefts, except for isolated cleft palate, in which the alveolar ridge integrity is maintained. Dental anomalies of shape, structure, number and position are present mainly in teeth close to the cleft.

All these anomalies in the deciduous dentition may predispose the affected teeth to greater dental caries. Thus, counseling and follow-up are important to maintain the integrity of teeth, even supernumerary or malpositioned teeth, in order to maintain the supporting bone structures, which may be defective at the cleft area [5,6,7].

Dental anesthesia in individuals with cleft is not different for most regions in the oral cavity, except for the cleft area. At this region, the maxilla is divided in different segments by the bone defect, with individual innervation. Even though the clinical

aspect is improved after surgical repair, the alveolar separation is maintained³⁸. This is important when teeth at this region must be anesthetized, because

the malpositioning may complicate determination of the site of tooth implantation.

Rubber dam isolation is recommended for dental treatment whenever possible, especially in cases of unrepaired cleft palate. The rubber dam isolates the constant water flow of the high speed handpiece, dental caries or restorative material

remnants, avoiding their penetration in the airway, which communicates with the oral cavity in these individuals[7].

Cariou lesions leads to the need of restorative treatment, if detected on time,

or tooth extraction if the extent of the lesion does not allow restoration. The atraumatic restorative technique should be indicated for initial carious lesions without risk of pulp contamination. Whenever individuals with cleft lip and palate present dental caries with risk of pulp contamination, treatment should be conventionally performed. Individuals submitted to surgery should have an excellent oral condition, removing the sources of infection that may compromise the surgery¹³. Supernumerary and/or malpositioned deciduous teeth adjacent to the cleft should be maintained as long as possible, in order to preserve bone tissue that is already defective at this region.[1,2,7]

The pediatric dental treatment for children with cleft lip and palate is not different from the conventional dental treatment concerning the prevention of dental caries and periodontal disease. The management techniques are those routinely used for child behavior control, considering the normal psychological development . Clinical examination and an adequate restorative and preventive treatment plan, as well as parent counseling, is fundamental for the future rehabilitation of individuals with cleft lip and palate. However, the anatomical alterations brought about by the anomaly may cause differences that the influence of the dental treatment [1,2].

III. Orthodontics

Orthodontists play a significant role in the treatment of a child with cleft lip and palate there are four distinct processes that the orthodontist will participate in up to and beyond the child's twelfth year of life. The orthodontist will confer with the dentist and plastic surgeon that care for a child with cleft lip and palate This is to determine proper timing for the implementation of orthodontic treatment. The first process begins from 0;0 to 7;0 years, after the initial treatment plan is devised with the craniofacial team. This is the period during which the orthodontist constructs neonatal maxillary orthopedics for the child ages infant through elementary school age. The purpose of this device is to bring the maxilla in alignment with the rest of the head, with consideration of the mandible and dentition in the process of the orthopedic treatment. There is debate as to the proper timing for orthopedics and the efficacy of using extra-oral pin-retained appliances versus passive appliances. Per the researchers 54% of craniofacial centers use neonatal maxillary orthopedics.[5,6]

The second process involves orthodontic treatment of the deciduous dentition stage, which the researchers state has a direct correlation with the patency of circummaxillary sutures. This occurs in the latter period of 5;0 to 7;0

years. It is significant to reiterate the research of Kaloust, Ishii, and Vargervik bearing in mind once again that there is a 0.96 year delay in dentition of Apert's vs. normal children's dentition. Treatments are needed for the lack of deciduous dentition in the area of the alveolar cleft, and these treatments may include a face mask to protract growth. Treatment to manage crossbite includes equilibration for occlusal interference.[1] The third process is in the mixed dentition period in the 9;0 to 11;0 years age range. This is concurrent with alveolar bone grafting, 6 months prior to graft insertion with fixed appliances placed on the maxillary arch. The researchers explain that this eliminates crossbite and other unfavorable consequences of malpositioned incisors, and helps with dental aesthetics.[5,6]

Eruption of the canine adjacent to the cleft of the secondary palate is of importance as this will control the timing for further orthodontic treatment. The researchers point to evidence that the canines erupt in synchronicity with bone graft placement. The fourth process is in the permanent dentition stage, anywhere from 10;0 to 13;0 years of age or even older. In this period there is a determination whether orthognathic surgery is indicated. The researchers state that there is a high percentage of patients that require this surgery vs. the general population, but that it is not needed in more than 10% of the Apert's and cleft palate patients. This is particularly relavent in Apert's patients as they have a high incidence of Class III skeletal issues and thus the orthodontist carefully exams the other evidence from the craniofacial team in order to determine candidacy for treatment[9,10,11,12].

The diagnosis of malocclusions in individuals with clefts makes use of the same resources employed in conventional orthodontic records: facial and dental photographs, dental casts, extraoral and intraoral radiographs. In general, orthodontic records are taken at 9 years, 12 years and 18 years of age. [12,13,14]

The panoramic radiograph is used for a global view of the dentition and diagnosis of dental anomalies. The standardized occlusal radiograph of the cleft area, as well as the periapical radiograph of the cleft area, are often used for the assessment of the width and extent of the alveolar bone defect and for the follow-up of alveolar bone grafts.[14,15]

The orthodontic treatment of individuals with clefts follows these protocol stages:

- 1) Orthodontics before alveolar bone graft;
- 2) Secondary alveolar bone graft;
- 3) Orthodontics after alveolar bone graft;
- 4) Orthognathic surgery;
- 5) Finalization and retention (**FIG 6**)

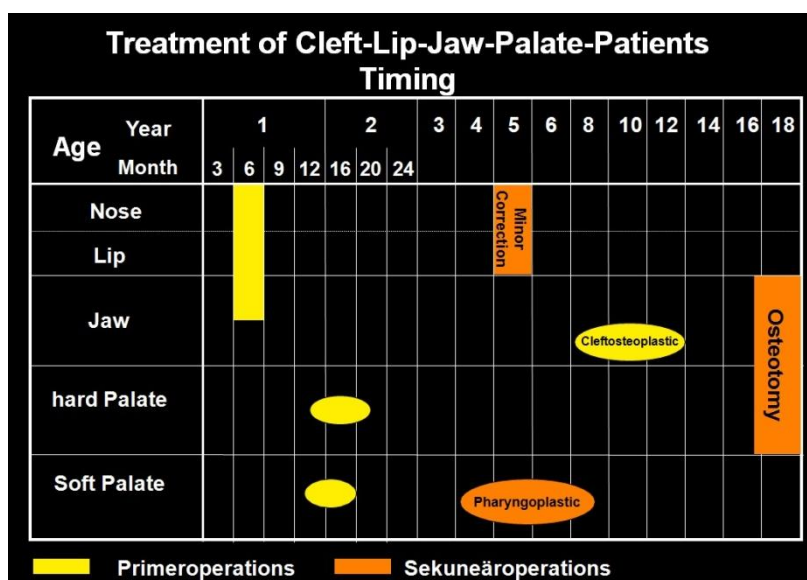


Fig 6

Approximately at 8 years of age. This first intervention deficiency to correct maxillary arch transversal deficiency and the posterior crossbite preparing the maxillary arch to receive the secondary alveolar bone graft. Rapid maxillary expansion with Hyrax or Haas type expanders is initiated when the permanent maxillary canines present formation of half to two thirds of the root. The maxillary arch trasversal deficiency is not always associated with crissbite ,or combined atresia of the mandibular dental arch. Even in these cases, there is the need of maxillary orthopedic expansion to prepare the maxilla to receive the secondary alveolar bone graft. Maxillary segments

should be aligned to provide lateral walls for performing the alveolar bone graft.

Bone grafting has several advantages. It is performed to support the long-term expansion of the dental arch, maintaining arch continuity and form while also providing bone for the passage of the erupting canine through the graft.[13,15,17]

Timing of alveolar bone graft relates to tooth development and is carried out between the ages of 6-9 years, using the stage of root formation of the maxillary canine as a guide for the proper timing for bone graft is better than just following chronological age, when one third of the canine is formed viewed by a periapical x-ray is the best time to consider bone graft. . This may lead to spontaneous canine eruption through the graft and healthy gingiva surrounding the graft, with normal bone height

The planning for the comprehensive orthodontic treatment should include intra-arch and inter-arch objectives.

The intra-arch therapeutic options include:

- 1)Space closure of the region of missing maxillary lateral incisor by orthodontic mesialization of posterior teeth at the cleft side (**FIG. 7a-d**)
- 2)Maintenance of the maxillary lateral incisor in the cleft area when it is present and show a good root length;
- 3) Space maintenance of the missing lateral incisor for implant placement after completion of orthodontic treatment the post-graft
- 4) Implant placement at the canine-premolar region after moving the maxillary canine toward mesial at the space of the absent lateral incisor. The advantage of this option compared to the previous one would be the prevention of bone loss at the SABG area.[15,16,17,18]

Orthognathic surgery is required in about 25% of adult cleft patients according to the severity of skeletal features. The most commonly affected jaw in cleft patients is the upper jaw. Thus, in most cases, the orthognathic procedure performed involves the advancement of the upper jaw (Le Fort I) rather than setting the mandible back. When the reverse overjet is severe, a two-jaw surgery may be required, impacting breathing and esthetics.[19,20]

After all steps of orthodontic treatment, the retention period is initiated, which is very important in the rehabilitation of individuals with clefts. The disrupted maxilla is more susceptible to relapse. The bone graft has exclusive action on the alveolar region, leaving the entire cleft palate covered only with soft tissue.[19,20]

If the occlusion is stable, the Hawley plate is used at nighttime for additional one year. After this period, intercalated use is indicated for further 6 months until definitive discontinuity of use. The mandibular 3x3 retainer is maintained permanently in patients with a good level of oral hygiene. However, regular professional prophylaxis is recommended. Patients are followed for 3 to 5 years after the appliance removal. At this period, the orthodontist should also follow the third molar eruption, with referral for extraction in opportune timing.[5,6,16-20]

Patients with cleft lip and palate require a team approach for their treatment, comprised of several specialists. This multidisciplinary care starts from birth and continues into adulthood, and coordination amongst specialists is a major contributor to success in cleft treatment.

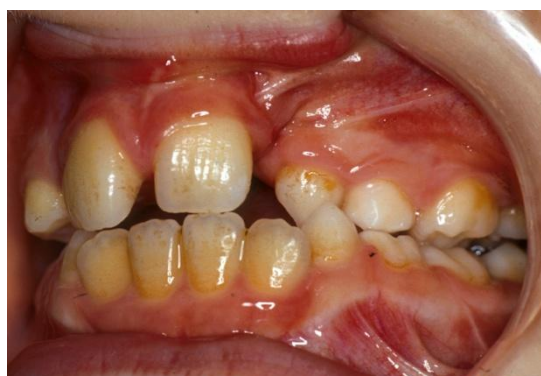

Fig.7a:

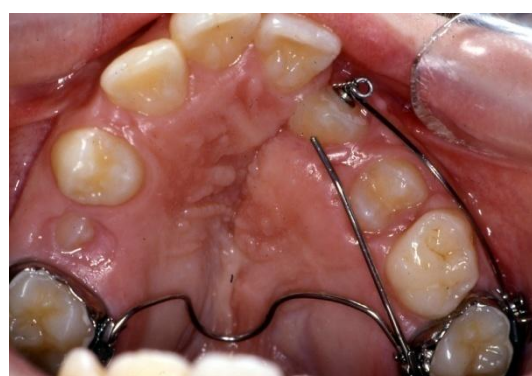

Fig.7b

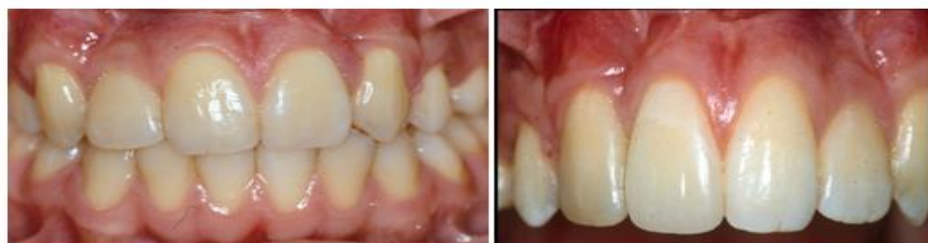

Fig.7c

Fig.7d

Fig 7a-d: Space closure of the region of missing maxillary lateral incisor by orthodontic mesialization of posterior teeth at the cleft side

IV. Conclusion

Patients with a cleft lip and palate are a priority group. The pediatric dentist and orthodontic had a key role to play in providing continuing, high-quality, preventive based dental care. Through treatment-planning, patient support and skilful behavior management are important aspects of this multi-faceted care. Good communication on a regular basis between the pediatric dentist-orthodontics and relevant members of the cleft team helps to achieve the best oral health outcome for the patient. It is mandatory that these patients be followed-up by a multidisciplinary team where the dentist plays an important role.

References

- [1]. Abu-Hussein M.; Cleft Lip and Palate – Etiological Factors. *Dent. Med. Probl.* 2012, 49, 2, 149–156
- [2]. Abu-Hussein M.; Cleft lips and palate ;the roles of specialists, *Minerva Pediatr.* 2011 .63(3):227-32.
- [3]. American Cleft Lip-Palate-Craniofacial Association. Parameters for Evaluation and Treatment of Patients with Cleft Lip/Palate or Other Craniofacial Anomalies. Chapel Hill, NC: The Maternal and Child Health Bureau, Health Resources and Services Administration, US Public Health Service, DHHS; November 2009. Grant #MCJ-425074. Available at: "http://www.acpa-cpf.org/resources/acpa_publications/". Accessed June 26, 2012
- [4]. Balasubrahmanyam, G., Scherer, N. J., Martin, J. A., & Michal, M. L. Cleft lip and palate: Keys to successful management. *Contemporary Pediatrics*, 1998, 15(11), 133-153.
- [5]. Graber L., Vanarsdall R., Vig K. *Orthodontics Current principles and Techniques*, 5th edition, Elsevier. 2011;965-89.
- [6]. Proffit WR, Fields HW, Sarver DM. *Contemporary Orthodontics*. (4th ed). St. Louis, 2007, Elsevier.
- [7]. Jaju R, Tate AR. The role of pediatric dentistry in multidisciplinary cleft palate teams at advanced pediatric dental residency programs. *Pediatr Dent* 2009;31:188-92
- [8]. Paravatty, R., Ahsan, A., Sebastian, B., Pai, K., Dayal, P. Apert syndrome: A case report with discussion of craniofacial features. *Quintessence International*, 1999,30(6), p. 423-426.
- [9]. Strong SM. Adolescent dentistry: multidisciplinary treatment for the cleft lip/palate patient. *Pract Proced Aesthet Dent.* 2002;14(4):333-8
- [10]. Kobayashi TY, Gomide MR, Carrara CF. Timing and sequence of primary tooth eruption in children with cleft lip and palate. *J Appl Oral Sci.* 2010;18(3):220-4.
- [11]. Vieira AR. Unraveling human cleft lip and palate research. *J Dent Res.* 2008;87:119-25.
- [12]. C.J. Rivkin, O. Keith, P.J.M. Crawford and I.S. Hathorn. Dental care for the patient with a cleft lip and palate. Part 1 : from birth to the mixed dentition stage. *British Dental Journal* 2000;188:no.2
- [13]. Bartzela TN, Carels CEL, Bronkhorst EM, Ronning E, Rizell S, Kuijpers-Jagtman AM. Tooth agenesis patterns in bilateral cleft lip and palate. *Eur J Oral Scin* 2010;118:47-5
- [14]. Precious DS. Cleft lip and palate. In: Fonseca R, editor. *Fonseca's oral and maxillofacial surgery*. Vol. 6, Ch. 3. Philadelphia: W.B. Saunders Company; 2000. p. 27-59.
- [15]. Precious DS, Delaire J. Surgical considerations in patients with cleft deformities. In: Bell WH, editor. *Modern practice in orthognathic and reconstructive surgery*. Vol. 1, Ch. 14. Philadelphia: Saunders; 1992.
- [16]. E. B. Strong and L. M. Buckmiller, "Management of the cleft palate," *Facial plastic surgery clinics of North America*, 2001, vol. 9, no. 1, pp. 15–25 .
- [17]. Strong SM. Adolescent dentistry: multidisciplinary treatment for the cleft lip/palate patient. *Pract Proced Aesthet Dent.* 2002;14(4):333-8 .
- [18]. Hagerty RF. The role of the dentist on cleft palate teams. *Birth Defects Orig Artic Ser* 1980;16:111-4.
- [19]. Carla A. Evans, Orthodontic treatment for patients with clefts *Clin Plastic Surg* 2004,31 ;271–90.
- [20]. Christos C. Vlachos. Orthodontic Treatment for the Cleft Palate Patient *Seminars in Orthodontics*, 1996, Vol 2, No 3 :197-204.