

## Peripheral Ossifying Fibroma: A Case Report

<sup>1</sup>Dr Santosh kanwar, <sup>2</sup>Dr Srisha Bassappa,

<sup>3</sup>Dr Mahesh M S, <sup>4</sup>Dr Prathibha Rani

<sup>1</sup>pg student of oral medicine and radiology; Farooqia dental college and hospital Mysore;

<sup>2</sup>HOD of oral medicine and radiology

<sup>3</sup>Reader of oral medicine and radiology

<sup>4</sup>Reader of oral medicine and radiology

---

**Abstract:** In the oral cavity, gingival growth is one of the most commonly encountered lesions, most of these lesions are benign, but some do have malignant potential. Usually these lesions occur as a result of irritants, plaque, calculus, trauma, microorganisms, restorations and dental appliances. Peripheral ossifying fibroma (POF) is a benign neoplasm that usually develops from reactive gingival overgrowth, usually occurring in the anterior maxillary region in teenagers. Females are affected then male (2:1) almost 60% of the lesion occurs in the mandible. Here we report a case of peripheral ossifying fibroma in a 50 year old male. Treatment includes excision of the lesion.

**Key Words:** Oral cavity, Gingiva, Fibrosed pyogenic granuloma, Peripheral ossifying fibroma, Histopathology,

---

### I. Introduction:

Gingiva is a common site for neoplastic and nonneoplastic lesions, to which peripheral ossifying fibroma (POF) is a non-neoplastic gingival growth which is quite common. Neoplasm's are characterized by progressive autonomous growth that can be either benign or a malignant course.<sup>1</sup> Peripheral ossifying fibroma are two types central and peripheral. Peripheral occurs only on the soft tissue over the alveolar bone.<sup>2</sup> The peripheral ossifying fibroma (POF) is a benign neoplasm (45.4%), that presents as an exophytic, smooth-surfaced, pink or red nodular mass sessile or pediculated, with a surface that is usually ulcerated arising from the interdental papilla.<sup>3</sup> Majority of the lesions are about 1.5 cm in diameter though some reach the size of about 6 cm in diameter .The peak incidence between 2<sup>nd</sup> and 3<sup>rd</sup> decade of life.<sup>4</sup>

### II. Case Report:

A 50 years old male reported the department of oral medicine and radiology with chief complaint of swelling in the lower left back teeth region since 3 months. History revealed, that the patient first noticed the swelling 3 months back, which was insidious in onset, not preceded by trauma or tooth ache. Swelling was gradually and constantly increasing in size to reach the present size. History of difficulty in chewing the food.

No history of pus, blood or watery discharge, color change or paraesthesia noted over the swelling. His medical and family history was noncontributory and had no deleterious habits. On intra oral hard tissue examination 33, 34, 35 no mobility elicited, on soft tissue examination , a solitary well defined sessile swelling measuring 3X3 centimeters present over the mandibular left posterior tooth region in relation to 33, 34, 35. The lesion is extending superiorly from marginal gingiva inferiorly up to lower border of attached gingiva. Medially up to the medial aspect of 33 till distal aspect of the 35. The color of the swelling resembles color of the surrounding normal mucosa. The surface of the swelling is normal with no secondary changes noted. Apart from confirming the inspectory findings, the swelling was non tender, soft to firm in consistency. [Fig: 1] A provisional diagnosis of fibrosed pyogenic granuloma was made. Differential diagnosis included Peripheral giant cell granuloma, Peripheral Ossifying fibroma, and Peripheral ameloblastoma. Ortho pantomogram showed well marginated radiopaque lesions with radiolucent foci seen in the interdental regions of 33, 34, and 35 suggestive of calcifications. [Fig: 2] Surgical excisions of the lesion was done under local anesthesia and was subjected to histopathological evaluation. Section showed variable thickness of stratified squamous epithelium with fibrovascular connective tissue. Connective tissue showed dense bundles of collagen fibers with compressed blood vessels, few areas showed chronic inflammatory cell predominantly lymphocyte along with osseous like structure seen. Epithelium showed hyperparakeratinization in few areas. Histopathological diagnosis was given as: Peripheral ossifying fibroma. [Fig: 3]

### III. Discussion

Peripheral ossifying fibroma (POF) has been defined by a variety of terms such as calcifying fibroblastic granuloma, ossifying fibrous epulis, and peripheral cementifying fibroma that have reflected partly the type of calcifications apparent histologically.<sup>5</sup> It is a reactive growth of the oral cavity seen in the gingiva. In 1872 Menzel first described the lesion ossifying fibroma, but its terminology was given by Montgomery in 1927.<sup>6</sup> There are two types of ossifying fibroma, the central and the peripheral. POF is not a counterpart of the central ossifying fibroma but a reactive lesion of the gingiva.<sup>7</sup> The term peripheral ossifying fibroma was given in the year 1982 by Gardner for a lesion that is reactive in nature and is not the extraosseous counterpart of a central ossifying fibroma (COF) of the maxilla and mandible. The term 'peripheral odontogenic fibroma' has been used to describe peripheral ossifying fibroma but should be avoided, as peripheral odontogenic fibroma has been designated by the World Health Organization (WHO) as the rare and extraosseous counterpart of central odontogenic fibroma and histologically presents as a fibroblastic neoplasm containing odontogenic epithelium.

Majority of the reports suggest POF is commonly seen in the second decade of life, with a reduce in incidence with age. In the present case, incidence of peripheral ossifying fibroma was in the fifth decade, which was comparatively older than that reported by Ababneh.<sup>9</sup> POF occurs in the gingival that is close to the periodontal ligament; origin of cells from the periodontal ligament (PDL) is considered and occurred in interdental papillae. POF appears as a slow growing solitary mass which is either pedunculated or sessile, the surface is usually smooth or ulcerated and the color ranging from red to pink, measuring about 1-2 cm in diameter usually but cases of > 2 cm have also been reported. The teeth involved are usually unaffected but in some cases migration, mobility and delay in eruption of permanent teeth may occur.<sup>2</sup> Radiographically it varies from completely no changes to areas of calcifications depending upon the degree of mineralization. Superficial bone loss, cupping defect and focal areas calcification have been reported in some cases.<sup>2,10</sup> Further investigations like computed tomography (CT) and magnetic resonance imaging (MRI) are done in cases when required considering the size. With administration of contrast agent, it appears as a mass with calcifications on CT and MRI shows the area of calcification with a very low signal on T2-weighted sequences.<sup>2</sup> Treatment includes surgical excision followed with oral prophylaxis. Follow-up is essential because of the recurrence rates varying from 8 to 20%, recurrence are due to incomplete excision, and or persistence of local factors.

### IV. Conclusion

Usually POF is clinically mistaken for pyogenic granuloma and peripheral giant cell granuloma so proper investigation like radiological and histopathological gives the confirmation. Treatment is complete surgical excision and regular follow-up due to the recurrence rate.

### References

- [1]. Lindhe J, Karring T, Lang NP. Clinical Periodontology and implant dentistry. 4th ed. Copenhagen: Blackwell Munksgaard; 2003.
- [2]. Moon WJ, Choi SY, Chung EC, Kwon KH, Chae SW. Peripheral ossifying fibroma in the oral cavity: CT and MR findings. Dentomaxillofac Radiol 2007; 36(3):180-2.
- [3]. Neville, et al. Textbook of Oral and Maxillofacial Pathology. 3rd edition 2009;p. 521-3.
- [4]. Cuisia ZE, Brannon RB. Peripheral ossifying fibroma – a clinical evaluation of 134 pediatric cases. Pediatr Dent2001; 23(3):245-8.
- [5]. Gardner DG. The peripheral odontogenic fibroma: an attempt at clarification. Oral Surg Oral Med Oral Pathol 1982; 54(1):40-8.
- [6]. Eversole LR, Sabes WR, Rovin S. Fibrous dysplasia: a nosologic problem in the diagnosis of fibro-osseous lesions of the jaws. J Oral Pathol 1972; 1(5):189-220.
- [7]. Buchner A. Peripheral odontogenic fibroma. Report of 5 cases. J Craniomaxillofac Surg 1989;17(3):134-8
- [8]. Kenney JN, Kaugars GE, Abbey LM; Comparison between the peripheral ossifying fibroma and peripheral odontogenic fibroma. J Oral Maxillofac Surg, 1989;47:378-82
- [9]. Ababneh KT. Biopsied gingival lesions in Northern Jordanians: a retrospective analysis over 10 years. Int J Periodontics. Restorative Dent 2006; 26(4):387-93.
- [10]. Yadav R, Gulati A. Peripheral ossifying fibroma: a case report. J Oral Sci 2009; 51(1):151-4.

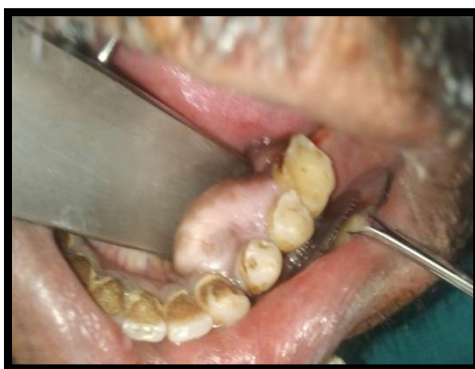

Fig 1: Intra oral view of the swelling

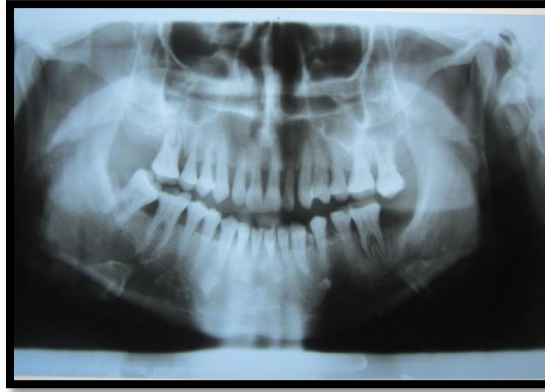

Fig: 2 Ortho Pantomogram Radiopaque shows lesions with radiolucent foci seen in the interdental regions of 33, 34, and 35 suggestive of calcifications.

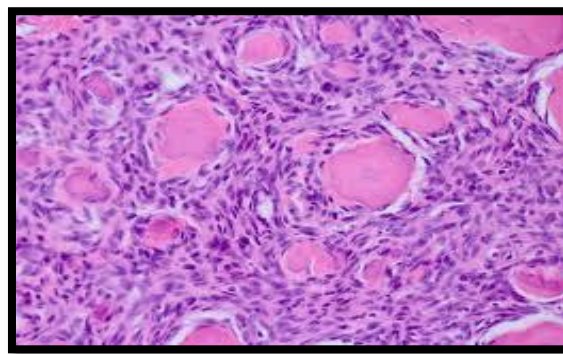


Fig: 3 Histopathological image