

## Corticotomy in the Modern Orthodontics

Muhamad Abu-Hussein\* , Nezar Watted \*\* Viktória Hegedűs\*\*\*,  
Péter Borbély\*\*\*\*

\*Department of Pediatric Dentistry, University of Athens, Greece

\*\* Clinics and Policlinics for Dental, Oral and Maxillofacial Diseases of the Bavarian Julius-Maximilian-  
University, Wuerzburg, Germany and Arab American University, Palestine

\*\*\*Department of Pediatric Dentistry and Orthodontics, University of Debrecen, Debrecen, Hungary

\*\*\*\*Fogszabályozási Stúdió, Budapest, Hungary

**Corresponding Author; Dr.Abu-Hussein Muhamad**

DDS,MScD,MSc,Cert.Ped,FICD 123Argus Street, 10441 Athens, Greece

---

**Abstract:** Corticotomy-assisted orthodontic treatment is an established and efficient orthodontic technique that has recently been studied in a number of publications. Corticotomy facilitated orthodontics have been employed in various forms over speed up orthodontic treatment It involves selective alveolar decortication in the form of decortication lines and dots performed around the teeth that are to be moved. It is done to induce a state of increased tissue turnover and a transient osteopenia, which is followed by a faster rate of orthodontic tooth movement. This technique has several advantages, including faster tooth movement, shorter treatment time, safer expansion of constricted arches, enhanced post-orthodontic treatment stability and extended envelope of tooth movement. The aim of this article is to present a comprehensive review of the literature, including historical background, contemporary clinical techniques, indications, contraindications, complications and side effects.

**Keywords:** Corticotomy, decortication, review, orthodontic treatment

---

### I. Introduction

The use of orthodontic treatment in adult patients is becoming more common. These patients have different requirements regarding duration of treatment, concerns regarding facial and dental aesthetics, and types of appliance that can be used. Additionally, orthodontic treatment in adult patients has special features with regard to periodontal hyalinization and alveolar flexibility compared with growing patients (1).

Surgically assisted orthodontic tooth movement has been used since the 1800s. Corticotomy-facilitated tooth movement was first described by L.C. Bryan in 1893, published in a textbook by S. H. Guilford(2). In the past 50 years, rapid tooth movement without significant root resorption has been reported(3). In these cases, the total treatment time was reduced to one-third to one-fourth that of traditional nonextraction and extraction orthodontic treatments.(3)The current corticotomy procedures adopted or modified by most clinicians are based on Heinrick Köle's combined radicular corticotomy/supraapical osteotomy technique, first described in 1959.Köle's technique consisted of buccal and lingual interproximal vertical corticotomy cuts limited to cortical layers, with these vertical corticotomy cuts being connected by horizontal osteotomy cuts approximately 1 mm beyond the apices of the roots(1). Then, in 1991, Suya replaced supraapical horizontal osteotomy with horizontal corticotomy to facilitate luxation of the corticotomized bone blocks.(4)

Recently, a surgical procedure in conjunction with orthodontic therapy has been popularized, which purports to reduce treatment times significantly. Although this procedure, termed corticotomy-assisted orthodontics, was first described in 1893,(5) it has only recently gained wide usage. This surgical technique includes gingival reflection followed by partial decortication of the cortical plates ending with primary flap closure. Significantly reduced treatment times have been reported using this procedure with reductions of 75% to 80% of routine treatment times.(6) **(Fig. 1)**

A corticotomy is defined as a surgical procedure whereby only the cortical bone is cut, perforated, or mechanically altered. The medullary bone is not changed. This is in contrast to an osteotomy, which is defined as a surgical cut through both the cortical and medullary bone. Wilcko et al. introduced surgical orthodontic therapy which included the innovative strategy of combining corticotomy surgery with alveolar grafting

in a technique referred to as Accelerated Osteogenic Orthodontics (AOO) and more recently to as Periodontally Accelerated Osteogenic Orthodontics (PAOO)(6,7,8,9) **(Fig.2)**. Significant acceleration in orthodontic tooth movement has been extensively reported following a combination of selective alveolar decortication and bone grafting surgery, with the latter being responsible for the increased scope of tooth movement and the long-term improvement of the periodontium. This conventional corticotomy approach

consists of raising full-thickness flaps and using a bur to create cortical incisions. Then an allograft is placed at the sites needing the bone expansion necessary for proper orthodontic tooth movement. This intentional injury to the cortical bone results in a modification of the bone metabolism, leading to a transient state of osteopenia, described as rapid acceleratory phenomenon (RAP). RAP was demonstrated at the alveolar bone level following corticotomy and would be responsible for rapid tooth movement.(6,7,8,9)

#### **Advantages**

1. Enhanced scope malocclusion treatment ( i.e., an increase in the limits of tooth movement and a decreased need for extractions)
2. Decreased treatment times (increased rate of tooth movement)
3. Increased alveolar volume and a more structurally complete periodontium(correction of preexisting fenestrations and dehiscence)
4. Alveolar reshaping, enhances patient's profile
5. Simultaneous recovery of shallow unerupted teeth
6. In certain situations, the additional alveolar bone can also provide improved lip posture
7. Less likelihood of root resorption.
8. History of relapse has been very low
9. There is less need for appliances and head gear
10. Both metal and ceramic brackets can be used

#### **Disadvantages**

1. Expensive procedure
2. Mildly invasive procedure and like all surgeries it has risk of some pain, swelling, and the possibility of infection.
3. Patients who take NSAIDs on a regular basis or have other chronic health problems will not be treated with this technique.

#### **Indications**

- a. Resolve crowding and shorten treatment time.
- b. Accelerate canine retraction after premolar extraction
- c. Enhance post orthodontic stability
- d. Facilitate eruption of impacted teeth
- e. Facilitate slow orthodontic expansion
- f. Molar intrusion and open bite correction

#### **Contraindications**

- a. Patients with severe active periodontal disease.
- b. Patients with inadequately treated endodontic problems.
- c. Patients on long term medications which will slow down bone metabolism, such as bisphosphanate and NSAIDs. NSAIDs lead to prostaglandin inhibition resulting in reduced osteoclastic activity thus disturbing bone remodeling.
- d. Patients on long term steroid therapy due to the presence of devitalized areas of bone
- e. Patients with compromised width of the attached gingiva

#### **Technique**

The orthodontic therapist determines the plan for the movement, identifying the teeth that will provide anchorage and those portions of the arch that will be expanded or contracted. In some cases the anchorage must be established before the procedure. Periodontal accelerated osteogenic orthodontics procedure is initiated. This is most commonly seen in class II malocclusions requiring retractions (**Fig. 3**).

The placement of orthodontic brackets and activation of the arch wires are typically done the week before the surgical aspect of the procedure. Periodontal accelerated osteogenic orthodontics procedure. If complex mucogingival procedures are combined with the procedure, the lack of fixed orthodontic appliances may enable easier flap manipulation and suturing. In all cases initiation of orthodontic force should not be delayed more than 2 weeks after surgery. A longer delay will fail to take full advantage of the limited time period that the RAP is occurring(10).

The orthodontist has a limited amount of time to accomplish accelerated tooth movement. This period is usually 4-6 months, after which finishing movements occur with a normal speed. Given this limited "window" of rapid movement, the orthodontist will need to advance arch wires sizes rapidly, initially engaging the largest arch wire possible.

### **Flap Design**

Basic flap design is a combination of a full thickness flap in the most coronal portion and split thickness in the apical portions. Split thickness dissection is done to provide mobility of the flap thereby it can be sutured with less tension. Periosteal layer is removed to provide access to the alveolar bone and helps to identify underlying neurovascular structures. Mesial and distal extension can be done to reduce the need for vertical releasing incisions. Interdental papilla should be preserved to obtain better esthetics. So in case of anterior teeth ‘tunneling’ can be done from the distal aspect.(6,11)

### **Decortication**

The purpose of decortication is to initiate RAP response. No 1 or No 2 round bur and piezoelectric knife can be used. Between the root prominences vertical groove is placed which extends 2 to 3 mm below the crest of the bone. Then vertical corticotomies are connected with the circular shaped corticotomy. Care should be taken to avoid damage to the underlying neurovascular structure.(12,13,14) (Fig. 4, Fig. 5)

### **Grafting**

Grafting is done in the areas that have undergone corticotomies. Volume of the graft material depends on direction and amount of tooth movement, pretreatment thickness of alveolar bone, and need for alveolar support. Most commonly used materials are deproteinized bovine bone, autogenous bone, decalcified freeze dried bone allograft. Use of platelet-rich plasma or calcium sulfate increases the stability of the graft material. Flaps are closed with nonresorbable interrupted sutures and left in its place for 1-2 weeks.(15)

### **Closure**

The flaps are approximated with non resorbable interrupted sutures without excessive tension<sup>15,18</sup>. The specific suture used is based upon the thickness of the tissues<sup>18</sup>. The sutures are then left in place for a minimum of 2 weeks. For the epithelial attachment to re-establish itself, it is important to allow the sutures to be left for a sufficient period of time. Premature suture removal may lead to flap displacement, dark triangles, and gingival recession .(14)

### **Orthodontic Treatment**

The placement of orthodontic brackets and engagement of light arch wires is typically done the week before the surgical phase is performed. However some authors have bracketed after surgery, enabling easier flap manipulation and suturing. In all cases initiation of orthodontic force should not be delayed more than 2 weeks after surgery. This is because a longer delay will fail to take full advantage of the limited time period that the RAP is occurring. Unlike conventional orthodontics, the orthodontic appliance should be activated every two weeks until the end of treatment. (16)

The orthodontist has a time period of 4-6 months to accomplish the accelerated tooth movement. Finishing movements can then occur at normal speeds. Given this limited initial time frame, the orthodontist will need to advance arch wire sizes rapidly, initially engaging the largest arch wire possible. The amount of orthodontic force to be applied is still debated. It is generally accepted with corticotomies heavier forces and more frequent reactivation is needed as compared with conventional orthodontic treatment. The method of anchorage used will also vary depending on amount of force applied and tooth movement required.(16)

### **Postsurgical Management**

Antibiotics, analgesics and antiseptic mouthwash should be prescribed to the patient. Long-term administration of nonsteroidal anti-inflammatory agents is discouraged as these may interfere with the regional acceleratory process(15). To decrease any postoperative swelling, icepacks can be applied to the affected areas. The patient should be recalled to the periodontist every 3 months during orthodontic treatment for the assessment of periodontal health and oral hygiene status(17).

**Contemporary Techniques:** Wilcko et al later adapted the corticotomy technique by incorporating alveolar augmentation and connective tissue grafting. Wilcko renamed the technique as Periodontal Accelerated Osteogenic Orthodontics. Grafting can be carried out in most areas that have undergone corticotomies. The volume of the graft material used is dictated by the direction and amount of tooth movement predicted, the pre-treatment thickness of alveolar bone and the envisaged need for buccal support by alveolar bone. No data comparing grafting material in conjunction with corticotomies is currently available. Commonly used materials are deproteinised bovine bone and autogenous bone. (18)

Periodontal Accelerated Osteogenic Orthodontics can further be successfully combined with gingival augmentation. This is particularly important to the adult patient who presents with gingival recession. In these

situations a subepithelial connective tissue graft is placed over the root surface in addition to the particulate graft placement.(18)

### **Clinical Implications**

**a)Molar Distalisation;** John V Mershon has done molar distalisation in just 2weeks with corticomy.(19)

**b)Molar Mesialization;** Watted et al. have shown how effective and how fast the mesial movement of the Molar in the lower arch after the corticotomy. This case shows the effect of corticotomy on the right side. The corticotomy was done so that the mesial movement of the tooth 36 is easier and more effective. The gaps closing in this quadrant should be distally (**Fig.6-Fig.15**)

### **c) Molar Intrusion**

Molar intrusion by 4mm was done only in in the 2.5 months with corticomy. Yao et al used skeletal anchorage to obtain an average of 3 to 4 mm of intrusion in 7.6 months. Sherwood et al obtained 4mm of intrusion in 6.5 months using mini-titanium plates. Enacaret al registered approximately 4 mm of intrusion in 8.5 months using a modified transpalatal arch.(16)

### **d) Facilitate Eruption of Impacted Teeth**

According to T. J. FischerCorticotomy assisted impacted canines moves at a rate of 1.06 mm/month vs. 0.75 mm/month for the conventional canines.

The reduction in treatment time rangedfrom 28% to 33%.(20)

### **e) Manipulation of Anchorage**

John V Merson has shown molar distalization with segmental corticotomy around the molars, the anchorage value and resistance of the molars to distal movement is effectively reduced no any extra anterior anchorage devices required. Because corticomy increases remodeling at the localized site only this may be the reason for increase in anchorage because anchorage also depends upon the bone density.(19)

### **f) Resolve Crowding and Shorten Treatment Time**

Corticomy resolves crowding in a shorter period of time, reducing the treatment time to as little as one fourth the time usually required for conventional orthodontics Wilcko1 also reported a case of an adult female whowas treated in only 4.5 months.(6,7,8,9)

### **Complications**

Although Periodontal accelerated osteogenic orthodontics may be considered a less-invasive procedure than osteotomy-assisted orthodontics or surgically assisted rapid expansion, there have still been several reports regarding adverse effects to the periodontium after corticotomy, ranging from no problems to slight interdental bone loss and loss of attached gingiva, to periodontal defects observed in some cases with short interdental distance(18,20,21). Subcutaneous hematomas of the face and the neck 22,5 have been reported after intensive corticotomies . In addition, some post-operative swelling and pain is expected for several days.(16,18,20,21)

No effect on the vitality of the pulps of the teeth in the area of corticotomy was reported(23). Long-term research on pulpal vitality after rapid movement has not been evaluated in the literature. In an animal study, Liou et al.(24)demonstrated normal pulp vitality after rapid tooth movement at a rate of 1.2 mm per week. However, pulp vitality deserves additional investigation. It is generally accepted that some root resorption is expected with any orthodontic tooth movement<sup>25</sup>. An association between increased root resorption and duration of the applied force was reported(25,26,27). The reduced treatment duration of Periodontal accelerated osteogenic orthodontics may reduce the risk of root resorption. Ren et al. (28)reported rapid tooth movement after corticotomy in beagles without any associated root resorption or irreversible pulp injury. Moon et al. reported safe and sufficient maxillary molar intrusion (3.0 mm intrusion in two months) using corticotomy combined with a skeletal anchorage system with no root resorption. Long-term effect of Periodontal accelerated osteogenic orthodontics on root resorption requires further study.(16)

## **II. Discussion**

CAO can play an important role in the comprehensive treatment of a patient's occlusal and aesthetic needs. This technique has been shown to decrease treatment time, enhance post-treatment stability and limit the need for orthognathic surgery. Further advantages include; less root resorption due to the decreased resistance of cortical bone, relapse is reported to the low and there less need for extra-oral appliances and head gear. Bone

grafting techniques can also be employed to increase post treatment alveolar bone width as can the incorporation of connective tissue grafts to improve aesthetics and gingival health. Depending on the method of the surgical cuts, CAO can be used to expedite the rate of movement of individual teeth (e.g. canines) or dental segments (e.g. incisor retraction). With CAO, patients will be in fixed appliances for a shorter period than with conventional treatment; consequently there is a decreased risk of enamel decalcification and periodontal disease. **Suya** reported corticotomy-assisted orthodontic treatment of 395 adult Japanese patients. **Suya**'s technique differed from Kole's with the substitution of a subapical horizontal corticotomy cuts in place of the horizontal osteotomy cut beyond the apices of the teeth (corticotomy: thinning of cortical plate without penetrating medullary bone, osteotomy: complete cut through cortical plate to medullary bone). Fixed orthodontic appliances were used. Some cases were completed in 6 months, other cases were completed in less than 12 months. **Suya** contrasted his technique with conventional orthodontics in being less painful, producing less root resorption, and exhibiting less relapse. Outstanding results and extreme patient satisfaction with corticotomy procedures were reported. He believed that the tooth movements were made by moving blocks of bone using the crowns of the teeth as handles. Completing tooth movement in 3–4 months were recommended, after which time the edges of the blocks of bone would begin to fuse together.(4)

**Wang et al.**, conducted a study on an animal model for corticotomy and osteotomy-assisted tooth movement in the rat. They found that the results of computerized tomograms demonstrated that alveolar corticotomies and osteotomies produced different bone responses.(29,30)

**Duker** investigated how corticotomy affected the vitality of the teeth and the marginal periodontium in beagle dogs. Rearrangement of the teeth within a short time after corticotomy damaged neither the pulp nor the periodontal ligament (PDL). He supported the idea of preserving the marginal crest bone in relation to interdental cuts; these cuts must always be left at least 2 mm short of the alveolar crestal bone level. These initial approaches included some types of alveolar osteotomy alone or combined with corticotomy, called "bone block movement." Traditionally, vertical and horizontal osteotomies have had an increased risk of postoperative tooth devitalization or even bone necrosis, depending on the severity of injury to the trabecular bone. There is also an increased risk of periodontal damage, mainly in cases in which the interradicular space is less than 2 mm.(31)

**T. J. Fischer** evaluate the effectiveness of a new surgical technique in the treatment of palatally impacted canines. Six consecutive patients presenting with bilaterally impacted canines were compared. One canine was surgically exposed using a conventional surgical technique while the contralateral canine was exposed using a corticotomy-assisted technique. After tooth movement was completed, statistical comparisons of the two methods revealed a reduction of treatment time of 28–33% for the corticotomy-assisted canines. No significant differences were observed in final periodontal condition between the canines exposed by these two methods.(32)

**Yao et al.** described molar intrusion of 4 mm in 7.6 months using these temporary devices. On the other hand, the same procedure combined with CAO can achieve the same amount of intrusion in 2.5 months(33).

**Dibart et al.** proposes a technique that changes the flap for the tunnelization. However, this procedure is complex, and it is also quite difficult to be sure that the graft is placed under the periosteum. Furthermore, it is not clear how the corticotomy can be performed between each tooth by means of tunnelization. This approach does not allow a corticotomy in between each tooth, a condition that produces accelerated movement.(13)

**Park et al** introduced the alternative approach consisting of incisions directly through the gingival and bone using a combination of blades and a surgical mallet. While decreasing the surgical time (no flaps or sutures; only cortical incisions), this technique did not offer the benefits of bone grafting to increase periodontal support in the areas where expansive tooth movement was desired. In addition, the extensive hammering in office to perform the cortical incisions appears to certain patients to be somewhat aggressive. Moreover, dizziness and benign paroxysmal positional vertigo have been reported, following the use of the hammer and chisels in the maxilla (34) The original technique described by Kole included a combined inter radicular corticotomy and supra apical osteotomy. Although the results of the Kole osteotomies were stable, pulp mortifications were not rare. Later, the supra-apical osteotomy was replaced by corticotomy, and labial and lingual corticotomy cuts were used to circumscribe the roots of the teeth.(1)

**Aboul-Ela et al.** using only buccal cortical perforations found that on the side where the corticotomy was performed individual tooth movement velocity was two to three times faster than on the control side. This result agrees with the findings of Wilcko et al. (2001, 2009), suggesting that the rapid rate of tooth movement seems to depend mostly on RAP rather than bony block movement.(35)

The combination of orthodontics and corticotomies described up to 2009, show a positive impact in terms of reducing overall orthodontic treatment times (Wilcko et al., 2009). However, these techniques have not been widely embraced by the dental community since they require extensive full thickness flap elevation and in cases of osteotomy, an invasive procedure associated with postoperative discomfort and a high risk of complications leading to a low acceptance by the patient. On the other hand, there is no consensus in the literature about different techniques used for surgery and orthodontics.(36)

The orthodontic results obtained with the minimally invasive technique proposed herein are similar to those observed in the literature by Wilko et al., (2009) and Vercelloti & Podesta, and treatment times are reduced by 30% to 70% compared with conventional orthodontic treatments.(37)

**Nowzari et al.**, who were first to document the use of particulate autogenous bone graft with PAOO™, initiated orthodontic movement immediately after surgery and completed the treatment in 8 months for the case of a 41-year-old male with class II, division 2 crowded occlusion. They also performed re-entry one year after the corticotomy procedure and reported that the thickness of the buccal plate in both arches remained unchanged, alveolar height was maintained and no new fenestration or dehiscence was observed.(15)

**Dibart et al.** reported a 26-year-old female with a Class I pattern with slightly retruded maxilla and mandible and a normodivergent mandible, presenting her chief complaint as ‘I have an unpleasant smile’. They utilised PAOO™ technique to shorten the treatment time and finalized the active orthodontic treatment in 17 weeks. They also suggested piezoincisions combined with a localised tunnelling approach in order to perform hard and soft tissue augmentation, enhance the periodontium and increase the scope of the OTM.(13)

**Einy et al.** presented six cases of adult patients from both genders, with a malocclusal variety of Angle class II and class III relationships, a constricted maxilla and maxillary dental arch, a bilateral posterior cross-bite and an anterior open bite, seeking a quick orthodontic solution for aesthetic and functional disorders. They concluded that PAOO™ could serve as a reasonable and safe option in adult patients for the growing demand of shortened treatment duration of OTM in three dimensions.(38)

**Aljhani and Zawawi** reported a 25-year-old female with a chief complaint of ‘I want my teeth fixed quickly’, drafted for PAOO. They bonded initial fixed orthodontic appliances one week before corticotomy and orthodontic activation was performed every two weeks. Total treatment ended in 8 months without adverse effects.(39)

**Kim et al.** demonstrated two adult cases with Class III malocclusion undergoing anterior decompensation for mandibular setback surgery. They compared the efficiency of conventional decompensation with temporary skeletal anchorage decompensation by using a device combined with guided tissue regeneration. They referred PAOO as a safe and effective technique for the facilitation of decompression of the mandibular anterior teeth in severely compromised dentitions.(40)

**Yezdani** demonstrated a 29-year-old female with Class I malocclusion and increased bidentoalveolar protrusion, treated with PAOO™. He stated that periodontal alveolar augmentation with an alloplastic graft material repaired the dehiscence’s, enhanced the bone volume and improved soft tissue profile remarkably, as the case was concluded at seventh month postoperatively.

The corticotomy-assisted orthodontic treatment has been demonstrated to be effective in several distinct clinical situations such as crowded dentition, canine retraction after premolar extraction, facilitation of impacted tooth eruption, facilitation of slow orthodontic expansion, molar intrusion with open bite correction and enhancement of postorthodontic stability.(42)

### **III. Conclusion**

CAO is a promising adjuvant technique, indicated for many situations in the orthodontic treatment of adults. It has been used in some limited cases to avoid secondary effects of conventional orthodontics, such as root resorption in molar intrusion or periodontal dehiscence in slow tooth expansion. However, its main advantages are reduction of treatment time and postorthodontic stability, which may allow its generalized use in many adult patients without active periodontal pathology. The biological principle of this method is based on

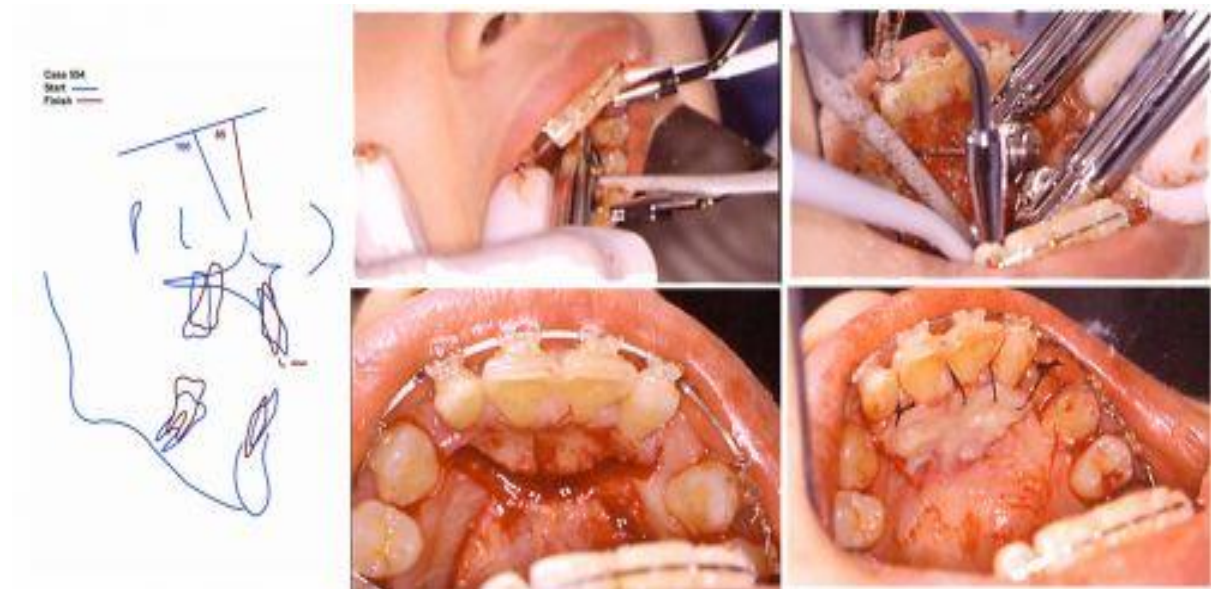
temporary reduction of medullar bone density (transitory osteopenia) within a 3-4-month window, which allows more physiological tooth movement inside the alveolar bone .

### References

- [1]. Köle H. Surgical operations on the alveolar ridge to correct occlusal abnormalities. *Oral Surg Oral Med Oral Pathol.* 1959;12:515–29.
- [2]. Guilford SH. *Orthodontia: Or Malposition of the Human Teeth, Its Prevention and Remedy.* Philadelphia, PA: Spangler and Davis; 1893.
- [3]. Hajji SS. The influence of accelerated osteogenic responses on mandibular de-crowding [thesis]. St. Louis, MO; St Louis University: 2000.
- [4]. Suya H. Corticotomy in orthodontics. In: Hösl E, Baldauf A, eds. *Mechanical and Biological Basis in Orthodontics Therapy.* Heidelberg, Germany: Hütlig Buch; 1991:107-226.
- [5]. Fitzpatrick B. Corticotomy. *Aust Dent J.* 1980;25:255–258.
- [6]. Wilcko WM, Wilcko T, Bouquot JE, Ferguson DJ. Rapid orthodontics with alveolar reshaping: two case reports of decrowding. *Int J Periodontics Restorative Dent.* 2001;21:9–19.
- [7]. Wilcko, M.T., Wilko, W.M., Bissada, N.F., . An evidence-based analysis of periodontally accelerated orthodontic and osteogenic techniques: a synthesis of scientific perspective. *Seminars 2008Orthod.* 14: 305-316.
- [8]. Wilcko, M.W., Ferguson, OJ" Bouquot.
- [9]. J.E., Wilcko, M.T., Rapid orthodontic decrowding with alveolar augmentation: case report. *World J. Orthod.* 2003, 4, 197-205.
- [10]. Wilcko, W.M., Wilcko, M.T., Bouquot. J.E., Ferguson, OJ., Accelerated orthodontics with alveolar reshaping. *J.Ortho. Practice* 2000,10, 63-70.
- [11]. Pham- Nguyen K: Micro-CT analysis of osteopenia following selective alveolar decortication & tooth movement. Boston MA, Boston university, 2006
- [12]. D.J. Ferguson, W.M. Wilcko and M.T. Wilcko. Selective alveolar decortication for rapid surgical-orthodontic resolution of skeletal malocclusion treatment. *Distraction osteogenesis of the facial skeleton.* (Italy, pmph usa, 2006) 199-203
- [13]. G. Amit, J.P.S. Kalra, B. Pankaj, S. Suchinder and B. Parul. Periodontally accelerated osteogenic orthodontics (PAOO)- a review. *J Clin Exp Dent,* 4(5), 2012, 292-296.
- [14]. S. Dibart, J.D. Sebaoun and J. Surmenian. Piezocision: a minimally invasive, periodontally accelerated orthodontic tooth movement procedure. *Compend Contin Educ Dent ,* 30(6), 2009, 342-344, 346, 348-50.
- [15]. K.G. Murphy, M.T. Wilcko, W.M. Wilcko and D.J. Ferguson. Periodontally accelerated osteogenic orthodontics: a description of the surgical technique. *J Oral Maxillofac Surg,* 67(10), 2009, 2160-2166.
- [16]. H. Nowzari, F.K. Yorita and H.C. Chang. Periodontally accelerated osteogenic orthodontics combined with autogenous bone grafting. *Compend Contin Educ Dent,* 29(4), 2008, 200-206.
- [17]. Moon CH, Wee JU, Lee HS. Intrusion of overerupted molars by corticotomy and orthodontic skeletal anchorage. *Angle Orthodontist.* 2007;6:1119
- [18]. A.S.T. AlGhamdi. Corticotomy facilitated orthodontics: Review of the technique. *The Saudi Dental Journal,* 22(1), 2010, 1-5.
- [19]. Wilcko MT, Wilcko WM et al. Accelerated osteogenic orthodontics technique. *J Oral Maxillofac Surg.* 2009;67:2149
- [20]. Graber , vandarshall, *Current principles and technique* 5th ed
- [21]. Fischer TJ. Orthodontic treatment acceleration with corticotomy assisted exposure of palatally impacted canines. *Angle Orthod* 2007; 77: 417-20. 21
- [22]. Iino S, Sakoda S, Miyawaki S. An adult bimaxillary protrusion treated with corticotomy-facilitated orthodontics and titanium miniplates. *Angle Orthod.* 2006;76:1074-82.
- [23]. Kwon HJ, Pihlstrom B, Waite DE. Effects on the periodontium of vertical bone cutting for segmental osteotomy. *J Oral Maxillofac Surg.* 1985;43:952-5.
- [24]. Oztürk M, Doruk C, Ozec I, Polat S, Babacan H, Bicakci AA. Pulpal blood flow: effects of corticotomy and midline osteotomy in surgically assisted rapid palatal expansion. *J Craniomaxillofac Surg.* 2003;31:97-100.
- [25]. Liou EJ, Figueroa AA, Polley JW. Rapid orthodontic tooth movement into newly distracted bone after mandibular distraction osteogenesis in a canine model. *Am J Orthod Dentofacial Orthop.* 2000;117:391-8.
- [26]. Harry MR, Sims MR. Root resorption in bicuspid intrusion. A scanning electron microscope study. *Angle Orthod.* 1982;52:235-58.
- [27]. Kvam E. Scanning electron microscopy of tissue changes on the pressure surface of human premolars following tooth movement. *Scand J Dent Res.* 1972;80:357-68.
- [28]. McFadden WM, Engstrom C, Engstrom H, Anholm JM. A study of the relationship between incisor intrusion and root shortening. *Am J Orthod Dentofacial Orthop.* 1989;96:390-6.
- [29]. Ren A, Lv T, Kang N, Zhao B, Chen Y, Bai D. Rapid orthodontic tooth movement aided by alveolar surgery in beagles. *Am J Orthod Dentofacial Orthop.* 2007;131:160.e1-10.
- [30]. Wang L, Karapetyan G, Moats R, Yamashita DD, Moon HB, Ferguson DJ, et al. Corticotomy-/osteotomy-assisted tooth movement microCTs differ. *J Dent Res* 2008; 87:861-7.
- [31]. Wang L, Won Lee, De-lin Lei, Yan-pu Liu, Dennis-Duke Yamashita, and Stephen L-K Yene. Tissue responses in corticotomy- and osteotomy-assisted tooth movements in rats: Histology and immunostaining. *Am J Orthod Dentofacial Orthop* 2009;136:770.e1-770.e11
- [32]. Duker J. Experimental animal research into segmental alveolar movement after corticotomy. *J Maxillofac Surg.* 1975;3:81–4.
- [33]. Fischer TJ. Orthodontic treatment acceleration with corticotomy assisted exposure of palatally impacted canines. *Angle Orthod* 2007; 77: 417-20
- [34]. Yao CC, Wu CB, Wu HY, Kok SH, Chang HF, Chen YJ. Intrusion of the overerupted upper left first and second molars by mini implants with partial-fixed orthodontic appliances: a case report. *Angle Orthod.* 2004;74:550–7.
- [35]. Park YG, Kang SG, Kim SJ. Accelerated tooth movement by Corticision as an osseous orthodontic paradigm. *Kinki Tokai Kyosei Shika Gakkai Gakujyutsu Taikai, Sokai.* 2006;48:6.
- [36]. Aboul-Ela, S. M.; El-Beialy, A. R.; El-Sayed, K. M.; Selim, E. M.; El-Mangoury, N. H. & Mostafa, Y. A. Miniscrew implant-supported maxillary canine retraction with and without corticotomy-facilitated orthodontics. *Am. J.Orthod. Dentofacial Orthop.,* 139:252-9, 2011.
- [37]. Koudstaal, M. J.; Poort, L. J.; van der Wal, K. G.; Wolvius, E.

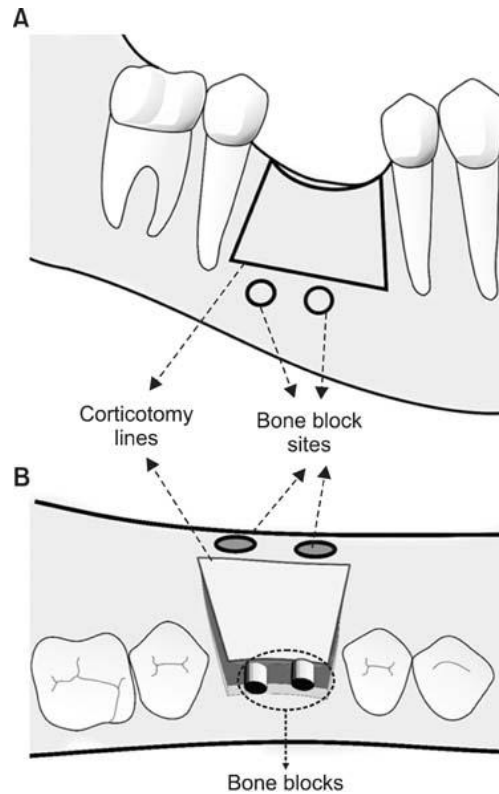


- [38]. B.; PrahI-Andersen, B. & Schulten, A. J. Surgically assisted rapid maxillary expansion (SARME): a review of the literature. *Int. J. Oral Maxillofac. Surg.*, 34:709-14, 2005.
- [39]. Vercellotti, T. & Podesta, A. Orthodontic microsurgery: a new surgically guided technique for dental movement. *Int. J. Periodontics Restorative Dent.*, 27:325-31, 2007.
- [40]. Einy S, Horwitz J, Aizenbud D. Wilckodontics--an alternative adult orthodontic treatment method: rationale and application. *Alpha Omegan*. 2011;104(3-4):102-11.
- [41]. Aljhani AS, Zawawi KH. Nonextraction Treatment of Severe Crowding with the Aid of Corticotomy Assisted Orthodontics. *Case Rep Dent*. 2012;2012:694527
- [42]. Kim SH, Kim I, Jeong DM, Chung KR, Zadeh H. Corticotomy-assisted decompensation for augmentation of the mandibular anterior ridge. *Am J Orthod Dentofacial Orthop*. 2011;140(5):720-31.
- [43]. Yezdani AA. Accelerated orthodontics with alveolar decortication and augmentation: A case report. *Orthodontics* . 2012;13(1):146-55.
- [44]. Cano J, Campo J, Moreno LA, Bascones A. Osteogenic alveolar distraction: a review of the literature. *Oral Surg Oral Med Oral Pathol Oral Radiol Endod*. 2006;101(1):11-2

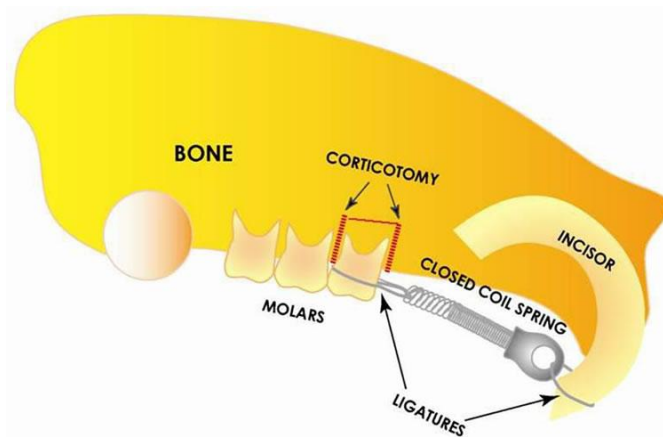


**Fig.1** Flap Design for each type. • Suturing techniques

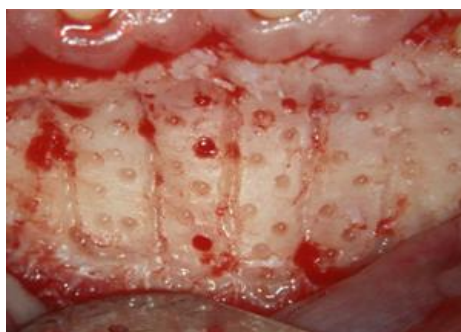



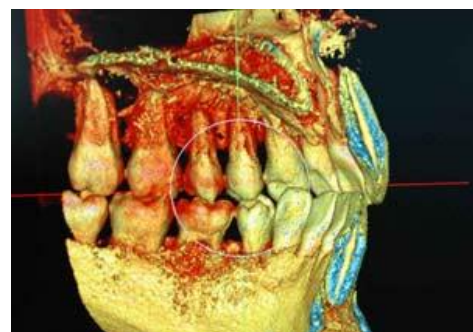**Fig.2** Schematic of the corticotomy procedure. A, Sagittal view. B, Occlusal view.



**Fig.3** vertical and horizontal corticotomy cuts with flap reflection were placed after application of a coil spring.



**Fig.4** Periodontal Accelerated Osteogenic Orthodontics



**Fig.5** Super Corticotomy Orthodontics is a new procedure using Cone Beam CT and Microscope

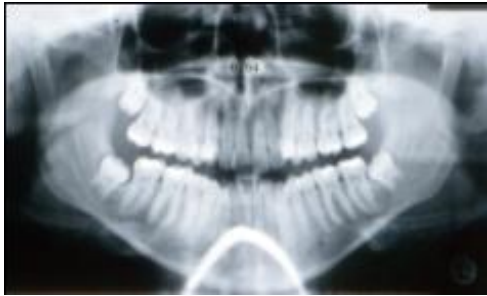

Fig.6 The space situation for the wisdom teeth is unfavorably

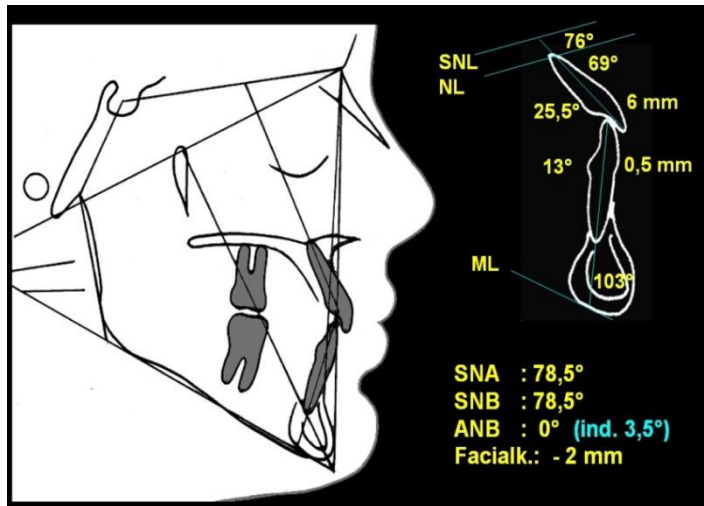
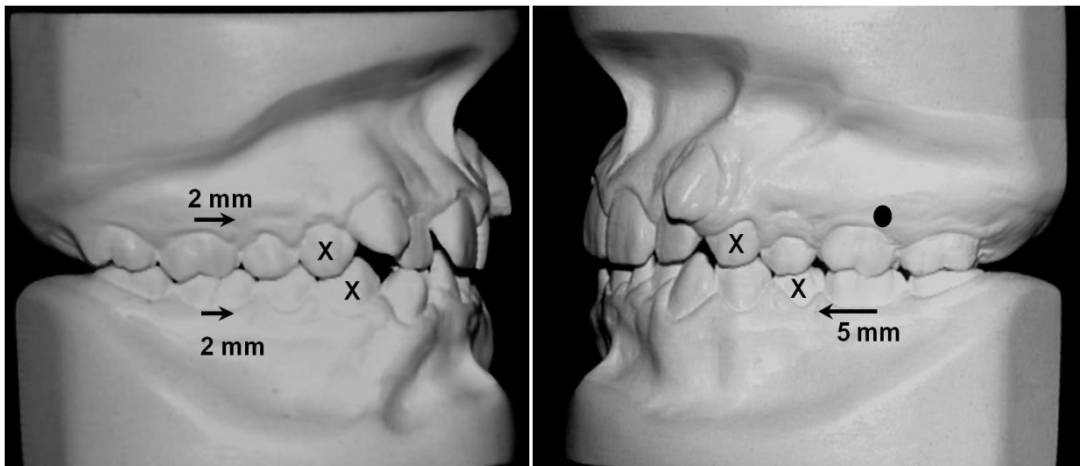
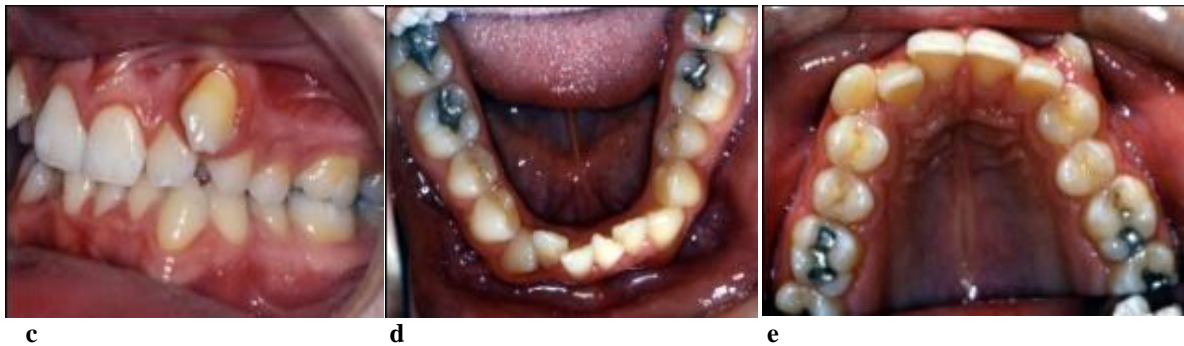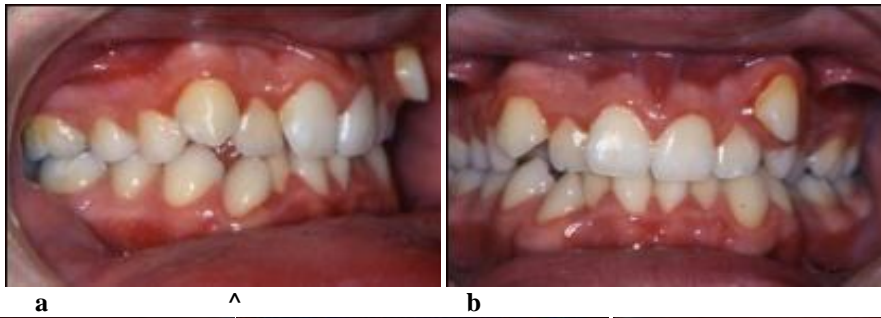

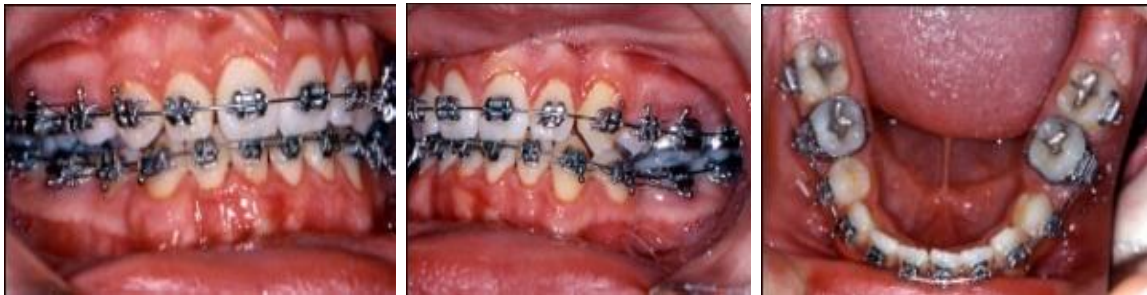
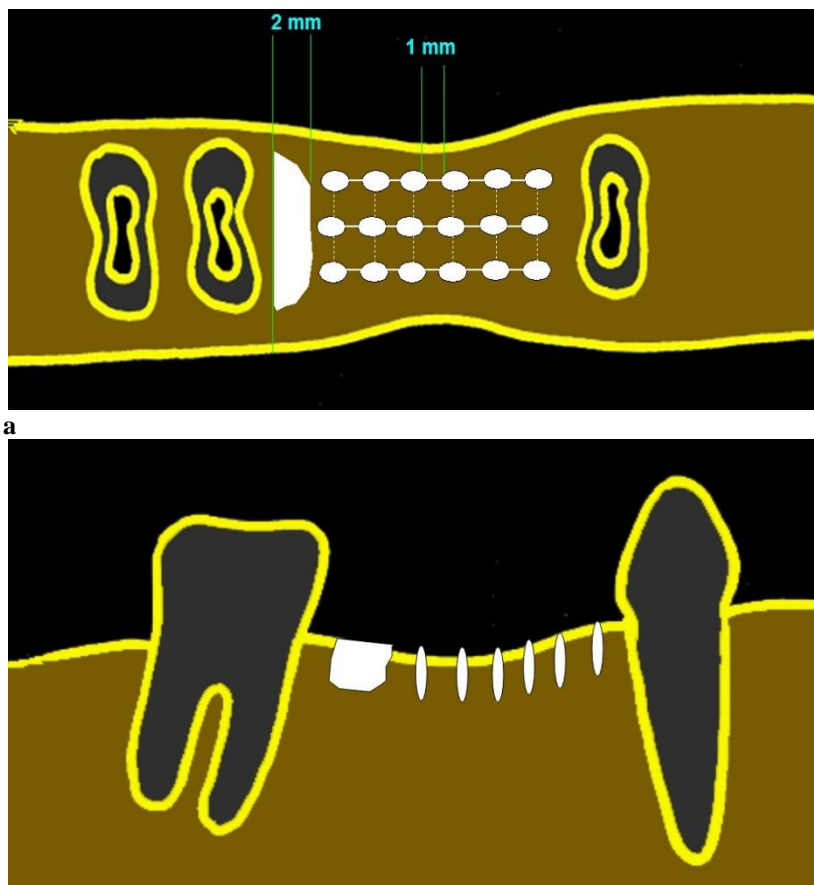
Fig.7 cephalometric before the beginning of treatment



**Fig.8a-g** clinical situation. Severe crowding in both jaws and severe misaligned teeth. Right side class I, class II left a maximum anchorage in the upper jaw left and minimal anchorage in the lower jaw left is required for a class I achieved



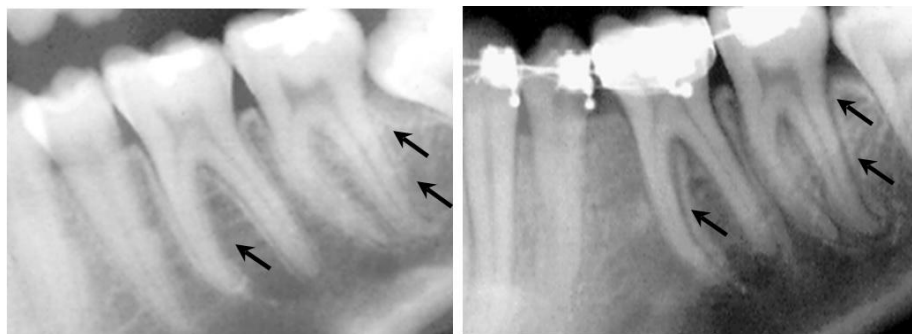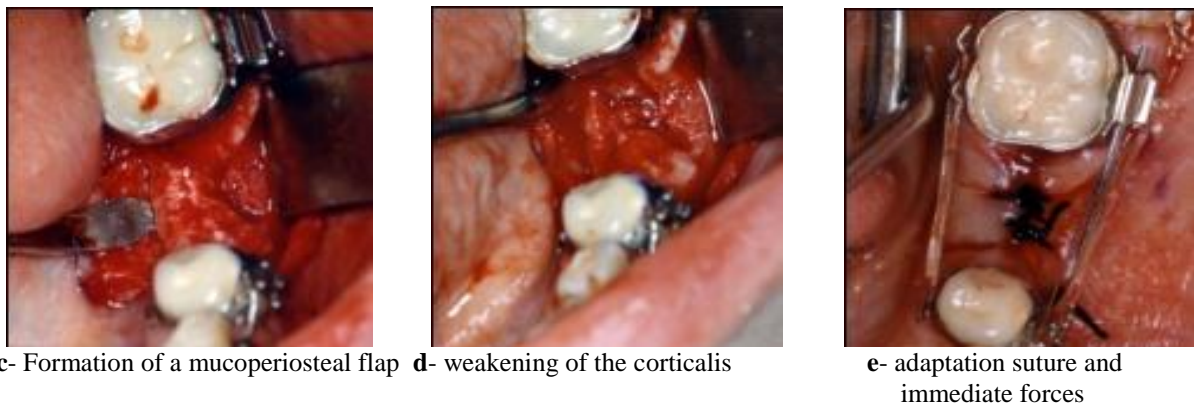
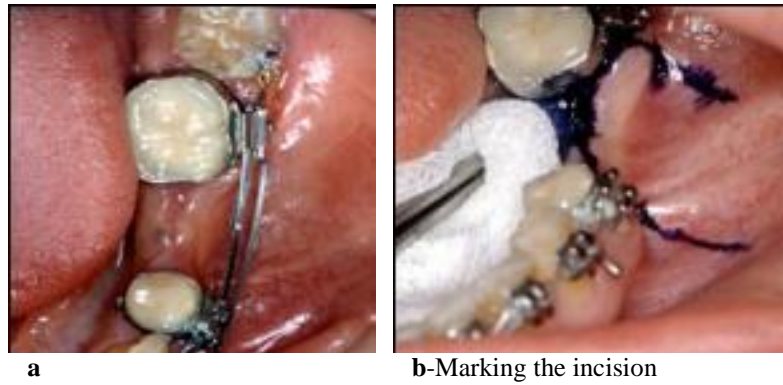
**Fig.9a-c** Situation after leveling and removal of dental crowding. The gap between 36 and 34 must be closed distally. for effective without side effects of tooth mesial movement 36 a bone weakening has been held



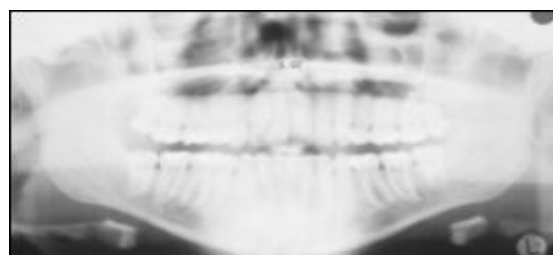
**Fig.10a, b** schematic representation of the surgical weakening of the corticalis

**Fig.11a-e** fotos on surgical procedure of corticotomy:





**Fig.12** the comparison of the PDL of 36 and 37 at the beginning of treatment and after corticotomy and gap conclusion from Distal



**Fig.13** Panoramic view after treatment

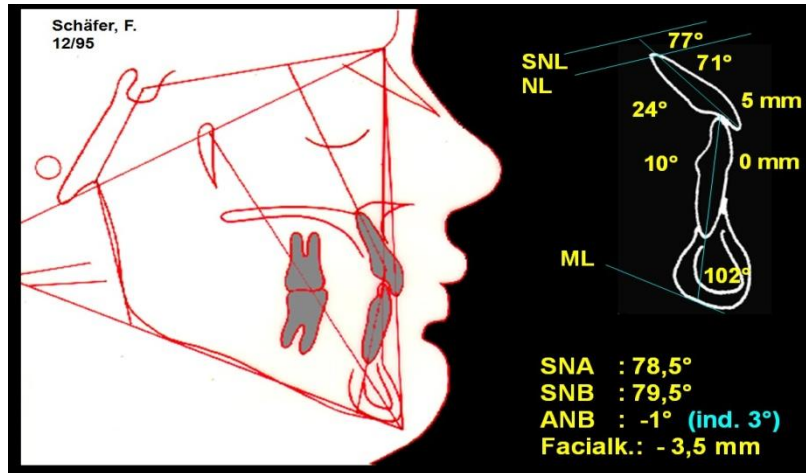


Fig.14 cephalometric after the treatment

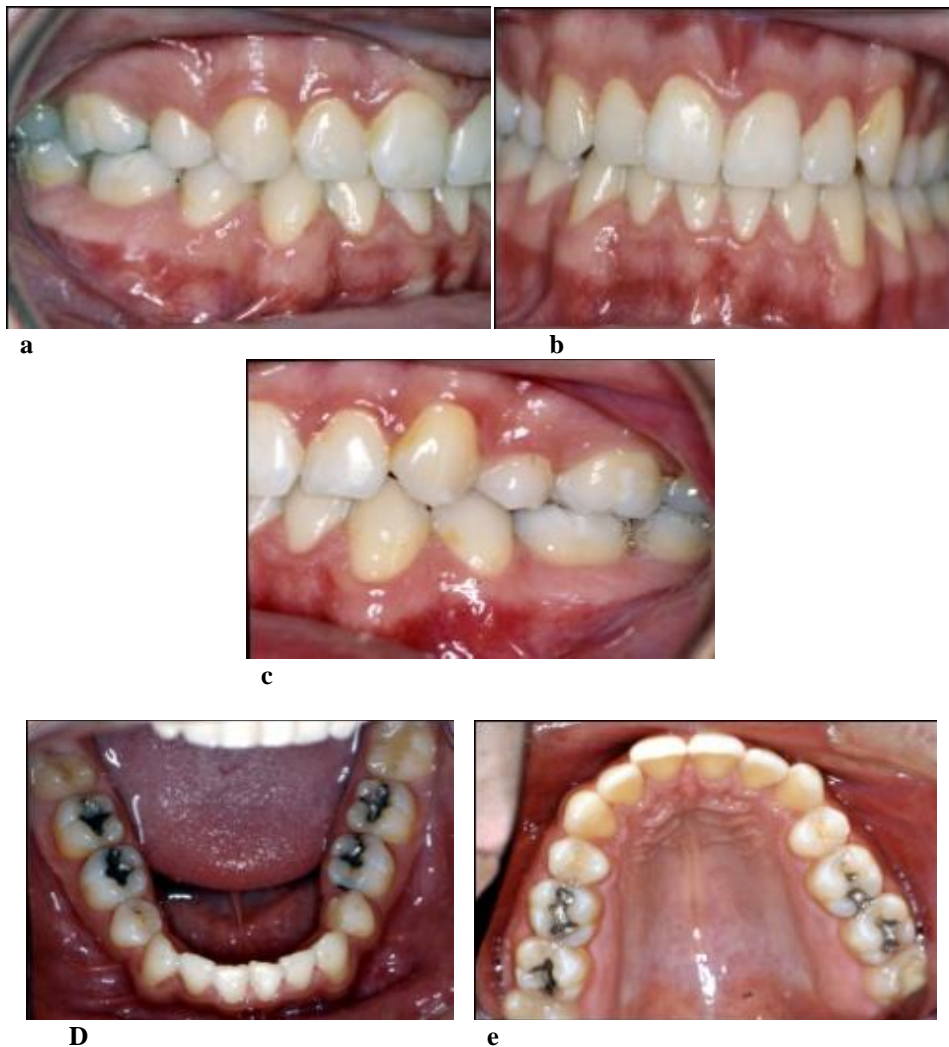


Fig.15a-e clinical situation after the end of treatment. right and left Class I occlusion