

## A rare site of Cystic hygroma

Snehansu Pan MS, DNB

Associate professor, General Surgery Burdwan Medical College, Burdwan-4, W.B, INDIA

---

**Abstract:** Cystic hygroma is not a rare condition. We have seen case of cystic hygroma involving neck. The diagnosis is not difficult.

Recently we have examined a one year old male child with a soft, cystic, translucent swelling over the left side of upper abdomen. It created diagnostic confusion. After investigation it came out to be a cystic hygroma.

Cystic hygroma of the abdominal wall is almost an unreported entity. The importance is that it created diagnostic confusion.

**Key words:** Cystic hygroma; Abdominal wall; Congenital malformation.

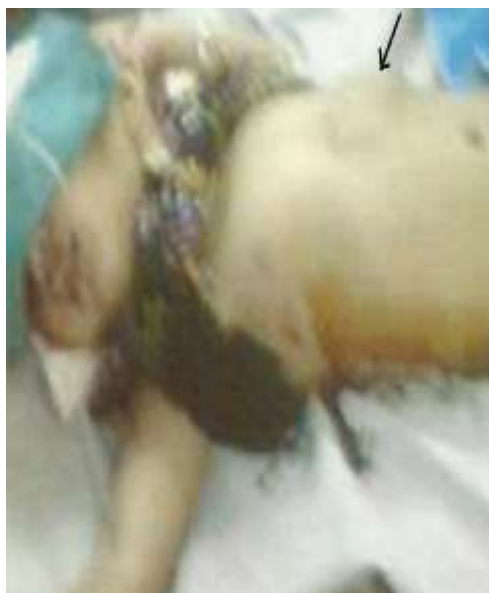---

### I. Introduction

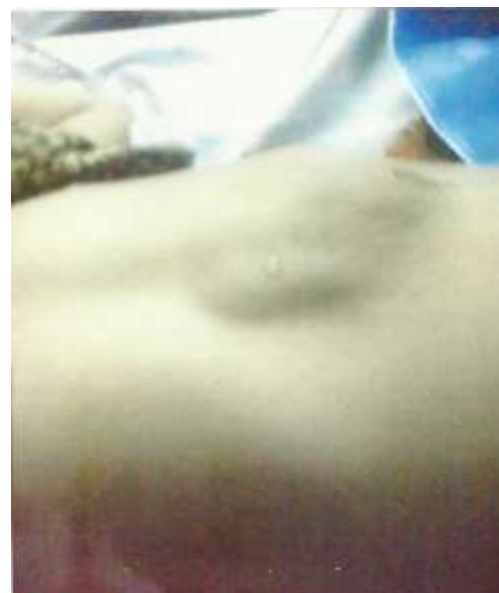Cystic hygroma is a congenital malformation of lymphatic vessels. It is encountered in newborn or early childhood. The commonest site of this lesion is neck. The other sites described in textbooks are axilla, groin, chest wall etc. A cystic hygroma of abdominal wall is unknown. Here is a child with a cystic hygroma of upper abdominal wall.

### II. Case presentation

A one year old male child came to our clinic with a painless swelling over the left side of upper abdomen since birth. There was no history of trauma, fever or pain. The child had a normal vaginal delivery. On examination there was a smooth swelling, 8 cm X 4 cm in size, situated over the left side of upper abdominal wall. There was no skin changes and no pulsation. The swelling was soft, partially compressible, non tender, fixed to skin and deeper structure. It was translucent, having no impulse on straining (crying). There was no audible sound on auscultation. Rest of the examination was normal (Fig 1 & 2).



**Fig 1:** The baby with cystic hygroma of upper abdominal wall: Marked with an arrow



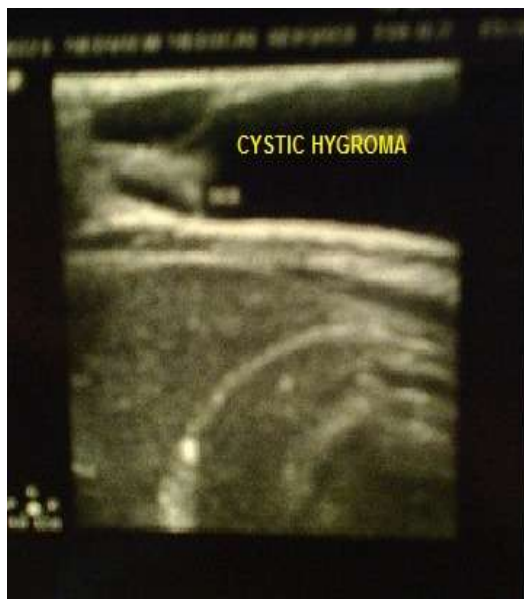**Fig 2:** Same cystic hygroma: close up view

### III. Investigations

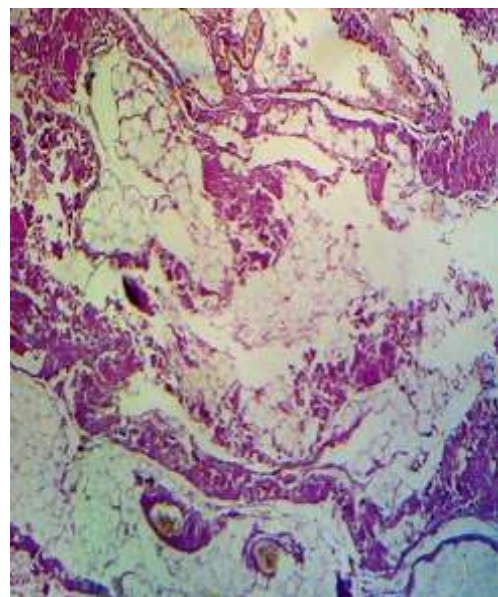
**Ultrasonography:** A well defined cystic lesion, 3.5x1.3 cm seen in the left hypochondrium with low level of internal echoes inside. Septus are seen. On colour mode no obvious vascularity seen (Fig 3).

**Chest x ray:** Normal.

**Histopathology:** Consistent with cystic hygroma (Fig 4).



**Fig 3:** Ultrasonography showing septated cystic lesion between skin and muscle.



**Fig 4:** Histopathology of the cystic hygroma. H & E stain. X 40

#### IV. Discussion

**Embryology:** The lymphatic system arises as sac-like outgrowths from the endothelium from veins in the fifth week of gestation. Six primary lymph sacs are formed: two jugulars, two iliac, one retroperitoneal and one cisterna chyli. If any of these lymph sacs fails to communicate with lymph system, they will form cystic hygroma or cavernous lymphangioma<sup>1</sup>.

**Sites:** First described by Wernher in 1843. Cystic hygroma usually occurs in the lower third of the neck. Often the posterior triangle is involved<sup>2</sup>. Though it can affect any anatomical sub site in human body, the head and neck is affected in 75%, with a predilection for the left side. About 20% occur in the axilla. Other sites include the mediastinum, groin and retroperitoneum<sup>3</sup>. Rare sites of cystic hygroma found in literature are anogenital areas, forehead, orbit, buttock, tongue, gastrointestinal tract, extremity, pelvis<sup>4</sup>. Cystic hygroma of abdominal wall is perhaps yet to be reported.

#### V. Conclusion

Though cystic hygroma can affect any organ, clinical presentation of abdominal wall cystic hygroma is not yet known. So this case is a unique one so far as our knowledge is concerned.

#### Reference

- [1]. Lymphatic system: in Langman's Medical Embryology: editor T.W. Sadler, twelfth edition (2012) p 197-198.
- [2]. Cystic hygroma: in Bailey & Love's Short Practice of Surgery: edited by R.C.G Russell et all, 23<sup>rd</sup> edition (2000) p-700.
- [3]. Cystic hygroma: Jason L Acevedo MD: chief editor emedicine.medscape.com>article>994...2015
- [4]. Vascular Anomalies: Emily R et all: in surgical clinics of North America number 2 volume 86 April 2006 p-409-410.