

Peripheral Ossifying Fibroma-A case report with Cone Beam CT features

Anuraag B. Choudhary¹, Mukta B. Motwani², Mayur B. Chaudhary³,
Shweta M. Chaudhary⁴, Pankaj J. Banode⁵, Abhishek S. Tidke⁶, Shailesh D.
Kumbhare⁷, Trupti D. Chordia⁸

¹Reader, Department of Oral Medicine and Radiology, VSPM Dental College & Research Centre, Digidoh hills, Nagpur, India

²Professor & Head, Department of Oral Medicine and Radiology, VSPM Dental College & Research Centre, Digidoh hills, Nagpur, India

³Reader Department of Oral Pathology and Microbiology Bharti Vidyapeeth Dental College Pune, India

⁴Reader Department of Pedodontia Bharti Vidyapeeth Dental College Pune, India

⁵Professor, Department Radio-diagnosis & Imaging Science, AVBRH, Sawangi, Wardha, India

⁶Senior Lecturer, Department of Oral & Maxillofacial Surgery Saraswati Dhanwantri Dental College, Parbhani, India

⁷MDS Oral & Maxillofacial Surgeon, Nagpur, India,

⁸MDS, Oral Pathology and Microbiology, Nagpur, India

Abstract: Many types of localized reactive lesions may occur on the gingiva, including focal fibrous hyperplasia, pyogenic granuloma, peripheral giant cell granuloma and Peripheral ossifying fibroma (POF). These lesions may arise as a result of such irritants as trauma, microorganisms, plaque, calculus, restorations and dental appliances. POF is a non-neoplastic enlargement of the gingiva and is precipitated by local irritation and minor trauma. Although being reported to reach more than 6 cm, they are usually less than 1.5 cm in diameter, and the diagnosis can be made by clinical inspection and biopsy. Some authors have called it fibrous epulis, calcifying fibroblastic granuloma, or peripheral fibroma with calcification. Clinically the lesion is asymptomatic, firm, pinkish red and pedunculated, histologically showing cellular, fibrous connective tissue stroma with calcified osseous and cementum-like calcifications. Radiographic features of the peripheral ossifying fibroma vary. Radiopaque foci of calcifications have been reported to be scattered in the central area of the lesion, but not all lesions demonstrate radiographic calcifications. The purpose of this article is to present a case of large POF, briefly review the current literature on this condition and emphasize the utility of Cone Beam Computed Tomography (CBCT) as an imaging modality for diagnosing radiographically such lesions.

Keywords: Peripheral ossifying fibroma, fibrous epulis, calcifying fibroblastic granuloma, peripheral fibroma with calcification and Cone Beam Computed Tomography

I. Introduction

The introduction of the paper should explain the nature of the problem, previous work, purpose, and the contribution of the paper. The contents of each section may be provided to understand easily about the paper. A 36 year female patient reported to the department of Oral Medicine and Radiology with the chief complaint of painless mass in left maxillary posterior tooth region of jaw since 10 years. The lump was interfering with her bite and it bleeds on brushing. Patient also gave history of repeated trauma by tooth brush. Physical examination revealed a dome shaped pedunculated, rubbery, non-tender and pinkish mass on the attached gingiva in relation to 23, 24 and 25 with a smooth mucosal surface and firm in consistency. Patient gave no history of tooth mobility and tingling and numbness in same region, no epistaxis or reduced appetite and loss of weight. It measured 2.5 cm in diameter (fig.1 and 2). The lesion extended up to the level of the occlusal plane. The patient's past dental and medical histories were non-contributory. Intraoral periapical radiographic examination (fig. 3) revealed a radiopaque mass in relation to crown of 23, 24 and 25 with reduced density of bone periapical to 22, 23 and 24 with loss of lamina dura with 23 and 24. On occlusal radiograph the radiopaque mass was evident buccal to 23, 24 and 25 region (fig. 4) of size approximately 2×2 cm with well defined margins. The clinico-radiographic diagnosis of peripheral ossifying fibroma was given with differential diagnosis of traumatic fibroma and pyogenic granuloma. The 3-dimensional reconstruction images on CBCT (fig. 5a and 5b) revealed the calcific foci in same region attached buccal alveolar bone supporting 23, 24 and 25. Similarly the multiplanar reconstruction (MPR) CBCT images of the patient revealed the radiopaque mass in all the three-axial, coronal and sagittal plane (fig 6 a, b and c). Excisional biopsy was performed, where the tissue was found to be friable and was removed in toto and the periosteum was curetted and the exposed bone was covered with

mucosal flap from the buccal mucosa and the specimen was sent for histopathologic examination, the report of which was suggestive of peripheral ossifying fibroma.

II. Discussion

Ossifying fibroma occurs mostly in craniofacial bones and is generally categorized into two types, central and peripheral. The central type arises from the endosteum or the periodontal ligament (PDL) adjacent to the root apex and expands from the medullary cavity of the bone. On the other hand, the peripheral type shows a contiguous relationship with the PDL, occurring solely on the soft tissues overlying the alveolar process.^{1, 2} Intra-oral ossifying fibromas have been described in the literature since the late 1940s.³ Many names have been given to similar lesions, such as epulis,³ peripheral fibroma with calcification,⁴ peripheral ossifying fibroma,^{5, 6} calcifying fibroblastic granuloma, peripheral cementifying fibroma, peripheral fibroma with cementogenesis⁷ and peripheral cemento-ossifying fibroma.⁸ The sheer number of names used for fibroblastic gingival lesions indicates that there is much controversy surrounding the classification of these lesions.⁸ In spite of confusing terminology, it is generally believed that POF is not the peripheral counterpart of the central ossifying fibroma of the mandible and maxilla, but instead is a reactive gingival lesion known under the generic name of epulis.⁹ It has also been suggested that the POF represents a separate clinical entity rather than a transitional form of pyogenic granuloma, peripheral giant cell granuloma or irritation fibroma.³ Eversole and Rovin⁵ stated that, with the similar sex and site predilection of pyogenic granuloma, PGCG and POF, as well as similar clinical and histologic features, these lesions may simply be varied histologic responses to irritation. Gardner⁶ stated that POF cellular connective tissue is so characteristic that a histologic diagnosis can be made with confidence, regardless of the presence or absence of calcification. Buchner and Hansen¹⁰ hypothesized that early POF presents as ulcerated nodules with little calcification, allowing easy misdiagnosis as a pyogenic granuloma.

The aetiology of POF is unclear. Trauma or local irritation such as dental plaque, calculus, ill-fitting dental appliances and poor-quality dental restorations are all known to precipitate the development of POF.^{6, 11, 12} Inflammatory hyperplasia originating in the superficial PDL is considered to be a factor in the histogenesis of the POF.¹⁰ The peak incidence of POF is between the second and third decades. Women are more likely to be affected than men.^{10, 12, 13} Clinically, the POF presents as an exophytic, smooth-surfaced, pink or red nodular mass that is sessile, or is less frequently seen on a pedicle. The inter-dental gingival papilla is frequently involved. Most of the reported POFs have been 1–2 cm in size.^{10, 11, 14}

In our case, scattered calcifications of the POF were best depicted on occlusal radiograph but the exact dimension of the lesion was evident on the CBCT images. At CBCT imaging, the area of calcification showed a radiopaque calcific mass in 23, 24 and 25 region in 3-D reconstruction where as the MPR images in axial, coronal and sagittal planes were used to evaluate the extent as well as the size of the image pre-operatively. A POF is known to have a variable amount of mineralization in the form of dystrophic calcifications, bone (woven or lamellar) and cementum-like material.¹⁰ Although radiological reports of POFs are rare, a plain radiograph may detect the focal calcifications in a POF.⁶ The another advantage of the CBCT is in detecting even small calcific lesions which are maturing initially as the flat panel detector of CBCT machine is very much sensitive even for a small variation in the amount and intensity of the x-ray photons reaching it and thus interpreting this signals and converting it into the digital to be displayed on computer screen. It can also evaluate the amount of the bone resorbed in buccal as well as palatal aspect of the teeth in area of complaint, which is probably the limitation of the conventional radiographs like intra-oral as well as occlusal. POFs can be clinically misdiagnosed as a pyogenic granuloma at an early stage.¹¹ Pyogenic granulomas are usually very small (from a few millimeters to 1 cm) and only occasionally show calcification. However, some researchers believe that POF is related to pyogenic granuloma and is probably a matured pyogenic granuloma containing fibrosis and calcification.¹

III. Figures

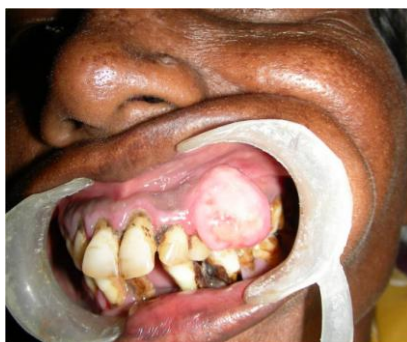

Fig.1 Intraoral photograph showing soft tissue growth in relation to 23, 24 and 25

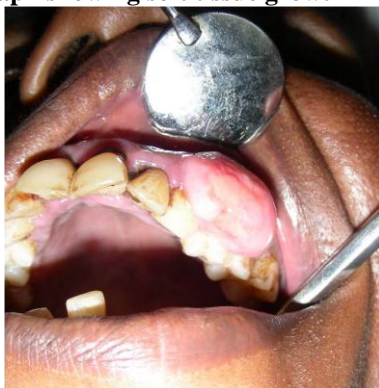


Fig.2 Intraoral photograph showing the extent of the growth

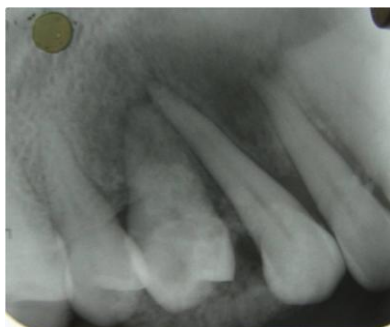

Fig.3 Intraoral periapical radiograph showing radiopaque mass coronal to 23, 24 and 25 with reduced bone density and loss of lamina dura of 23 and 24

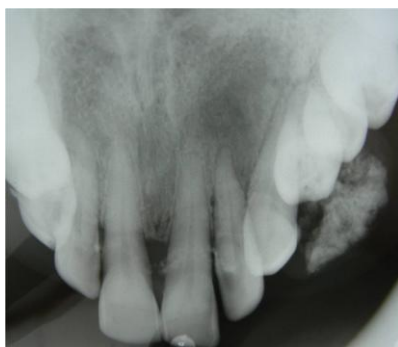


Fig. 4. Occlusal radiograph showing a 2x2 cm radiopaque mass buccal to 23, 24 and 25

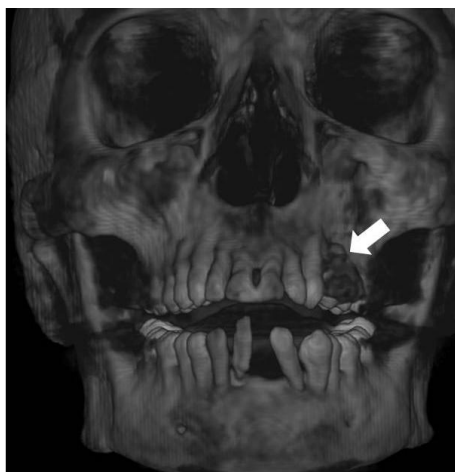


Fig. 5a 3-D CBCT image frontal view showing the calcific foci in relation to 23, 24 and 25.

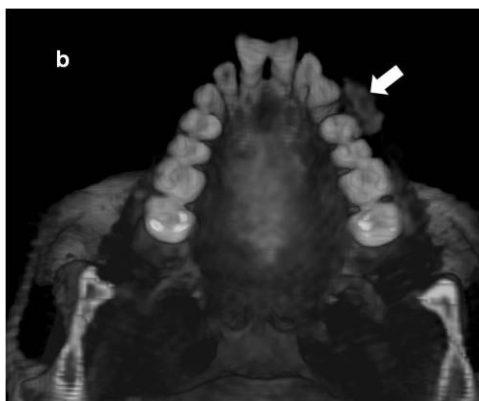


Fig. 5b 3-D CBCT image occlusal view showing the calcific foci in relation to 23, 24 and 25.

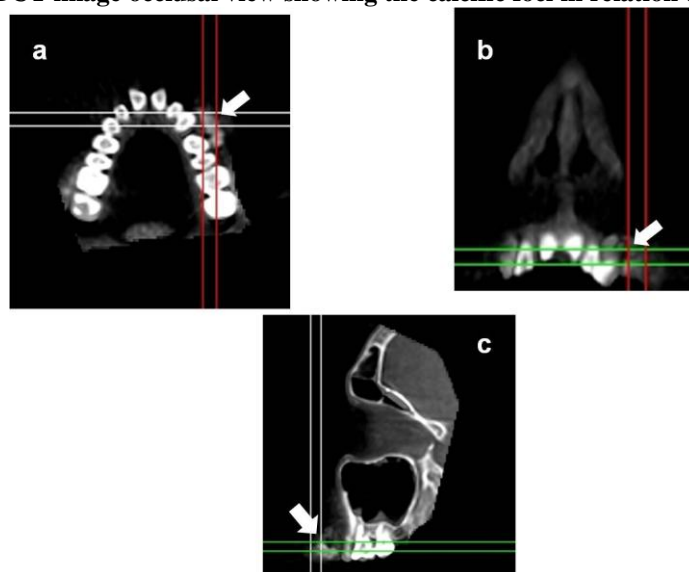


Fig. 6 a, b and c. MPR CBCT image showing the radiopaque mass in buccal relation to 23, 24 and 25.

IV. Conclusion

In conclusion, POF is a slowly progressing, pink in colour as that of mucosa, firm to hard, non-tender lesion with speckled calcifications usually seen in the anterior oral cavity. Many cases will progress for long periods before patients seek treatment because of the lack of symptoms associated with the lesion. A slowly growing pink soft tissue nodule in the anterior maxilla of an adolescent should raise a suspicion of a POF. Discussion of the differential diagnosis should be done tactfully to prevent unnecessary distress to the patient and family. In the current case, the patient experienced distress related to the suggestion of malignancy before referral for treatment and definitive diagnosis. The conventional radiographs along with CBCT images helped in diagnosing as well as treating the aforementioned case. However the advantages of the CBCT like low radiation cost comparatively to the CT scan, though greater than conventional radiographs, 3-dimensional images in all the planes i.e. MPR images and low equipment cost thus makes the CBCT possibly one of the ideal imaging modality for evaluating the lesions with respect to their exact extent and size for pre-operative evaluation of the lesion as described in our case. Treatment consists of surgical excision, including the curettage and freshening of the periosteum as well as the raw bone and scaling of adjacent teeth with bone coverage by mucosal flaps from the adjacent accessible tissue. Close postoperative follow-up is required because of the growth potential of incompletely removed lesions and the 8%–20% recurrence rate.

Acknowledgements

We are thankful to **Dr. Pankaj J Banode**, **Mr. Pranay Gawai**, technical staff TIFAC (Technology Information, Forecasting Assessment & Counseling) CORE (Centre of Relevance & Excellence) in interventional radiology Department of Science and Technology, Acharya Vinoba Bhave Rural Hospital, Sawangi (Meghe), **DMIMSU**, Wardha, Maharashtra, India supported by Government of India.

References

- [1]. W-J Moon, S. Y Choi, EC Chung, KH Kwon and SW Chae. Peripheral ossifying fibroma in the oral cavity: CT and MR findings. *Dentomaxillofacial Radiology* 2007; 36: 180–182.
- [2]. Saito I, Ide F, Inoue M, et al. Periosteal ossifying fibroma of the palate. *J Periodontol* 1984; 55: 704–707.
- [3]. Terry Farquhar; Jennifer MacLellan, Heather Dymont, Ross D. Anderson. Peripheral Ossifying Fibroma: A Case Report. *JCDA* 2008; 74:9:809-812.
- [4]. Bhaskar SN, Jacoway JR. Peripheral fibroma and peripheral fibroma with calcification: report of 376 cases. *J Am Dent Assoc* 1966; 73(6):1312–20.
- [5]. Eversole LR, Rovin S. Reactive lesions of the gingiva. *J Oral Pathol* 1972; 1(1):30–8.
- [6]. Gardner DG. The peripheral odontogenic fibroma: an attempt at clarification. *Oral Surg Oral Med Oral Pathol* 1982; 54(1):40–8.
- [7]. Kumar SK, Ram S, Jorgensen MG, Shuler CF, Sedghizadeh PP. Multicentric peripheral ossifying fibroma. *J Oral Sci* 2006; 48(4):239–43.
- [8]. Zain RB, Fei YJ. Fibrous lesions of the gingiva: a histopathologic analysis of 204 cases. *Oral Surg Oral Med Oral Pathol* 1990; 70(4):466–70.
- [9]. Buchner A. Peripheral odontogenic fibroma. *J Cranio Max Fac Surg* 1989; 17: 134–138.
- [10]. Buchner A, Hansen LS. The histomorphologic spectrum of peripheral ossifying fibroma. *Oral Surg Oral Med Oral Pathol* 1987; 63(4):452–61.
- [11]. Kendrick F, Waggoner WF. Managing a peripheral ossifying fibroma. *J Dent Child* 1996; 63: 135–138.
- [12]. Poon CK, Kwan PC, Chao SY. Giant peripheral ossifying fibroma of the maxilla: report of a case. *J Oral Maxillofac Surg* 1995; 53: 695–698.
- [13]. Cuisia ZE, Brannon RB. Peripheral ossifying fibroma—a clinical evaluation of 134 pediatric cases. *Pediatr Dent* 2001; 23: 245–248.
- [14]. Sezer B, Koyuncu B, Unal T, Tekin U, Akay C, Gomel M, et al. Peripheral ossifying fibroma: clinical and histologic evaluation of 98 cases. *J Appl Res Clin Dent* 2004; 1: 12–16.