

## **Antral inflammatory polyp causing intermittent gastric outlet obstruction: Case report**

Dr. G.Vandana, Dr. S.Lokesh , Dr. B. Kavita Devi, Dr S.Sandhya. Anil &  
Dr. H. Sandhya Rani

---

**Abstract:** We report a case of a 45-year-old woman who presented with vomiting & severe fatigue. On routine examination show iron deficiency anemia. Gastroscopy revealed a large polyp in the antral region causing intermittent gastric outlet obstruction. Histopathologic examination revealed an inflammatory fibroid polyp (known also as Vanek's tumour).<sup>1</sup>

**Background:** Gastric polyps are usually found incidentally on upper gastrointestinal endoscopy performed for an unrelated indication and only in rare cases do they cause symptoms. Nevertheless, the diagnosis and appropriate management of gastric polyps are important, as some polyps have malignant potential.

In 1949, Vanek described inflammatory fibroid polyp as "gastric submucosal granuloma with eosinophilic infiltration."<sup>2</sup> These polyps are characterized by the proliferation of spindle cells, small blood vessels, and inflammatory cells, often dominated by eosinophils.<sup>3</sup>

These uncommon polyps of unknown etiology may be found throughout the gastrointestinal tract, but they are most common in the antropyloric region (80%). They are diagnosed in male and female adults of all ages and are associated in some cases with hypochlorhydria or achlorhydria.<sup>4,5</sup>

Gastric outlet obstruction (GOO) presents with nausea and vomiting and usually develops over weeks to months.<sup>6</sup> It may be complete or incomplete with intermittent symptoms. In the past, peptic ulcer disease was considered as the most common cause of GOO; more recently, gastric malignancy has become a more frequent entity.<sup>7</sup> The rare causes are bezoars, foreign bodies, Bouveret's syndrome, hypertrophic pyloric stenosis, and large polyps of the antrum or pyloric channel.<sup>8,9,10,11</sup>

Inflammatory fibroid polyps are extremely rare lesions that represent less than 0.1 percent of all gastric polyps. Following resection, inflammatory fibroid polyps typically do not recur, and surveillance is not recommended.

**Keywords:** gastric outlet obstruction; pyloric channel; inflammatory fibroid polyp; polypectomy.

---

### **I. Case Presentation**

A 45 years old woman was admitted to MGM hospital, Warangal due to severe fatigue, intermittent nausea and vomiting. Her hemoglobin was 6.5 gm/dl, MCV: 60 and serum iron level: 34 (low); iron binding capacity: 452 (high). All of aforementioned laboratory results indicated that the patient was suffering from iron deficiency anemia. In upper endoscopy, pyloric canal partially obstructed by a smooth surfaced pedunculated structure traversing the pyloric canal might be a stalk of a polyp. Upon dragging the polyp with a controlled force, the clinicians were able to bring the polyp back to stomach. It was a pedunculated large antral polyp with a small area eroded on it, which was a possible explanation for blood loss. The polypectomy was performed successfully in toto.

The gross appearance (Figure a) and microscopic examination (Figure b,c,d) revealed a large inflammatory fibroid polyp with no malignant component in any part. The patient who was regarded cured is under periodic endoscopic follow up. Clinically patient was given two bags of blood and later continued with iron supplementation therapy as a part of her treatment. Now, the patient is quite well with hemoglobin level of 11.5 gm/dl and has no signs of gastric outlet obstruction, freely consumes a normal diet.

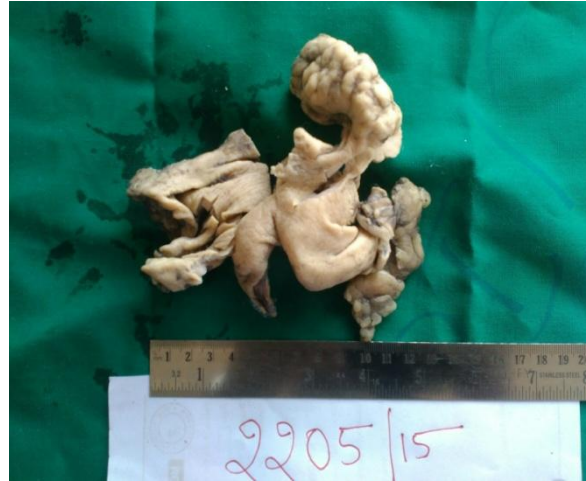

Fig a: Gross

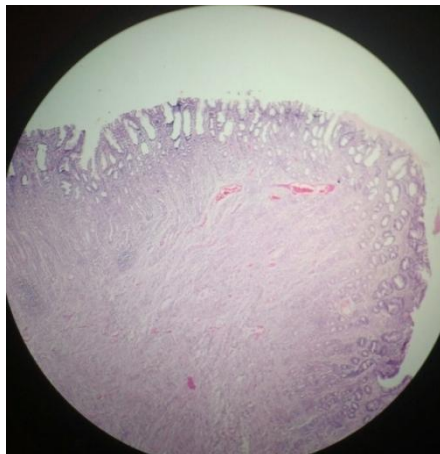


Fig: b 4x

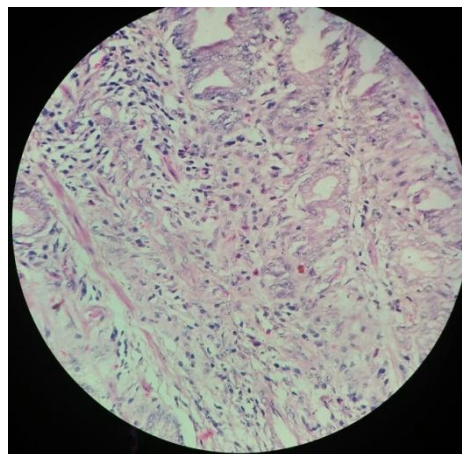


Fig :c 10x

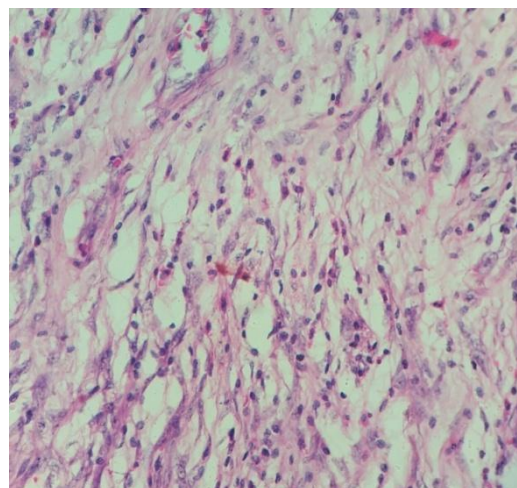


Fig:d 40x

## II. Discussion

Although familial clustering of inflammatory fibroid polyps has been reported, the etiology of inflammatory fibroid polyps is largely unknown.<sup>12</sup>

Most inflammatory fibroid polyps are asymptomatic, but larger polyps have been reported to cause abdominal pain, early satiety, anemia, and gastric outlet obstruction. On endoscopy, inflammatory fibroid polyps are usually firm, solitary, sessile or pedunculated, and often ulcerated. On endoscopic ultrasound, they

have the appearance of a hypoechoic homogeneous lesion with an indistinct margin, located within the second or third layer with an intact fourth layer.

On histology, these polyps are characterized by submucosal proliferations of spindle cells with vessels surrounded by a characteristic circumferential deposition of fibroblasts giving it an onion skin appearance, and an inflammatory infiltrate with a predominance of eosinophils.

Inflammatory fibroid polyps have been considered reactive and non-neoplastic. However, in one study of 23 inflammatory fibroid polyps, 70 percent were found to have gain-of-function mutations in the platelet-derived growth factor receptor alpha polypeptide gene, similar to those found in CD117-negative GI stromal tumors, suggesting the possibility of a neoplastic process.<sup>13</sup>

Following resection, inflammatory fibroid polyps typically do not recur, and surveillance is not recommended.

### III. Conclusion

All symptomatic gastric polyps presenting as the case above should be removed preferentially when they are detected at the initial diagnostic endoscopy. Polypectomy not only provides tissue to determine the exact histopathologic type of the polyp, but also achieves radical treatment. The same strategy can be used for asymptomatic polyps, because biopsy samples may yield inconclusive results by sampling error. Evidence now is in favour of polypectomy. Additionally, in patients with gastric polyps, other parts of the gastric mucosa should also be histologically evaluated by multiple biopsies for detection of any accompanying inflammatory changes or malignancy. After polypectomy, endoscopic follow-up can be recommended, because of the possibility of recurrence at the polypectomy site and of development of malignancy in the remote gastric mucosa.

### References:

- [1]. Vanek J: Gastric submucosal granuloma with eosinophilic infiltration. *Am J Pathol* 1949;25:397–411.
- [2]. Vanek J: Gastric submucosal granuloma with eosinophilic infiltration. *Am J Pathol*. 1949;25:405.
- [3]. Lewin KJ, Appelman HD. Mesenchymal tumors and tumor-like proliferation. In: Rosai J, Sobin LH, eds. *Tumors of the Esophagus and Stomach*. Washington, DC: Armed Forces Institute of Pathology; 1996:449–453. *Atlas of Tumor Pathology*; 3rd series, fascicle 18
- [4]. Kolodziejczyk P, Yao T, Tsuneyoshi M. Inflammatory fibroid polyp of the stomach: a special reference to an immunohistochemical profile of 42 cases. *Am J Surg Pathol*. 1993;17:1159–1168.
- [5]. Hasegawa T, Yang P, Kagawa N, Hirose T, Sano T. CD34 expression by inflammatory fibroid polyps of the stomach. *Mod Pathol*. 1997;10:451–456.
- [6]. Livingston EH. Stomach and duodenum. In: Norton JA, Bollinger RR, Chang AE, Lowry SF, Mulvihill SJ, Pass HI, Thompson RW, editor. *In Surgery: Basic Science and Clinical Evidence*. New York: Springer-Verlag; 2000. pp. 489–515
- [7]. Jaffin BW, Kaye MD. The prognosis of gastric outlet obstruction. *Ann Surg*. 1985;201:176–179. [[PMC free article](#)] [[PubMed](#)]
- [8]. Malvaux P, Degolla R, De Saint-Hubert M, Farchakh E, Hauters P. Laparoscopic treatment of a gastric outlet obstruction caused by a gallstone (Bouveret's syndrome) *Surg Endosc*. 2002;16:1108–1109. doi: 10.1007/s004640042033. [[PubMed](#)] [[Cross Ref](#)]
- [9]. Gencosmanoglu R, Sad O, Sav A, Tozun N. Primary hypertrophic pyloric stenosis in the adult: a case report. *Turkish J Gastroenterol*. 2002;13:175–179. [[PubMed](#)]
- [10]. Dean PG, Davis PM, Nascimento AG, Farley DR. Hyperplastic gastric polyp causing progressive gastric outlet obstruction. *Mayo Clin Proc*. 1998;73:964–967. [[PubMed](#)]
- [11]. Alper M, Akcan Y, Belenli O. Large pedunculated antral hyperplastic gastric polyp traversed the bulbous causing outlet obstruction and iron deficiency anemia: endoscopic removal. *World J Gastroenterol*. 2003;9:633–634. [[PMC free article](#)] [[PubMed](#)]
- [12]. Alibone RO, Nanson JK, Anthony PP. Multiple & Recurrent inflammatory fibroid polyps in a Devon family (“Devon polyposis syndrome”): an update *Gut* 1992; 33 : 1004.
- [13]. Schildhaus HU, Cavlar T, Binot E, et al. Inflammatory fibroid polyps harbour mutations in the platelet-derived growth factor receptor alpha (PDGFRA) gene. *J Pathol* 2008; 216:176.