

## Spectrum of Haemangioma in Orthopedics: A Case Report

Frank H.C.<sup>1</sup>, Bhattacharyya T.D.<sup>2</sup>, Islam M<sup>3</sup>, Baruah S.<sup>4</sup>, Hazarika K.<sup>5</sup>, Mittal S.<sup>6</sup>  
(<sup>1,2,3,4,5,6</sup>Department of Orthopedics, Gauhati Medical college and hospital, India)

**Abstract:** A hemangioma is an abnormal proliferation of blood vessels that may occur in any vascularized tissue. Considerable debate exists as to whether these lesions are neoplasms, hamartomas, or vascular malformations. Skeletal muscle is the most common site for hemangioma of the deep soft tissue. Hemangioma of bone may be symptomatic or may be purely an incidental finding. We hereby present 3 cases of hemangioma occurring at different locations confirming the wide spectrum of hemangioma in orthopedics.

**Keywords:** Angiomatosis, Haemangioma: cavernous, capillary, epithelioid

### I. Introduction

Haemangioma is a relatively rare tumor encountered in orthopedic practice. These are lesions characterized by vascular spaces lined with endothelial cells. There are many types of hemangiomas, and they can occur throughout the body, including skin, muscle, bone, and internal organs. Multiple variants of haemangiomas are reported, depending on variable histological features<sup>(1)</sup>. It is suggested that hemangiomas are congenital or developmental disorders, although the etiology remains unknown. Hemangiomas are usually asymptomatic, and thus most are never discovered, leading some to describe these lesions as "rare". Actually, hemangiomas are common lesions with approximately 10% of autopsy cases having vertebral hemangiomas in one study. The peak incidence is in the fifth decade. Approximately 50% of osseous hemangiomas are found in the vertebral bodies (thoracic especially) and 20% are located in the calvarium. The remaining lesions are found in the tibia, femur and humerus<sup>(2)</sup>. They are usually incidentally detected on imaging done for other reasons. Collapse of the vertebral body or encroachment into the neural canal are some of the classic causes of pain. Any increase in activity can cause the vertebral haemangioma to become painful, such as extensive physical exercise, sporting activities etc. Intramuscular hemangiomas are rare benign tumors, making up 0.8% of all hemangiomas<sup>(3)</sup>. They are of interest to the surgeon because their location may present considerable therapeutic challenge since radiographic work-up of the soft-tissue mass by magnetic resonance imaging (MRI) may be suspicious for malignancy. The definitive diagnosis is made by histological study of the surgical and/or biopsy specimen.

True synovial-based hemangiomas again are uncommon lesions and, as such, may enter the differential diagnosis of other lesions encountered more frequently in clinical practice, including pigmented villonodular synovitis and traumatic hemarthrosis. It most commonly occurs in the knee joint but can occur at other sites like elbow, ankle, temporomandibular joint and tendon sheath<sup>(4)</sup>.

We hereby present 3 cases of hemangioma at different locations attending orthopedics OPD at our hospital and subsequently getting operated.

### II. Case Summary

#### CASE 1

A 12 year male attended the emergency of our institute with fracture shaft femur. It had occurred following self fall while playing football. There was no history of fever, sinus, swelling, pigmentation, prior injury to the same limb. However, patient had complaints of mild pain in the thigh for the past 1 year. In the emergency, X-rays were done and they revealed pathological fracture of shaft femur. Initially it was suspected to be fibrous dysplasia in X-ray. There was no compounding and distal neurovascular status was intact. Other bones were normal in skeletal survey. All hematological investigations including calcium, phosphorus, ALKP and peripheral blood smear were normal. The affected limb was immobilized in a Thomas splint and was planned for internal fixation. Follow up x-rays revealed union.

Intraoperatively, abnormal bleeding from the bone at drill hole sites was noted. The soft tissues of the thigh were however intact. The fracture was fixed with a locking compression plate after taking samples for biopsy and the patient was kept on non weight bearing. The biopsy

report came out to be hemangioma of bone. The patient was later discharged and kept on regular follow up. X-rays at 2 months show early callus formation.

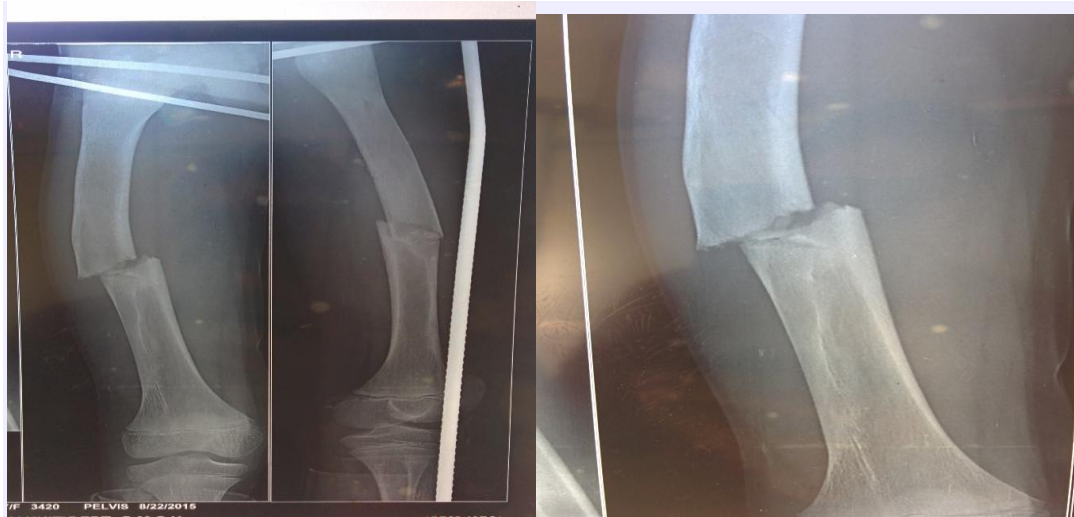

Fig 1. Xrays showing pathological fracture shaft of femur in a 12 year old boy at the time of presentation in emergency department.

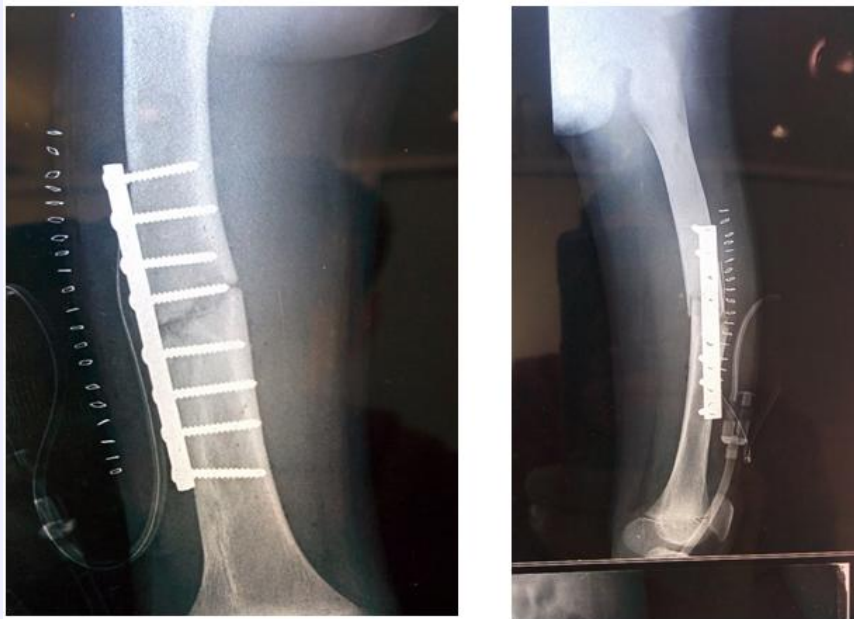


Fig 2. Immediate post op Xrays showing internal fixation done using Locking Compression plate.

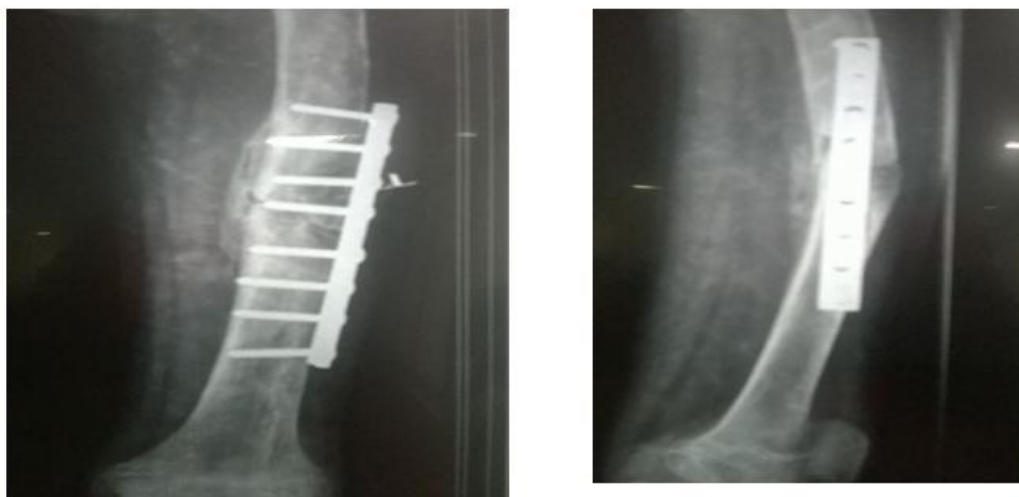


Fig 3. 2 months follow up xray showing early callus formation

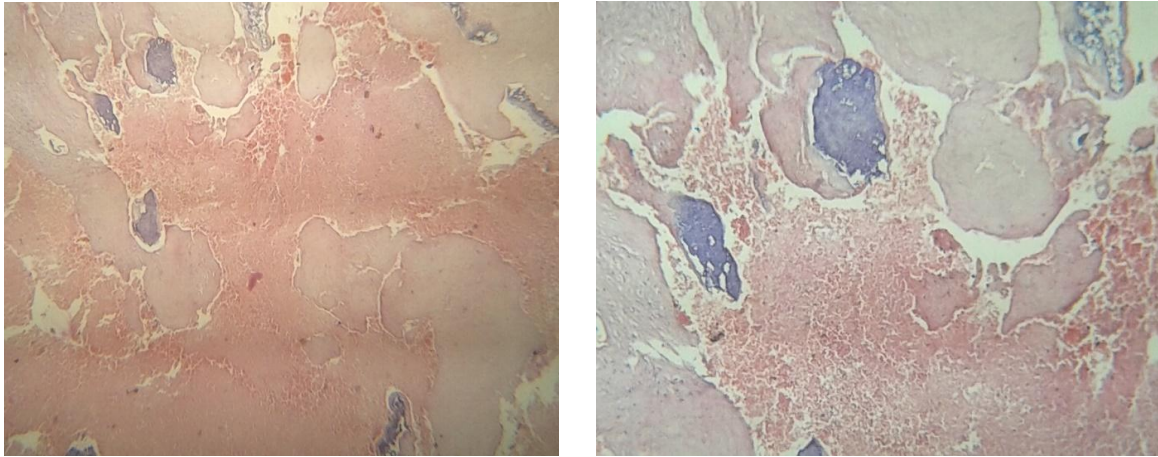


Fig 4. Histological picture showing hemangioma of bone.

**CASE 2**

A 12 year male attended the OPD, Orthopedics GMCH with a swelling in the left knee joint. He had a insignificant history of trauma to the joint 3 years back. Then the swelling gradually increased in size. It was not painful at any stage. Xrays and blood picture were normal. Culture sensitivity report was inconclusive.

An MRI of the joint was subsequently done and was reported to be hemangioma of the synovium. Attempted FNAC provided only a blood aspirate. The lesion was excised maintaining proper hemostasis and the excised specimen was reported to be hemangioma on HPE. The patient did not have any recurrence of swelling. The joint motion was full and painless on follow up.

Fig 1. Histological picture showing hemangioma of synovium

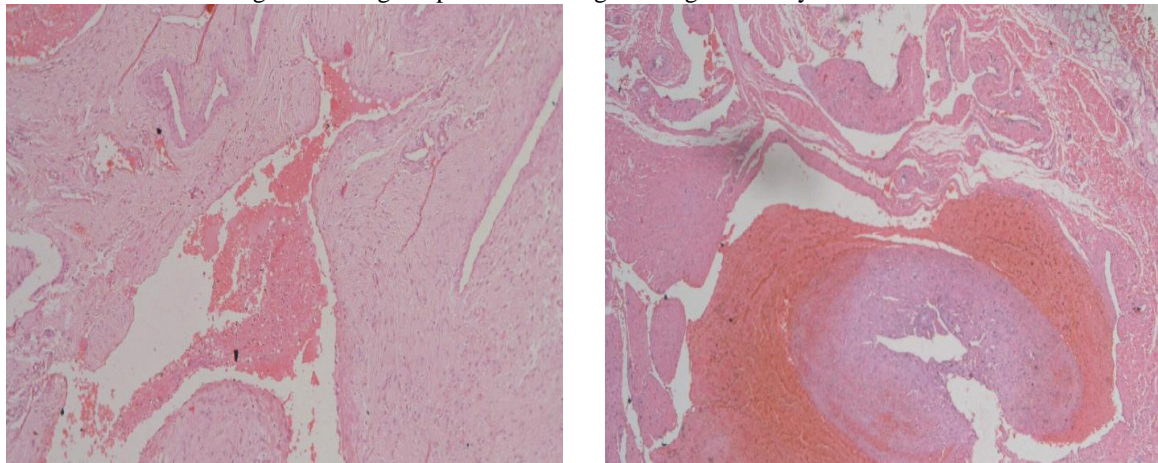


Fig 2. MRI images of the knee joint showing hemangioma

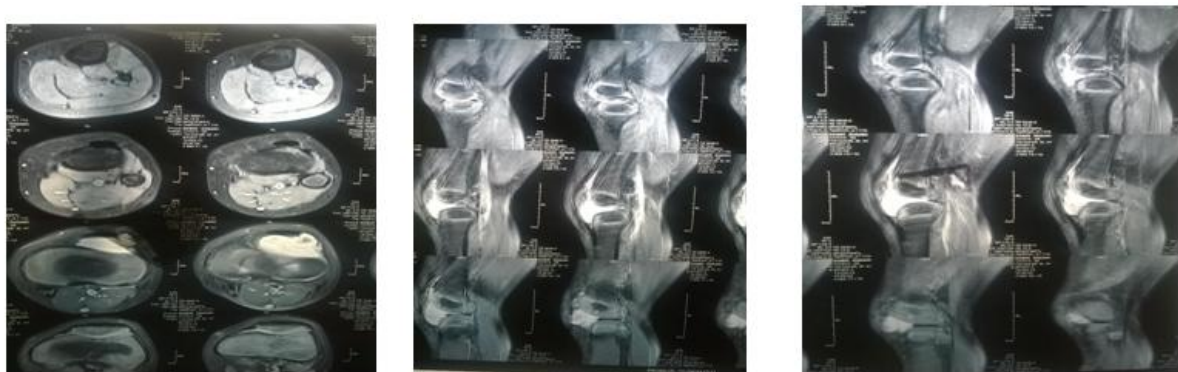
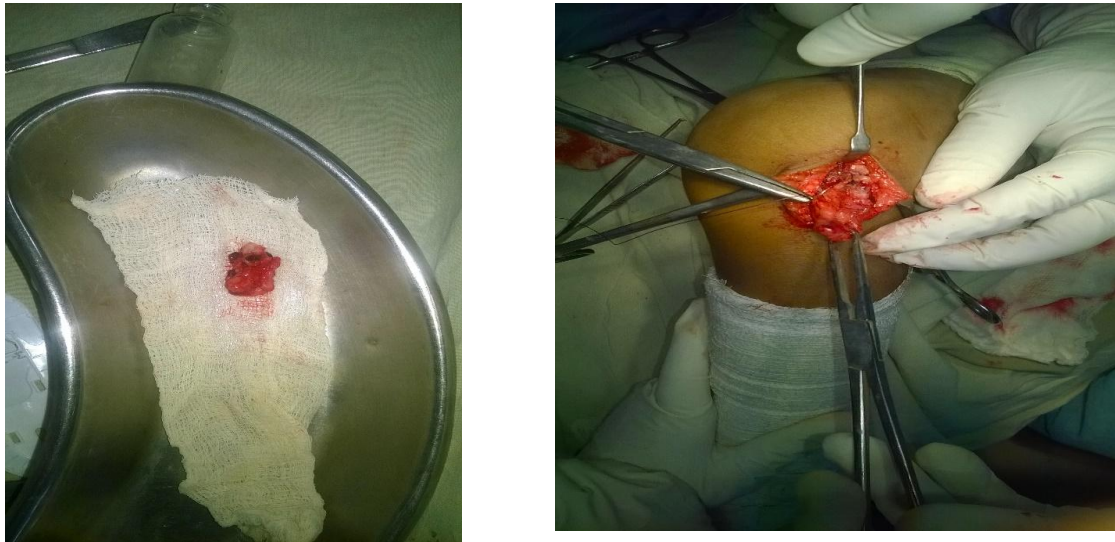




Fig 3. Intra operative picture showing the excised tissue



**ASE 3**

A 16 years female attended the OPD of GMCH with a swelling in the right arm on the medial aspect for the last 3 – 4 years. It was significantly palpable for the last 1 year. There was no history of trauma, pain, discharge, fever, earlier surgical procedures or similar swelling in any other part of the body. All routine blood investigations were normal. MRI of the swelling was done which reported a suspicion of hemangioma of biceps muscle. Excision of the lesion was planned in consultation with CTVS. Excision revealed a fusiform swelling of size 8 x 3 cm which was sent for HPE. Biopsy reports revealed a hemangioma of biceps muscle. The patient was followed up subsequently and had no recurrence of the swelling.

Fig 1. Picture showing swelling in the right arm

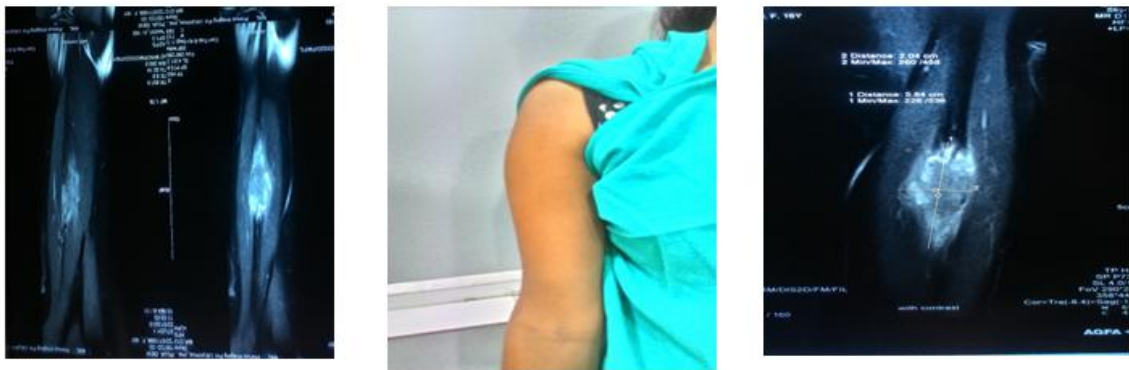

Fig 2. MRI showing suspicious hemangioma of the biceps

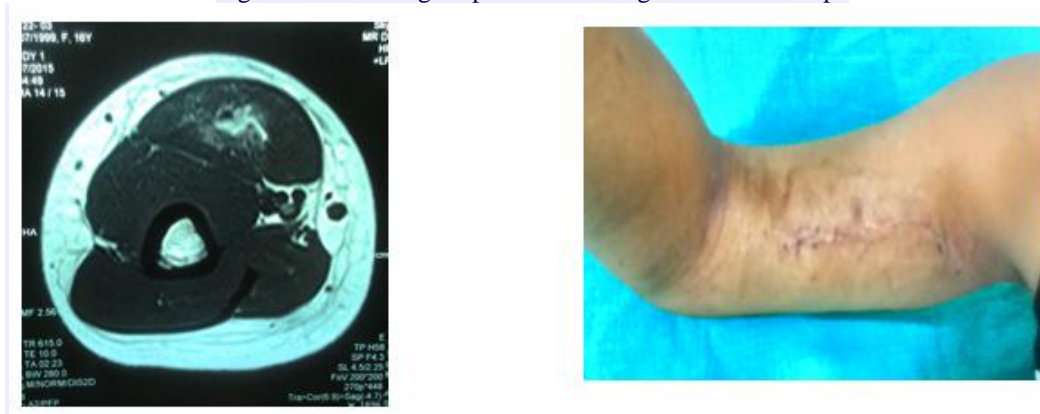

Fig 3. Picture showing the excised biceps tissue and the postoperative wound at follow up

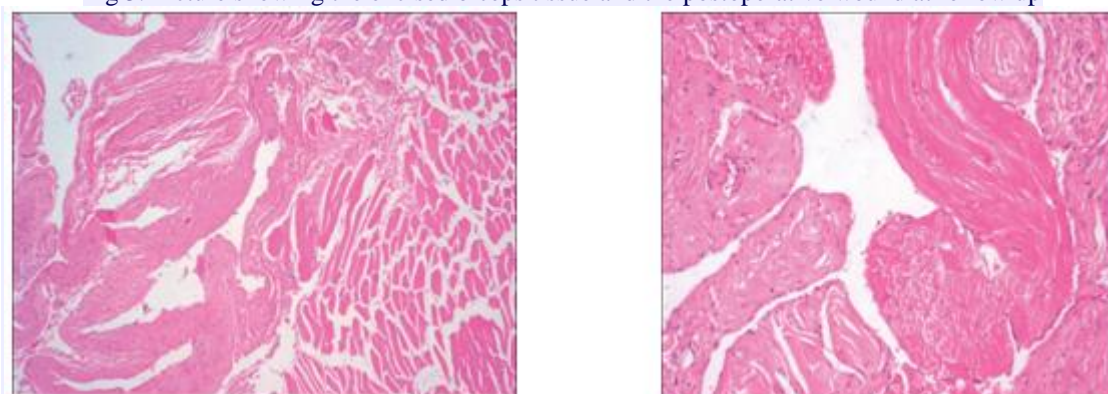
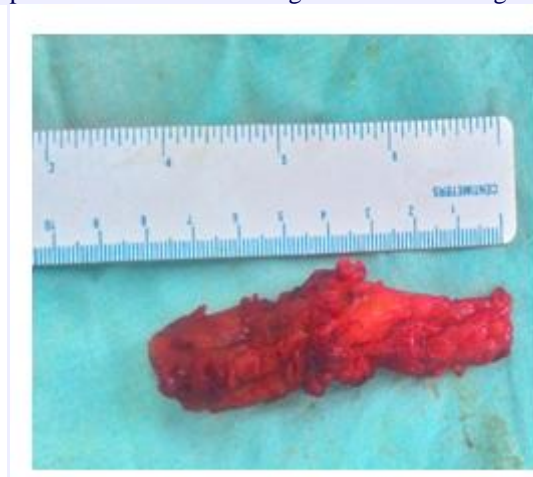

Fig 4. Histological pictures confirmed the diagnosis to be hemangioma of biceps muscle.



### III. Discussion

Hemangiomas are benign, nonreactive process in which there is an increase in the number of normal or abnormal-appearing vessels, recognizing that many of these lesions represent tissue malformations rather than true tumors. Hemangiomas are one of the most common soft tissue tumors and account 7% of all benign tumors. It is the most common soft tissue tumor during infancy and childhood. Most hemangiomas are superficial lesions that have a predilection for the head and neck area but may also occur in organs such as liver. Hemangiomas affecting the bone are relatively rare, accounting for only 1% of all bone tumors. They account for a majority of primary, benign, vascular neoplasms involving the spine. Hemangiomas affecting bone can be medullary, intracortical, or periosteal based. Synovial cavernous hemangioma is a rare entity that can arise from any synovium lined surface and therefore may be found along the course of tendons or in joint space . It often presents as a painless soft tissue swelling. Intraarticular cavernous hemangiomas are rare and almost always involve knee joint. It causes recurrent episodes of pain, swelling and joint effusion. Symptoms usually begin in childhood and persist several years before the time of diagnosis. In most cases a spongy compressible mass that decrease in size by elevation over the joint . Plain films are non-specific to some soft tissue density and capsular thickening in some cases. Arteriography is more diagnostic in showing blood pool over the mass but it is a painful and invasive procedure. Recently MRI has been a great help in diagnosing these lesions. The lesion can be either pedunculated or as a diffuse process.

Histologically, the tumors are cavernous hemangiomas in which the vessels are separated by an edematous, myxoid or focally hyalinized matrix occasionally containing inflammatory cells and siderophages. There is no general agreement concerning the pathogenesis of these lesions. It has been suggested that those lesions are not neoplasms but represent a reaction to trauma although such a history is given in only a small number of cases. On the other hand, the young age of onset raises the question as whether these lesions are congenital malformations or tumors. Treatment of local or pedunculated lesions is a simple surgical resection. This can be performed either by open arthrotomy or arthroscopic methods. The treatment of more diffuse lesions is much more difficult and might need some adjuvant radiation therapy to prevent recurrences.

**References**

- [1]. [atlasgeneticsoncology.org/Tumors/HaemangiomaBoneID5358.html](http://atlasgeneticsoncology.org/Tumors/HaemangiomaBoneID5358.html)
- [2]. [www.bonetumor.org/tumors-bone/hemangioma](http://www.bonetumor.org/tumors-bone/hemangioma)
- [3]. A. T. Wild, P. Raab, R. Krauspe, Hemangioma of skeletal muscle. Archives of Orthopaedic and Trauma Surgery February 2000, Volume 120, Issue 3, pp 139-143
- [4]. A. Cotten., R. -M. Flipo, B. Herbaux, F. Gougeon, M. Lecomte-Houcke, P. Chastanet, Synovial haemangioma of the knee: a frequently misdiagnosed lesion. Skeletal Radiology, May 1995, Volume 24, Issue 4, pp 257-261.