

Role of 3D CT in Evaluation of Tibial Plateau Fractures

Dr.Lakshmi Manjula,¹ Dr V. Venkataratnam²

PES Institute of Medical Science and Research, Kuppam, Andhra Pradesh

1)Final Year Resident . 2)Professor of Radiodiagnosis.

Abstract

Objective: Our purpose was to determine the value of 3D dimensional CT in tibial plateau fractures of knee for characterization and to know the amount of displacement of fracture fragments for preoperative evaluation and surgical planning. This article shows the advantage of 3DCT over radiography and conventional CT in evaluation of plateau fractures.

Materials And Methods: Thirty patients of knee trauma underwent CT with 3 dimensional CT reconstruction. The type of fractures and displacements are evaluated in all cases.

RESULTS: out of thirty patients of knee trauma twenty patients had fractures of tibial plateau and they are classified according to schatzkers classification and rest showed fractures of other bones around knee.

Conclusion: Among knee fractures Tibial plateau fractures are more common. Even though Radiography can detect fractures around 80% of cases it cannot detect subtle fractures (because of patient position in acute trauma) and depression of fracture fragments, displacement of fragments, intra articular fragments. Which helps in pre operative planning. These can be accurately evaluated by 3 dimensional CT scan. MDCT is a fast and accurate examination and is recommended in patients with complex knee injuries in order to evaluate the fractures adequately.

I. Introduction:

The knee joint is complex joint and is the commonly injured joint now a days because of increased traffic accident, and sports related injuries a simple fall, or a twisting injury. Being superficial joint and more exposed to external forces, this joint easily gets injured. Fractures around the knee in adults account for only 2% of all the fracture. Fractures around the knee are often complex injuries that present to the surgeon with numerous potential complications.

Radiography can detect fracture comminution of fracture fragments and displacement of tibial plateau fractures to certain extent.

MDCT allows thin slices with near isotropic voxels in every plane, and these are suitable for two-dimensional (2D) reformats and three-dimensional (3D) rendering. With new software and workstations, fast image processing is possible even in the emergency-room setting. MDCT allows imaging through splints and casts without decrease in image quality, and positioning of the knee is not as crucial as for radiography.

The well-known disadvantage of MDCT is radiation. The average effective dose for a peripheral joint such as the knee is 1mSv, and can be considered as a low-dose examination. With new-generation scanners, the radiation dose is further decreasing. Another disadvantage is its inability to detect ligaments and meniscal injuries.

Recent advances in computerized tomography have reduced data acquisition and reconstruction times so that three-dimensional CT images of knee injuries may be economically and quickly generated. 3DCT was judged superior to multiplanar two-dimensional CT in demonstrating the spatial relationships of fracture fragments in complex and mid knee trauma. 3D CT enables a clear perception of extent of major fracture line and resulting displacement of fragments. So this new modality permits preoperative analysis and surgical planning as compared to other conventional radiography for treatment of knee fractures.

II. Materials And Methods

Source of data:

All cases with fractures in and around knee joint referred to the department of radiodiagnosis, PES IMSR Kuppam. During period of 2014-2015

Mechanism of Injury:

Injuries to the plateaus occur as a result of :

1. Force directed either medially (valgus deformity, the classic bumper fracture) or laterally (varus deformity)

Equipment

- 500 Ma SeimansKlinoskop–H Xray Machine.
- Ge Bright Speed Elite 16 Slice Ct Scanner

2. Axial compressive force. 3. Both an axial force and a force from the side

Radiography ;Radiography was performed with a computed radiography unit SIEMENS 500 mA X RAY MACHINE. Radiography was done in the standard AP and lateral views with 57kvp and 5mas .All patients with complex knee injuries and with high clinical suspicion of knee fractures are subjected to 3DCT.

MDCT Knee with 3D reconstruction:The MDCT images were obtained with a 16 slice multi-detector scanner (BrightSpeed; GE Medical Systems,). The routine knee MDCT examination protocol was performed as follows : MDCT scanning taken from the upper pole of the patella to caudal fibular head usingmAs-135 kV-120 Approximate total exposureTime8.3sec. Slice thickness of 2.5 mm with Reconstruction increment of 0.625 mm Helical scan with -Large FOV Images are displayed in Standard and bone reconstructions coronal and sagittal planes.

III. Observations And Results

Study design: A descriptive statistical analysis and evaluation of study group consisting of 30 patients with knee trauma is undertaken to study the spectrum of 3D CT findings.

Out of 30 patients studied mode of trauma is road and traffic accident in 90% of patients . plateau fractures are more common in male patients and in 21-30 years age group. Out of patients studied 20 patients showed tibialplateau fractures.

Type	Frequency	Percentage
I	1	3.3
II	6	20.0
III	0	0
IV	3	10.0
V	0	0
VI	10	33.3
Total	20	66.6

Among plateau fractures type IV fractures are more common in our study and they account for about 50% followed by type II fracture.

In our study Twentytibial plateau fractures were examined with plain film (anteroposterior, lateral,) and spiral CT with 3D reconstructions. The fractures were underestimated with plain film in 4cases (20%).

IV. Discussion

Tibial plateau fractures presents as isolated injury or part of poly trauma and are clinically important as the disruption of soft tissues and bones and if not detected accurately, can have severe sequelae.

Radiography in AP and lateral views is the basis for primary evaluation of the knee injury. Conventional radiography is quick, widely available, and quite economical. The obtaining of additional views has been supported by several authors. In severely injured patients, however, additional views are demanding or sometimes even impossible to obtain. Partly because of this difficulty, the next-step study in the evaluation of the knee trauma at many hospitals nowadays is MDCT.

MDCT scanners produce images of good quality almost in seconds and are therefore suitable for acute trauma cases. These scanners yield isotropic voxels enabling reformats in any plane and also 3D reformats . Scanning through casts and splints is also possible without impairing image quality.

□ **Classification of Tibial Plateau Fracture:** Over the years, many classifications for the tibial plateau fractures have been developed. All classifications are based on fracture location and degree of displacement. The fractures are classified according the Schatzker classification system. It divides tibial plateau fractures into six types.

□ Classification of Tibial Plateau Fractures is widely used by orthopedic surgeons to assess the initial injury, plan management, and predict prognosis.

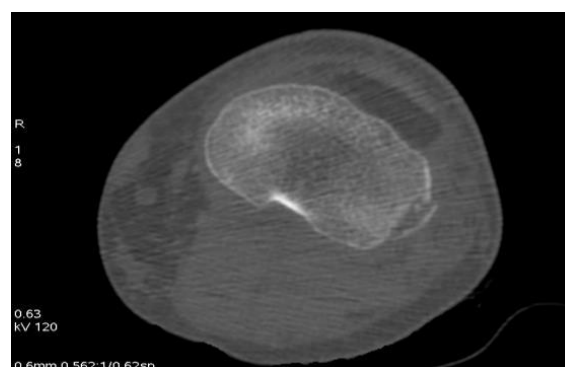
A type I fracture is a wedge-shaped pure cleavage fracture of the lateral tibial plateau, with a displacement or depression less than 4mm. They are caused by the lateral femoral condyle being driven into the articular surface of the tibial plateau.(fig1)

- Type II is a fracture with a combined cleavage and compression of the lateral tibial plateau, a type I fracture with a depressed component. There is a depression greater than 4mm.
 - A Schatzker type III fracture is a pure compression fracture of the lateral tibial plateau in which the articular surface of the tibial plateau is depressed and driven into the lateral tibial metaphysis by axial forces. Type III fractures are divided into two subgroups: those with lateral depression (type IIIA) and those with central depression (type IIIB).
 - Type IV is a medial tibial plateau fracture with a split or depressed component. These fractures occur as a result of varus forces combined with axial loading in a hyperflexed knee. Type IV fractures have the worst prognosis.
 - Type V fracture consists of a wedge fracture of the medial and lateral tibial plateau, often with an inverted “Y” appearance. Articular depression is typically seen in the lateral plateau and might be associated with a fracture of the intercondylar eminence.
 - Type VI is a bicondylar fracture with a dislocation of the metaphysis from the diaphysis. This pattern results from high-energy trauma and diverse combinations of forces. (fig2)
- The first three types are mostly the result of low energy injury, the three others of high energy injury. The magnitude of the force determined the degree of fragmentation and the degree of displacement. Tibial plateau fractures are often associated with anterior cruciate ligament, collateral ligaments (MCL and/or LCL), menisci and articular cartilage injury.

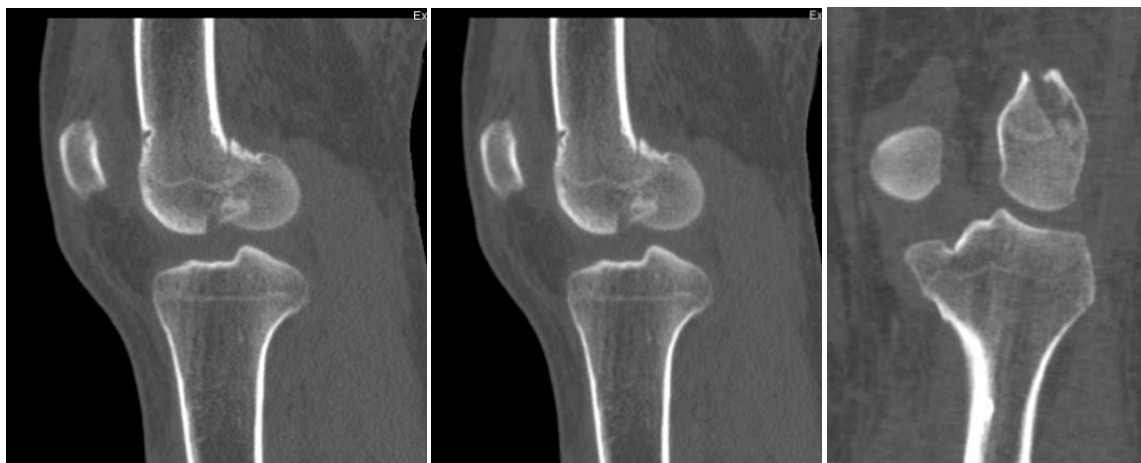In study by RajuskarPramodPralhad majority of fractures are schatzkers Type II.

In our study majority are Type VI fractures.

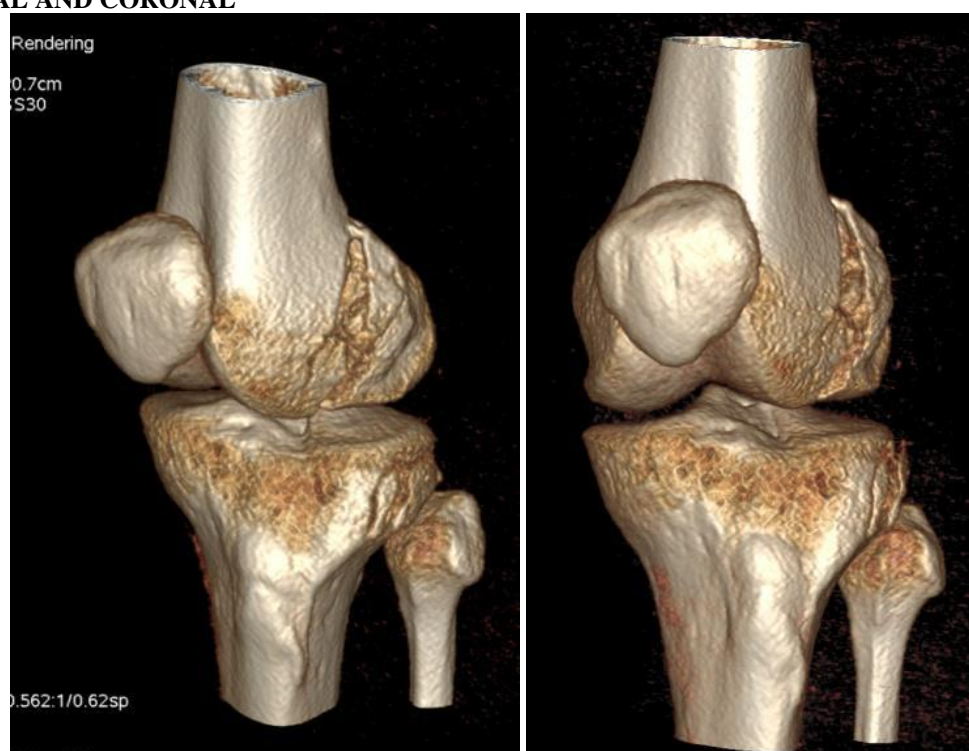
- In a study by DiassJ. J etal in Sixteen consecutive patients with tibial plateau fractures were investigated by standard radiography and computerised axial tomograms (CT scans). It was found that CT scanning proved most helpful for classifying the type of fracture, for evaluating the degree of comminution, and for measuring displacement.
- In a study byKeeganMarkhardt et al Schatzker classification system for tibial plateau fractures is widely used by orthopedic surgeons to assess the initial injury, plan management, and predict prognosis. Many investigators have found that surgical plans based on plain radiographic findings were modified after preoperative computed tomography (CT). CT image is more accurate than plain radiography for Schatzker classification of tibial plateau fractures, and use of cross-sectional imaging can improve surgical planning.
- Our study is done by studying fractures of knee by 3DCT evaluation and multi planar reconstruction of images . Using these reconstructed coronal images and sagittal images with VR images allowed us to make accurate, reproducible, and appropriate evaluations of proximal tibial fracture patterns and depressions.
- McEnery et al reviewed the value of spiral CT coronal plane reconstructions of image the sensitivity and specificity in distinguishing 5-mm fracture displacements 96% and 93%, respectively
- In our study by coronal reconstruction of knee images 5 to 6mm depression of tibialplateau fracture fragments was detected.
- In our study Twenty tibial plateau fractures were examined with plain film (anteroposterior, lateral,) and spiral CT with 3D reconstructions. The fractures were underestimated with plain film in 4 cases (20%) and can not characterize the type of fractures. In Our study is done by studying fractures of knee by 3DCT evaluation and multi planar reconstruction of images . Using these reconstructed coronal images and sagittal images with VR images allowed us to make accurate, reproducible, and appropriate evaluations of proximal tibial fracture pattern types and depressions. In our study by coronal reconstruction of knee images 5 to 6mm depression of tibialplateau fracture fragments was detected which were not accurately detected in plain radiographs.



AXIAL



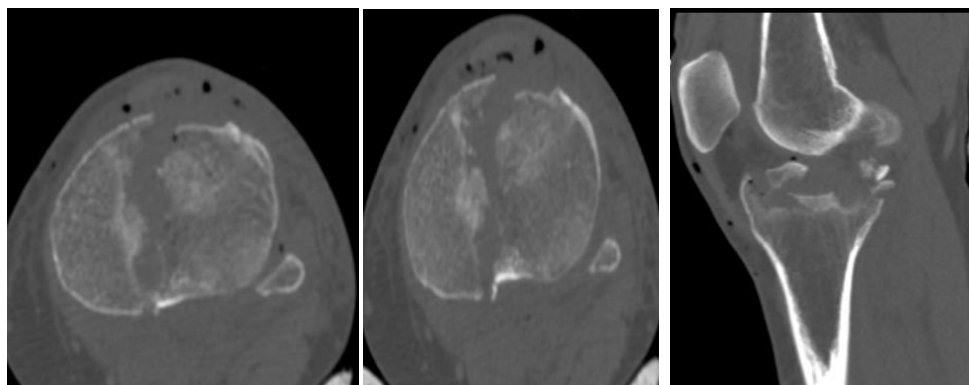
SAGITTAL AND CORONAL

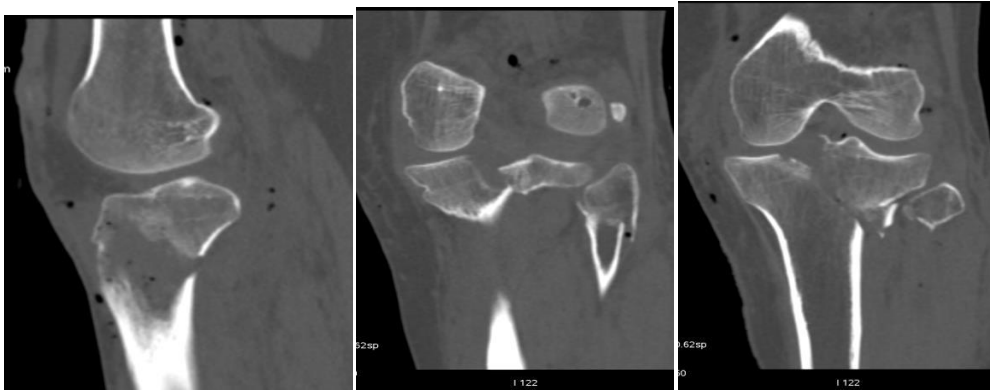

VR IMAGES

Fig 1: A male patient aged 23 with history of RTA showing fracture of lateral tibial condyle without depression (Schtzkers Type I) and lateral femoral condyle.

CASE:2





AXIAL&SAGITTAL,CORONAL

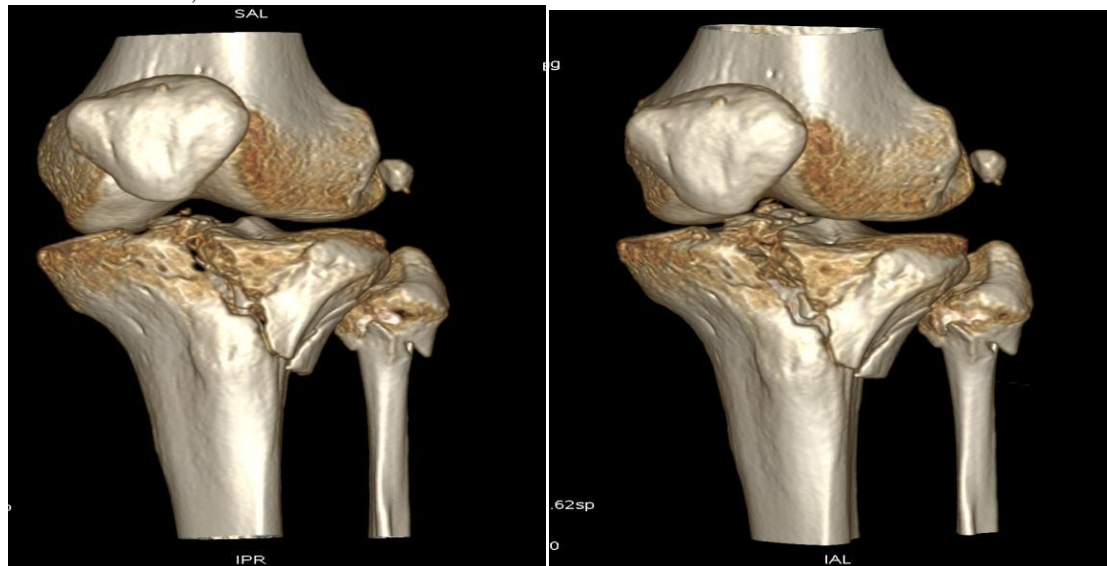


Fig 2: VRIMAGES

A female patient aged 50years with history of RTA showing comminuted fracture involving lateral tibialplateau extending to tibial eminence along proximal meta diaphyseal region .(Schatzker`sTypeVI)Fracture of fibular neck and head with Lipohaemarthrosis.

Limitations of study

□ 3D CT cannot evaluate meniscal and collateral and cruciate ligaments injuries and can only detect osseous pathology. Since it involves with ionizing radiation it cannot be used in pregnant patients. If there is motion on one or more slices, then final 3-D Imaging will be unsatisfactory regardless of rendering algorithm is used..

V. Conclusion

Among knee fractures Tibial plateau fractures are more common. Even though Radiography can detect fractures it cannot detect subtle fractures(because of patient position in acute trauma) and depression of fracture fragments ,displacement of fragments , intra articular fragments. These can be accurately evaluated by CT scan. MDCT is a fast and accurate examination and is recommended in patients with complex knee injuries in order to evaluate the fractures adequately.Continuing advances in computer software algorithms and improved precision in the acquisition of radiographic data will make 3D reformatted CT imaging a necessary complement to traditional 2D CT imaging in the management of complex knee trauma.

Most cases of musculo skeletal trauma require MPR or 3D Imaging. As there is no additional scanning or radiation involved in the reconstruction of images, 3D VR images and MPR is a valuable tool for the radiologist interpreting knee plateaufractures. MPR and 3D VR images help better evaluation of fractures detected on axial images. 3D reconstruction is useful to assess bony architecture in large comminuted, displaced, and complex fractures involving multiple planes. In the case of complex fractures, and allow an adequate visualization and easy interpretation of the fracture segments and, their relationship to one another. This is very helpful when deciding on the most suitable preoperative planning for each patient.

References

- [1]. Diass J. J, Stirling. A. J, Finlay DBL, Gregg P.JET,;Computerised axial tomography for tibial plateau fractures, J 1987 British Editorial Society of Bone and Joint Surgery
- [2]. McEney KW1, Wilson AJ, Pilgram TK, Murphy WA Jr, Marushack MM, Fractures of the tibial plateau: value of spiral CT coronal plane reconstructions for detection displacement in vitro.AJR Am J Roentgenol. 1994 Nov;163.
- [3]. Chan PS1, Klimkiewicz JJ, Luchetti WT, Esterhai JL, Kneeland JB, Dalinka MK, Heppenstall RB. Impact of CT scan on treatment plan and fracture classification of tibial plateau fractures.JOrthop Trauma. 1997 Oct;11(7):484-9
- [4]. Blaser PF1, Wicky S, Husmann O, Meuli RA, Leyvraz PFetal.21 Value of 3D CT in diagnosis and treatment of fractures of the tibial plateau.[Article in French]Swiss Surg. 1998;(4):180-6
- [5]. S.wickyP.F.Blaser,C.H.Blank,P .Flevvraj,P.schnyder, R.A.Meuli compared between standard radiography and spiral CT with 3D reconstruction in the evaluation, classificationand management of tibial plateau fractures. EuropeanRadiology.2000;10(8):1227-1232
- [6]. Markhardt, B. Keegan, Jonathan M. Gross, and Johnny Monu. "Schatzker Classification of Tibial Plateau Fractures: Use of CT and MR Imaging Improves Assessment 1." Radiographics29.2 (2009): 585-597..
- [7]. Dr.RajuskarPramodPralhad - Mch-Ortho"Assessment of different Modalities of treatment in fracture of TibialPlatue" Department of orthopedics Atharv medical Foundation &Research center, Maharashtra.
- [8]. XU Mei,LIU Jing wang,CHENG Ming fu.(Department of Radiology,123th Hospital of PLA,Anhui 233015,CThe application of spiral CT in examination of the knee with trauma fracture.
- [9]. ÖmerEtlik; OsmanTemizöz; AliDoğan; MustafaKayan; HalilArslan; UnalÖzkanThree-dimensional volume rendering imaging in detection of bone fractures31-Dec-2004European Journal of General Medicine (ISSN: 1304-3897) Vol 1 Num 4
- [10]. Antti O. Mustonen, Seppo K. Koskinen, Martti J. Kiuru: Acute knee trauma:Analysis of multidetector computed tomography findings and comparison toconventional radiography. ActaRadiol46:866–874, 2005
- [11]. B. Keegan Markhardt, MD, , Jonathan M. Gross, MD, , and Johnny Monu, MD, ¹From the Departments of Imaging Sciences (B.K.M., J.U.V.M.) and Orthopedic Surgery (J.M.G., J.U.V.M.), University of Rochester Medical Center, Strong Memorial Hospital, 601 Elmwood Ave, Box 648, Rochester, NY 14642-8648. Presented as an education exhibit at the 2007 RSNA Annual MeetinGSchatzker Classification of Tibial Plateau Fractures: Use of CT and MR Imaging Improves Assessment . March –april 2009
- [12]. Flohr, T. H., et al. "Image reconstruction and image quality evaluation for a 16-slice CT scanner." Medical physics 30.5 (2003): 832-845.