

## Endoscopic third ventriculostomy –our institute experience

Dr.B.Hayagreeva Rao<sup>1</sup>, Dr. K. Satyavara Prasad<sup>2</sup>, Dr. P.Krishna Rajiv<sup>3</sup>, Dr. P.Vijay Kumar<sup>4</sup>, Dr.T.Phaneswar<sup>3</sup>.

<sup>1</sup>(Associate Professor, Department of Neurosurgery, King George Hospital, Andhra Medical College, Visakhapatnam, Andhra Pradesh, India)

<sup>2</sup>( Professor, Department of Neurosurgery, King George Hospital, Andhra Medical College, Visakhapatnam, Andhra Pradesh, India)

<sup>3</sup>( Post Graduate, Department of Neurosurgery, King George Hospital, Andhra Medical College, Visakhapatnam, Andhra Pradesh, India)

<sup>3</sup>( Senior Resident, Department of Neurosurgery, King George Hospital, Andhra Medical College, Visakhapatnam, Andhra Pradesh, India)

---

**Abstract:** *The Introduction: With the advances in minimally invasive techniques in past decade, Endoscopic third ventriculostomy (ETV) has gained popularity and revolutionized the management of hydrocephalus with several advantages, thus became the treatment of choice of obstructive hydrocephalus and for certain selected cases of communicating hydrocephalus. The outcome of this treatment with regard to age, cause remains controversial.*

**Aim:** *to analyse the demographics and perioperative and post-operative complications and surgical outcome of ETV.*

**Materials and Methods:** *This is a retrospective study of 48 patients treated by ETV with various aetiologies in the department of neurosurgery, King George Hospital, Visakhapatnam, for a duration of 35 months from January 2012 to November 2015. The data was collected from the medical records and analysed. Patients less than 6 months of age and hydrocephalous due to intra ventricular haemorrhage, associated meningomyelocele and acute infectious aetiology were excluded from the study. Follow-up period ranged from one week to 35 months. Failure was defined by persistence or recurrence of symptoms and the need for installation of subsequent shunt device. The outcome results were analysed.*

**Results:** *the mean age of the patients in our study was 16.5+/-2.8 years of age with the range extending from 7months to 56 years with male predominance (male to female ratio was 2.2:1). Major indication for the ETV was aqueductal stenosis (56.25%). The success rate was 77.08%. Failure rate was in 22.91%. Commonest complication was CSF leak from burr-hole site.*

**Conclusion:** *ETV has success rate of 77.08% with various aetiologies. Patients below 2 years of age and shunt failure cases and post TB meningitis did not show statistical difference in outcome compared to aqueductal stenosis cases. Further studies with a large numbers of patients are warranted.*

**Keywords:** *Aqueductal Stenosis, Cerebro Spinal Fluid (CSF), Endoscope third ventriculostomy (ETV), Hydrocephalus, Outcome of ETV, Ventriculo-peritoneal shunt.*

---

### I. Introduction

The CSF flow diversion techniques are the treatment for hydrocephalus to alleviate the increased intracerebral pressure. Ventriculo Peritoneal (V P) shunt is the time honored procedure for the management of hydrocephalus. Endoscopic third ventriculostomy (ETV) has emerged as the procedure of choice in recent times for the management of obstructive hydrocephalus of various etiologies.<sup>[1-6]</sup> ETV is a minimally invasive and often a onetime procedure which allows the CSF to be internally diverted to the basal cisterns and eventually be reabsorbed by arachnoid granulations, evades the need to implant exogenous material like the shunt and its associated complications and lifelong harboring of a foreign material. With the advances in the technology and understanding of the flow dynamics, neuroendoscope usage has been extended for the management of broader pathologies like communicating hydrocephalous and shunt malfunction cases with good results, in selected cases.<sup>[7-9]</sup> Since the introduction of valve regulated shunt in 1952, a simple technique and reliable treatment with good results, made shunt the treatment of choice for the management of hydrocephalous for many decades. But, the concept of usage of endoscope in hydrocephalous dates back to early 1920's when Walter E. Dandy performed choroid plexectomy in communicating hydrocephalus at which time the term ventriculostomy was coined and hence Dandy is regarded as the father of neuroendoscopy.<sup>[10]</sup> It was William Mixter, an urologist, in 1923 performed first ETV using an ureteroscope.<sup>[8]</sup> Due to poor magnification and illumination of first generation neuroendoscope, ETV became difficult and unreliable and more so its era ended with the advent of shunt. Resurgence of ETV occurred in 1990's with advances in endoscopic technologies and the high rate of

shunt failure and complications over a period of decades, had prompted neurosurgeons to review this oldest treatment for hydrocephalus (ETV). Here, we present our institute experience of ETV in 48 cases over a period of 3 years.

## **II. Materials and methods**

This is a cross sectional retrospective descriptive study of 48 patients who underwent ETV for hydrocephalus and the associated problems in our institute for a duration of 35 months from January 2012 to November 2015. The data was collected from the medical records were analyzed. Patients less than 6 months of age and hydrocephalous due to intracranial hemorrhage, those associated with meningomyelocele and acute infectious etiology were excluded from the study. Patients between 6 months to 2 years of age were stratified from others to include etiology of congenital aqueductal stenosis only. Follow-up period ranged from one week to 35 months. All cases had signs and symptoms of raised intracranial pressure and radiographic evidence (CT/MRI) of hydrocephalus. Lateral and third ventricle dilatation with small fourth ventricle, a sign of obstruction at the level of the aqueduct of Sylvius, presence of CSF in basal cisterns and extension of floor of the third ventricle behind and below the dorsum sellae were the radiological selection criteria for ETV in non-communicating hydrocephalus as suggested by Hoffman et al. [11] Patients with dilated fourth ventricle suggesting outlet obstruction (pan ventricular obstruction) due to TB meningitis presenting in chronic stage (>4 weeks from the onset of symptoms and on ATT) are included, and the rest of patients with hydrocephalus secondary to intra ventricular hemorrhage or in early stage of infection and in association with meningomyelocele were excluded from our series.

With surgical consent patients were operated under general anesthesia using ventricular Storz operating 0° neuroendoscope (Fig.1). The patients were placed supine with the head elevated approximately 30° with head flexed (Fig.2). Burr hole placed on right Kocher's point or readjusted for the optimal trajectory into the third ventricle through foramen of Monro and into the interpeduncular cistern which are planned on preoperative mid sagittal MRI imaging. Using FREE HAND technique Trochar with a stylet was inserted followed by an endoscope into the lateral ventricle and using the land marks of thalamostriate vein and choroid plexus, Foramen of Monro was identified. Then the endoscope is further negotiated through the foramen into the third ventricle. Continuous irrigation is done with warm saline solution. The site of the stoma was planned in the midline midway between the mamillary bodies and infundibular recess. (Fig.3) The stoma was created using bipolar cautery probe, then dilated with a Fogarty balloon catheter of 6f/7f. Visualizing and fenestration the lilliquet membrane if present and thus establishing oscillating pulsatile CSF flow across the ostium in floor of third ventricle into the pre-pontine /interpeduncular cisterns and visualization of vigorously pulsating basilar artery is the end point of surgery. (Fig.4)

Post operatively, serial measurement of head circumference in pediatric age group below 2 years of age, improvement in signs and symptoms in others were taken as the parameters in the assessment of the clinical outcome. Radiologically, size of the ventricles were assessed postoperatively.

Outcome is termed as a Failure if there is persistence or worsening of symptoms of raised intracranial pressure (ICP) during postoperative period or resurgence of raised ICP symptoms after a period of normalcy in follow up. Radiologically (CT/MRI) effacement of cerebral gyri and sulci and/or periventricular oedema were taken as signs of ETV failure. Persistent ventriculomegaly alone was not considered as ETV failure as ventriculomegaly is known to persist following ETV in spite of clinical improvement. ETV Failure cases were treated with shunt placement. Patients after discharge are followed up clinically and radiologically once in a month for 6 months later on 6th monthly.

The information regarding patient demographical details, causes of hydrocephalus and complications of procedure and failure rates are analyzed statistically using Fishers exact test and compared with other similar studies

## **III. Results**

The Over the study period, 48 patients underwent ETV in our institute of which 33 cases were male (68.75%) and 15 were female (31.75%). The average age of the patient at the time of surgery was 16.5 years with a range of 7 months to 56 years (Table 1).maximum number of cases are between the age group less than 10 years.(Fig.6) The commonest etiology was aqueductal stenosis (21 cases- 56.25%), followed by shunt failure (16 cases-33.3%), post TB meningitis (chronic) cases (8 cases -16.6%), 2 cases of hydrocephalous associated with arachnoid cyst and I case of hydrocephalus with pineal gland tumor.(Fig.7) All cases had hydrocephalus at the time of ETV, except in 2 cases of shunt over drainage cases causing slit ventricle syndrome. All Shunt failure cases had primary etiology of aqueductal stenosis presented with shunt migration or obstruction in 10/16 cases, infection in 4/16 cases and slit ventricle syndrome with secondary failure of lumboperitoneal shunt. Patients diagnosed TB meningitis and on ATT for at least for one month.

The patients were followed up from one month to 35 months duration. Thirty seven patients showed overall clinical improvement projecting our success rate to be 77.08%. The success rates in each pathology constituted to be 80.95% (17/21) in aqueductal stenosis, 75% (12/16) in shunt failure cases, 62.5% (5/8) in post TB meningitis cases and 100% each in hydrocephalous associate with arachnoid cysts and pineal tumor. (Table 2) These results are compared with one another using Fisher's exact test with significance level at 0.05. The difference of success rates between aqueductal stenosis and shunt failure was not statistically significant (Fisher's exact test  $P=1$ ). Similarly between aqueductal stenosis and post Tb meningitis was also statistically insignificant (Fisher's exact test  $P=0.75$ ).

We divided the aqueductal stenosis patients into two groups: 8 patients were younger than 2 years of age, and 13 were older. The age group more than 2 years age had better success rate of 92.3%(12/13 cases) when compared to group less the 2 years being 62.5% (5/8 cases).But this difference was statistically insignificant (Fisher's exact test  $P=0.28$ ).

Overall complication rate was 29.1% (14/48 cases) of which CSF leak was the commonest 12.5% (6 cases). Failure rate was 22.9% (11/48 cases) with 3 cases of mortality and 8 cases of persistence or deterioration of symptoms leading to shunt placement.

Out of 48 cases, we encountered one case of intraoperative complication of torrential bleed and procedure was stopped and external ventricular drainage was instituted and the patient succumbed in the postoperative period. One case had severe hyperthermia and seizure in first postoperative day which lead to death. Of the three mortality cases in our series, the last one occurred at 7 months of follow up suddenly, cause of which was not known.

6 patients (12.5%) developed CSF leak from the burr hole. Leak stopped after placement of reinforcement skin sutures in 2 cases, but the rest (4 patients) had persistence of CSF leak leading to institution of CSF diversion procedure (shunt placement). Ventriculitis developed in 3 cases. They were treated with antibiotics and external ventricular drainage (2 cases) and latter a shunt procedure. One case had seizure in the early post-operative period, subsided with antiepileptic medication. Late complications (developed more than 1 month after ETV) was development of pseudomeningocele at the burr hole site 5 months after ETV and shunt procedure was done in this case. (Table 3)

During follow up, at 1month and at one year following ETV, the clinical and radiological outcome were assessed. Radiologically the reduction in ventricular size is assessed (Fig.5). After 1 month in 48 cases, clinical outcome was 75% (39/48) but radiologically was only 52.08% (25/38). Among cases with 1 year follow up of 43, clinical outcome was 74.41% (32/43) and radiologically 67.44% (29/43). (Table 4)

#### **IV. Discussion**

Ventriculo-peritoneal shunt is a well-known, time honoured surgical procedure in the management of hydrocephalus. But in long run it has own complications and failure. With the resurgence of endoscopy with advances in the technology and availability of sophisticated equipment, endoscopic third ventriculostomy is gaining its importance in recent era of minimally invasive approaches. ETV efficacy in obstructive hydrocephalus is well documented in many studies. Extension of its application in other aetiologies of hydrocephalus are evolving. Several endoscopists differ in opinion regarding the role of ETV in aetiologies of hydrocephalous other than aqueductal stenosis and usage below 2 years of age. We have included other causes of hydrocephalous, strictly confining to the pre-set highly selective inclusion criteria, excluding those hydrocephalus cases associated with meningomyelocole, acute infections and post haemorrhagic causes. Children with only aqueductal stenosis are included in children less than 2 years and above 6 months of age. This selection criteria was done to eliminate the factors suggested as causes of failure of ETV like infants below six months etc.<sup>[23]</sup>

In our study, the mean age of the patient at the time of ETV was 16.5 which is comparable with other studies,<sup>[12,13]</sup> with the range from 7 months to 56 years. Many endoscopists are of the opinion that adults have a better outcome compared to children especially below 2 years of age who had low success rate.<sup>[14,16,17]</sup> Few authors found no relation with age.<sup>[18,22]</sup> We compared the aqueductal stenosis cases in relation to age, dividing 21 cases into a group less than 2 years (8 cases) and others above it (13 cases). The outcome rates showed to be 62.5% and 92.3% in groups less than and more than 2 years respectively. Though the difference was not statistically significant (Fisher's exact test  $P=0.28$ ) similar results was published by Singh D. et al of 70% and 100% below and above 2 years respectively. The immature CSF absorptive surfaces in infants might be the cause of low outcome rate below 2 years.<sup>[14]</sup> Kulkarni AV et al postulated the relative risk for ETV compared to shunt becomes progressively lower after about 3 months.<sup>[24]</sup> It is believed that The differences in the clinical response of adult patients to ETV differs from the paediatric group is believed due to differences in the duration of hydrocephalus, CSF circulatory dynamics and reduced elasticity of the brain in adults.<sup>[49]</sup>

Few studies had predicted the outcomes in ETV is more related to the aetiology than age.<sup>[19-21]</sup> The outcome of ETV in depends on the aetiology of Hydrocephalus and ranges from 50 to 94% where as in adult

population it constitutes to be 69% to 83%.<sup>[25]</sup> The overall clinical outcome in our study was 77.08%. Amongst various aetiologies, outcome rate in aqueductal stenosis was 80.95% (17/21 cases). Several other studies has shown the clinical outcome of ETV in aqueductal stenosis to vary from 56% to 87%.<sup>[17,26,27]</sup> This is the aetiology wherein studies have consistently reported to have good outcomes.

In shunt malfunction cases, the overall clinical outcome rate was 75% (12/16). In this subgroup, all the cases had primary aetiology of aqueductal stenosis. 10/16 cases presented with shunt migration or obstruction. ETV outcome rate was 80% (8/10 cases). 4/16 had shunt infection in whom after antibiotic management, ETV was performed having an outcome of 50% (2/4 cases). 100% (2/2 cases) outcome in slit ventricle syndrome (SVS). The reported rate of shunt malfunction in the first year of placement is 30%, and thereafter it is about 10% per year. The cumulative risk of infection was nearly 20% per patient, with most studies reported rates over a range of 5 to 10%.<sup>[31,32]</sup> Bilginer B et al had reported an overall shunt failure rate in patients shunted during infancy to be 48, 52, and 63% at one, two, and five years, with 20% of the patients having more than three revisions in five years.<sup>[31]</sup> Such a high complications rate and revision of shunt is not a cost effective and a leaves psychological stress and emotional impact over the family members. Many studies have shown an overall success rate of 70 to 80% of ETV in post shunt malfunction cases which is comparable to our study.<sup>[31,33-36]</sup> In cases with slit ventricle syndrome(SVS), on diagnosing, we placed a lumboperitoneal shunt (LPS). Both the cases had transient remission of symptoms followed by recurrence of headache. We went ahead with ETV in such cases using free hand technique, both had clinical improvement in the immediate post-operative period. It has been classically described to have a third ventricular dilatation (width) of 7mm or more for a safe ETV procedure to prevent injuries to the surrounding structures like thalamus and hypothalamus.<sup>[8]</sup> In both the cases when presented with failure of LPS for SVS, the ventricles size has increased enabling us to performing ETV uneventfully. Yadav et al has suggested careful and cautious blockage of the shunt for adequate third ventricular dilatation.<sup>[8]</sup>

In hydrocephalus due to chronic cases of post TB meningitis, outcome rates were 62.5% (5/8 cases). These rates are comparable to 70% ETV overall outcome rates in other larger studies.<sup>[28,29]</sup> Traditionally, placement of shunts has been the treatment of choice in TBM-related hydrocephalus, and still holds good in acute stage of the disease, the presence of inflammation in the ependymal lining especially in the floor of third ventricle making it thick and chances of bleeding is high(if ETV is performed), presence of tubercles in the ventricles and the subarachnoid spaces, and the basal exudates render performing ETV technically difficult and challenging and increase the chance of failure. But high rates of shunt malfunction necessitating revisions have been reported. With adequate medical therapy, the tubercles tend to heal and the basal exudates disappear to a large extent.<sup>[15]</sup> ETV has been found to be successful in the management of hydrocephalus associated with the chronic stages of tubercular meningitis.<sup>[28]</sup> It is possible to wash out the basal exudates during ETV procedure. The thick and opaque third ventricular floor even in chronic stages can be a hurdle for making a safe ostium in the floor.<sup>[15]</sup> Yadav et al has postulated that the results of ETV in these cases can be augmented by performing serial lumbar punctures and lumboperitoneal shunt, in case ETV alone didn't show clinical improvement. His results showed better outcome in cases who presented with better clinical grade.<sup>[30]</sup> Since our study is a retrospective study, we couldn't analyse on these factors. The failure of three cases of tb origin can be attributed to presence of complex hydrocephalous which have both the components of obstructive (which is overcome with ETV) as well as communicating which has defective absorption of CSF at arachnoid granulations and decreased or absence of patency in cranial subarachnoid space leading to failure.<sup>[8,30]</sup> the patency of subarachnoid cisternal space can be predicted preoperatively by measurement of spinal elastance and resistance.<sup>[40]</sup> The other three cases of hydrocephalus associated with arachnoid cyst and pineal tumour had 100% result. As these subset of cases have few cases statistical analysis couldn't be done. In case of arachnoid cyst there was a thin membrane between the cyst and the ventricle which was fenestrated endoscopically and an ETV was done. In pineal gland tumour, a biopsy was done after performing ETV. There was two schools of people on whether to perform ventriculostomy prior to or after the biopsy of the tumour.<sup>[15]</sup>

Following an ETV procedure, the results of a successful surgery are seen in terms of clinical and radiological improvement and in our series, we analysed the outcome in both aspects at one month and at one year following ETV. Clinical improvement in signs of increased intracranial pressure and radiologically the reduction in the size of the ventricle are correlation. It didn't show concordance between the two outcomes, suggesting the persistence of ventriculomegaly alone with clinical improvement of raised intracranial pressure signs and symptoms in post-operative period cannot be considered as a failure of ETV. The reduction in the periventricular leucency and prominence of gyri and sulci can be the earliest sign of successful ETV. In several studies radiological improvement after ETV varied from 53-87%.<sup>[16,17,27,38,39]</sup> In our series it was 52.08% and 75% at the end of first month and 67.44% and 74.41% at the end of one year of radiological and clinical improvement respectively following ETV. This shows that radiological improvement takes a longer time than clinical improvement, as documented in many studies.<sup>[14]</sup>

Santamarta D et al has analysed the ventricular changes following ETV and concluded that a decrease in the size of ventricle soon after ETV is shown to have a satisfactory clinical outcome and this response continues during the first few months following ETV. The reduction in size is more prominent in acute forms of hydrocephalus.<sup>[41]</sup> After a successful ETV, decrease in the size of third ventricular width was more than that of the lateral ventricles.<sup>[41,50,51]</sup> Romeo A et al concluded that most significant reduction in ventricular size was observed at the time of 1-year follow-up and later on with only modest reduction in Tectal plate gliomas.<sup>[42]</sup> So is the radiological improvement after ETV compared to post shunt wherein reduction in ventricular size in ETV is not as much as in a shunt cases with clinical improvement, attributed to the CSF flow dynamics where fluid is maintained in the same physiological space as before in ETV, thereby rendering the ventricles will not shrink as in a patient who has functioning shunt.<sup>[43]</sup> Schwartz et al had suggested in patients above 70 years, those who had been shunted previously or after meningitis, reduction of the size of the ventricular system should not be expected.<sup>[50,51]</sup>

The overall incidence of the complications rates have been reported to range from 0 to 26%<sup>[8,13,14,43,44]</sup> In our series it constituted to be 29.1%(14/48). This high rate compared to others could be due to learning curve of the surgeons and the cohort population of our study is small.<sup>[43]</sup> 3 out of 14 cases had mortality. First case had a torrential bleed intraoperatively, second had hypothalamic injury with hyperthermia and seizures leading to death and third had a sudden death around 7 months following surgery, cause of which not known. Few cases have been recorded in the literature with late sudden deaths after ETV. Mobbs RJ et al has postulated a technique of placement of a ventricular catheter and subcutaneous reservoir via the endoscope path after doing ETV. This subcutaneous reservoir is amenable for a percutaneous needle puncture to withdraw CSF and decreasing intra cranial pressure until a consultation of a neurosurgeon occurs when an acute blockage and neurological deterioration occurs.<sup>[45]</sup>

Rest of 11 out of 14 cases of complication are divided the 2 groups presenting with complications early to be less than one month and late thereafter. 90.9% (10/11) cases presented before one month duration. CSF leak from burr hole site was the commonest (6/10). 2 cases subsided with skin sutures, rest of the four cases persisted and went on for shunt placement. Incidence of CSF leak after ETV have varied between 2% to 7%.<sup>[47,48]</sup> Post-operative CSF leak can be avoided by plugging cortical and dural opening by gel foam, direct dural closure, especially in large ventriculomegaly with thin brain cortex in infants, or by using artificial dural substitute and tissue sealant in at risk patients or a galealpericranial flap intraoperatively.<sup>[8,46]</sup> We advocated dural plugging with gel foam. Presence of CSF leak should raise the suspicion of procedure failure or an infection and should be treated appropriately with a reinforcement skin sutures or antibiotics in case of an infection.<sup>[43]</sup> ventriculitis developed in 3 out of 10 cases, all treated with antibiotics and had shunt placement latter. One case had sub dural haemorrhage and has been evacuated. Subdural hematoma could be prevented by making burr hole at highest point by flexing the neck, proper haemostasis at burr hole site and by preventing sudden brain collapse and using continuous fluid irrigation.<sup>[8]</sup> only 1 out of 11 cases presented with pseudomenigocele at operative site with clinical symptoms of raised intracranial pressure, we went ahead with a shunt placement. Early failures presenting within one month of surgery are due to either poor absorptive surface or poor procedure, whereas late failures are mostly due to stomal closure.<sup>[10,14,16,18]</sup>

ETV failure is termed in whom clinical signs and symptoms of raised ICP persisted or deteriorated after the surgery. Out of 48 cases 11 were a failure (22.92%), three had mortality and the rest had shunt placement. ETV failure had reported to vary from 8 to 69%.<sup>[15]</sup> Etiologically aqueductal stenosis had the low failure of 19.05%(4/21 cases) which is comparable with the other studies projecting to a range of 10 to 20%.<sup>[15]</sup> though the failure rate in shunt malfunction and post TB meningitis cases have a high failure rate than that of aqueductal stenosis, the difference was not statistically significant. The failure rates in ETV can be reduced by careful selection of cases and pre-operative MRI of brain to assess the distance of posterior communicating artery from midline, high definition 3D reconstruction of multiplanar sequences to identify any membranes in the prepontine cisterns and the adequacy of prepontine interval, all helpful in performing a safe and functioning ETV in a well experienced and skilful hands.<sup>[8]</sup> Neuronavigation or stereotactic guidance augments the technique of proper entry and find an optimal trajectory to the floor of the third ventricle to avoid unnecessary injury to forniceal columns, thalamus and hypothalamus. Presence of thick and opaque floor of third ventricle, poor anatomical land marks, narrow space between mammillary bodies and dorsum sellae and high localization of basal artery bifurcation are the common difficulties encountered intraoperatively.<sup>[52]</sup> Patients with high CSF protein and fibrinogen levels or in patients with some intraoperative bleeding have high chances of stomal closure.<sup>[16]</sup> With the advent of Cine phase-contrast MRI, we can distinguish communicating from noncommunicating hydrocephalus and also detect any abnormality in basal cisterns.<sup>[8]</sup> post operatively, cine phase contrast MRI is useful in determining the patency of the stoma and hence during follow up, decrease in the flow across the stoma can be depicted which is an early sign of stoma closure.<sup>[8]</sup> At our institute, 3T MRI was not equipped with cine phase contrast CSF flow study software sequences, rendering us to diagnose the

ETV failure more clinically. As our study is a retrospective one, we could only speculate the cause of the complications and failure.

**V. Figures and Tables**

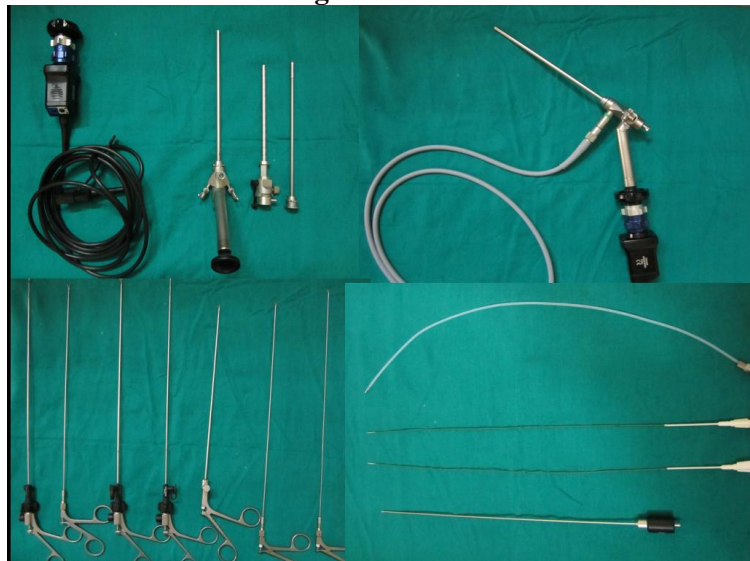

Fig : 1 Endoscopic equipment.

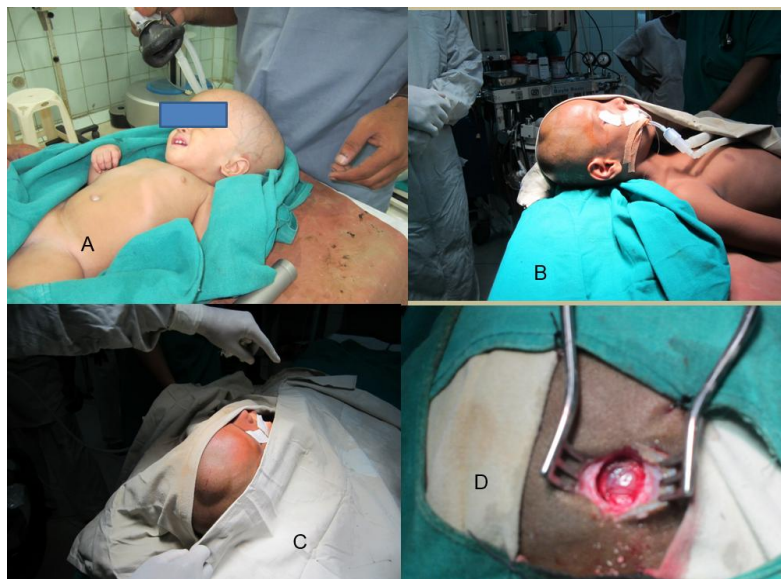

Fig : 2 the picture depicts A) baby preparing to anesthetize. B) position of the baby with in supine with slight head flexion. C) baby being draped. D) burr hole placement.

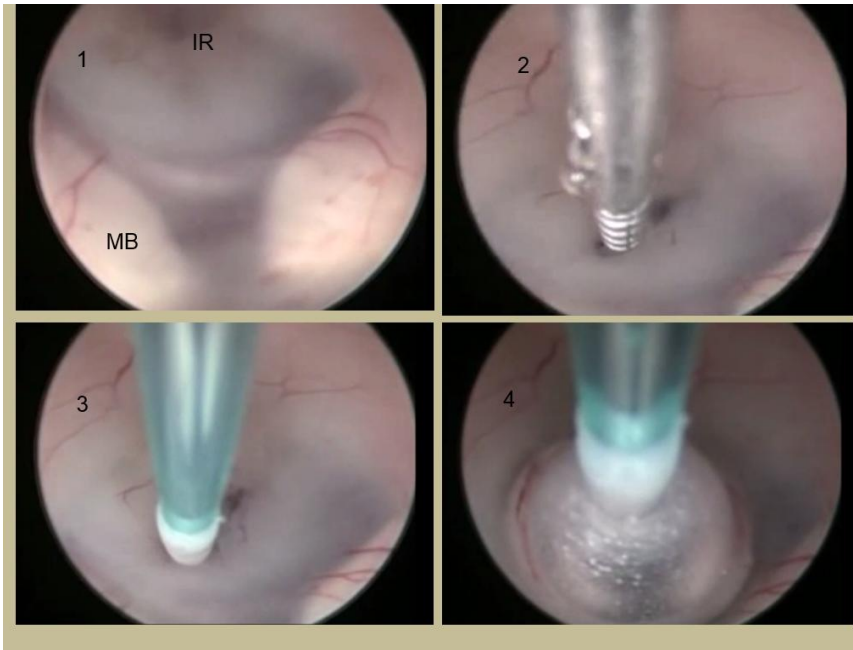


Fig 4: endoscopic view of the floor of the third ventricle 1) the landmarks of IR (Infundibular Recess) anteriorly in the midline and MB (Mammillary Bodies) pair on either side of the midline posteriorly. 2) the fenestration in the floor made midway between IR and MB in the midline using a cautery forceps. 3) the fogarty catheter is being negotiated into the ostium. 4) balloon dilatation of the ostium .

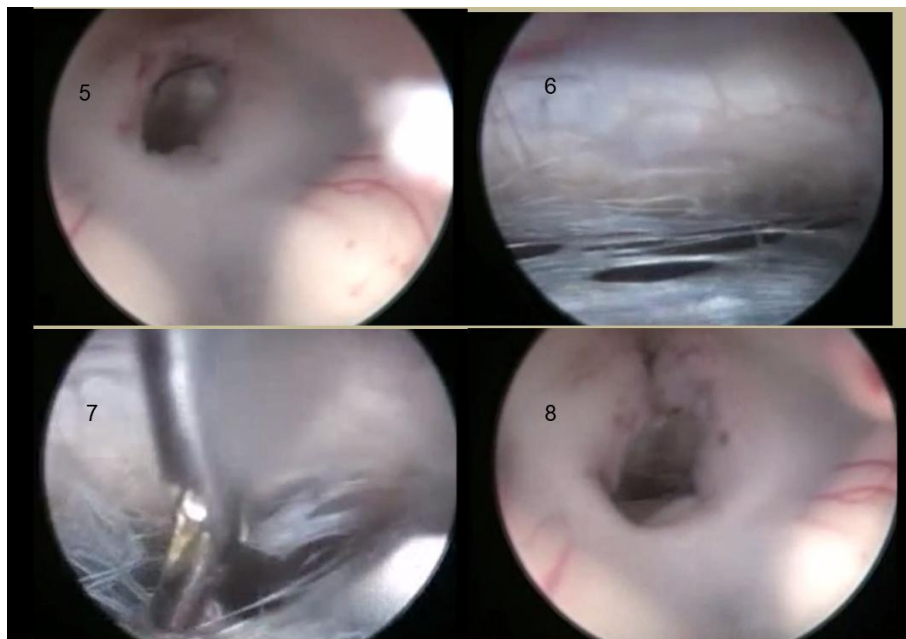


Fig : 4 5) the stoma in floor of third ventricle after balloon dilatation. 6) Visualization of the liliquest membrane through the stoma. 7) Removal of the membrane. 8) Adequate stoma with oscillating to and fro CSF flow

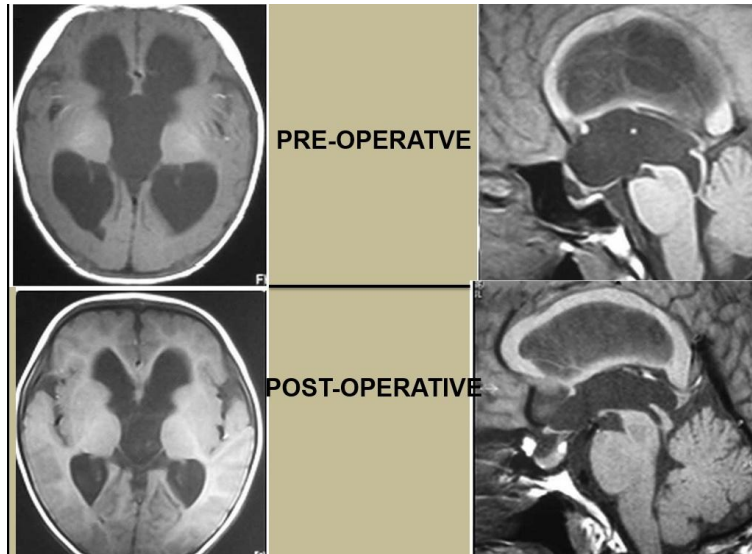


Fig : 5 MRI BRAIN axial and sagital T1 wt sequences on left and right half respectively. Upper two images are pre operative imaging showing dilated ventricles. Lower two images are post operative imaging showing decreased ventricular diameters, periventricular CSF seepage has disappeared with prominent gyri ans sulci suggesting good radiological outcome of ETV.

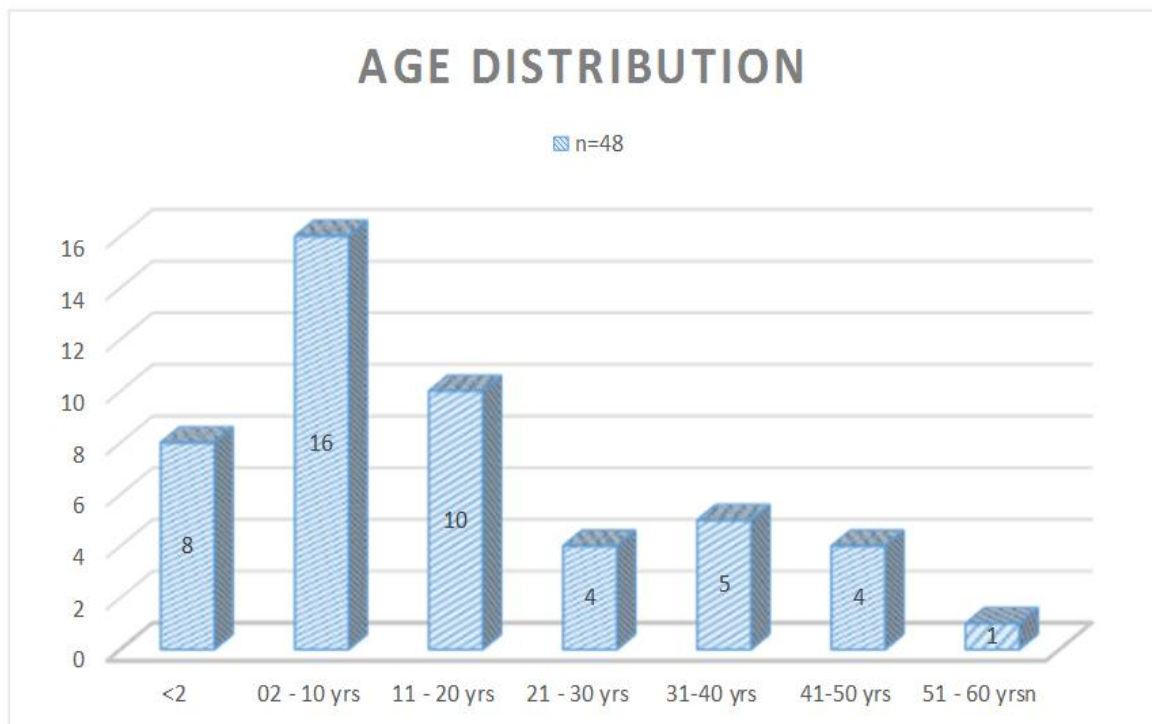


Fig 6: age distribution of the patients operated with ETV.



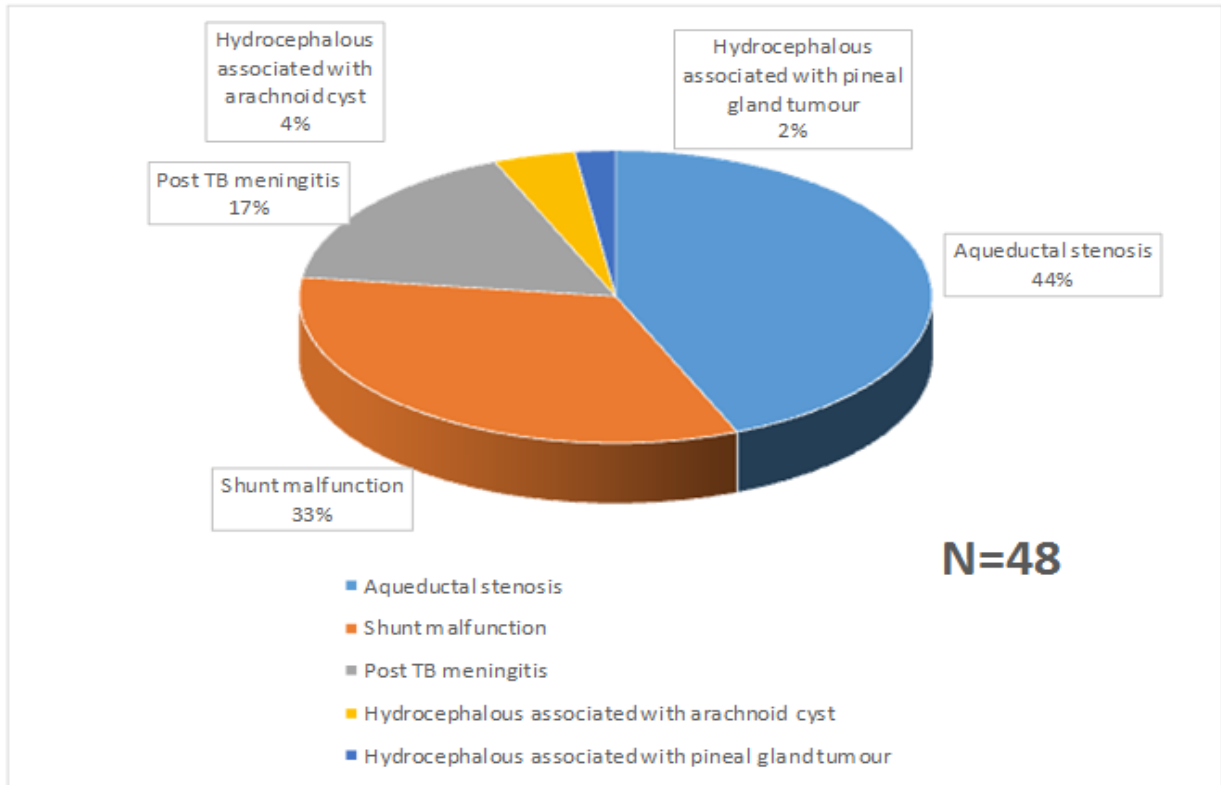


Fig 7: pie diagram depicting the various aetiologies for which ETV was performed in our study

Table 1: Demographic statistics.

Total Number of patients	48
<2yrs	8
>2yrs	40
male	33 (68.75 %)
Female	15 (31.25 %)
Male to female ratio	2.2:1
Mean age at time of ETV	16.5 years
Minimum age	7 months
Maximum age	56 years

Table 2: Etiology and outcome rates

Etiology	Number	percentage	Good outcome	failure	Success rate %
Aqueductal stenosis	21	56.25	17	4	80.95
Shunt malfunction(all post aqueductal stenosis)	Migration/obstruction	10	8	2	80
	Infection	4	2	2	50
	Slit ventricle syndrome	2	2	0	100
	Total	16	12	4	75
Post TB meningitis	8	16.6	5	3	62.5
Hydrocephalous associated with arachnoid cyst	2	4.16	2	0	100
Hydrocephalous associated with pineal gland tumour	1	2.08	1	0	100
Total	48		37	11	77.08

Table 3: complications and failure rate of ETV in our series

	Complications	Endurance of complications		Onset of complications		%	Failure <sup>#</sup>
		Transient	Persistent	Early (<1month)	late		
morbidity	CSF leak	2*	4 **	6		12.5	4
	Ventriculitis	3 <sup>^</sup>		3		6.25	3
	Seizure	1 <sup>\$</sup>		1		2	
	Pseudomeningocele		1**		1	2	1
	<b>Total morbidity</b>	<b>6</b>	<b>5</b>	<b>10</b>	<b>1</b>	<b>22.9</b>	
mortality	Intra operative-torrential bleed			1		2	1
	Immediate post-operative –seizure, hyperthermia			1		2	1
	Sudden death				1	2	1
	<b>Total mortality</b>			<b>2</b>	<b>1</b>	<b>6.25</b>	
<b>Total</b>			<b>12</b>	<b>2</b>	<b>29.1</b>	<b>11 (22.9%)</b>	

# Failure means those cases who have persistence or deterioration of clinical status after 2nd post-operative day in whom we have resorted to perform a shunt procedure.

\* managed by placing skin sutures

\*\* managed by performing ventriculo-peritoneal shunt (VPS).

<sup>^</sup> Antibiotic coverage was administered, if necessary placed an external ventricular drainage and with CSF culture sterile, done VPS.

<sup>\$</sup> placed on antiepileptic drugs.

Table 4: clinical and radiological outcome of patients with one month and one year follow up.

Outcome	Follow up duration			
	One month		One year	
	N=48	%	N=43	%
Clinical	39	81.25	32	74.41
Radiological *	25	52.08	29	67.44
Failure				
Shunt procedure	7	14.58	8	18.60
Mortality	2	04.16	3	06.97

\*radiological outcome was assessed in term of decrease in ventriculomegaly.

## VI. Conclusion

Endoscopic third ventriculostomy is a logical alternative to the ventriculoperitoneal shunting procedures in the management of hydrocephalus as it renders an establishment of physiological CSF circulation and avoidance of implantation of foreign body and its associated complications with comparable good outcome in selected cases. Hence a good selection of cases, pre-operative planning, proper imaging, surgeon's endoscopic expertise and good postoperative care help in improving results. Our study on age and etiological outcomes showed variation in outcome numerically but did not show significant statistical difference. We recommend a large and a varied study population, multiple studies at multiple centres, longer duration of follow up will further delineate the advantages and disadvantages of the procedure.

## References

- [1] Van Beijnum J, Hanlo PW, Fischer K, Majidpour MM, Kortekaas MF, Verdaasdonk RM, et al. Laser-assisted endoscopic third ventriculostomy: Long-term results in a series of 202 patients. *Neurosurgery* 2008;62:43743; discussion 443-4.
- [2] Mohanty A, Santosh V, Devi BI, Satish S, Biswas A. Efficacy of simultaneous single-trajectory endoscopic tumor biopsy and endoscopic cerebrospinal fluid diversion procedures in intra- and paraventricular tumors. *Neurosurg Focus* 2011;30:E4.
- [3] Morgenstern PF, Osburn N, Schwartz TH, Greenfield JP, Tsiouris AJ, Souweidane MM. Pineal region tumors: an optimal approach for simultaneous endoscopic third ventriculostomy and biopsy. *Neurosurg Focus* 2011;30:E3.
- [4] Al-Tamimi YZ, Bhargava D, Surash S, Ramirez RE, Novegno F, Crimmins DW, et al. Endoscopic biopsy during third ventriculostomy in paediatric pineal region tumours. *Childs Nerv Syst* 2008;24:1323-6.
- [5] Oppido PA, Fiorindi A, Benvenuti L, Cattani F, Cipri S, Gangemi M, et al. Neuroendoscopic biopsy of ventricular tumors: A multicentric experience. *Neurosurg Focus* 2011;30:E2.
- [6] Roopesh Kumar SV, Mohanty A, Santosh V, Satish S, Devi BI, Praharaj SS, et al. Endoscopic options in management of posterior third ventricular tumors. *Childs Nerv Syst* 2007;23:1135-45.
- [7] Garg A, Suri A, Chandra P, S, Kumar R, Sharma B, S, Mahapatra A, K. Endoscopic Third Ventriculostomy. *Pediatr Neurosurg* 2009;45:1-5
- [8] Yadav YR, Parihar V, Pande S, Namdev H, Agarwal M. Endoscopic third ventriculostomy. *J Neurosci Rural Pract* 2012;3:163-73
- [9] Neils DM, Wang H, Lin J. Endoscopic third ventriculostomy for shunt malfunction: What to do with the shunt?. *Surg Neurol Int* 2013;4:3.
- [10] Gieger M, Cohen AR. The history of neuroendoscopy. In: AR cohen, SJ Hains, eds. Minimally invasive technique in neurosurgery series. Concepts in neurosurgery. Congress of neurosurgical surgeons. Baltimore: MD Williams & Wilkins; 1995. pp. 1-5.

- [11] Hoffman HJ, Harwood Nash D, Gilday DL. Percutaneous third ventriculostomy in the management of noncommunicating hydrocephalus. *Neurosurgery* 1980;7:313-21.
- [12] Brohi SR, Brohi AR, Sidiqui MA, Mughal SA, Saeed S. Outcome of endoscopic third ventriculostomy in hydrocephalus. *JSP* 2010;15:25-28 .
- [13] Mian Iftikhar ul Haq. Endoscopic third ventriculostomy (ETV). *Professional Med J* 2014;21(1): 144-147.
- [14] Singh D, Gupta V, Goyal A, Singh H, Sinha S, Singh A, Kumar S. Endoscopic third ventriculostomy in obstructed hydrocephalus . *Neurol India* 2003;51:39-42
- [15] Moorthy RK, Rajshekhkar V. Endoscopic third ventriculostomy for hydrocephalus: A review of indications, outcomes, and complications. *Neurol India* 2011;59:848-54
- [16] Hopf NJ, Grunert P, Fries G Resch DM, Pernecksky A. Endoscopic third ventriculostomy: Outcome analysis of 100 consecutive procedures *Neurosurgery* 1999;44:795-806.
- [17] Tisell M, Almstrom O, Stephenson H, Tullberg M, Wikkelso C. How effective is Endoscopic third ventriculostomy in treating adult hydrocephalus caused by primary aqueductal stenosis. *Neurosurgery* 2000;46:104-11.
- [18] Brockmayer D, Abtin K, Carey L, Walker ML. Endoscopic third ventriculostomy: An out come analysis. *Pediatr Neurosurg* 1998;28:236-40
- [19] Buxton N: Neuroendoscopic third ventriculostomy. *Neurosurg Focus* 1999, 6(4): Article 2
- [20] Mehdorn HM, et al: Endoscopic third ventriculostomy in infants. *J Neurosurg* 2005, 103(1 Suppl): 50-3
- [21] Nowoslawska E, Polis L, Kaniewska D, et al: Influence of neuroendoscopic third ventriculostomy on the size of ventricles in chronic hydrocephalus. *J Child Neurol* 2004, 19(8): 579-87
- [22] Lipina R, Reguli S, Dolezilová V, Kuncíková M, Podesvová H. Endoscopic third ventriculostomy for obstructive hydrocephalus in children younger than 6 months of age: Is it a first-choice method? *Childs Nerv Syst* 2008;24:1021-7.
- [23] Zohdi AZ, El Damaty AM, Aly KB, El Refaee EA. Success rate of endoscopic third ventriculostomy in infants below six months of age with congenital obstructive hydrocephalus (a preliminary study of eight cases). *Asian J Neurosurg* 2013;8:147-52
- [24] Kulkarni AV, Drake JM, Kestle JR, Mallucci CL, Sgouros S, Constantini S; Canadian Pediatric Neurosurgery Study Group. Endoscopic third ventriculostomy vs cerebrospinal fluid shunt in the treatment of hydrocephalus in children: A propensity score-adjusted analysis. *Neurosurgery* 2010;67:588-93.
- [25] Moujahed Labidi, MD, Pascale Lavoie, MD, MSc, FRCSC, Geneviève Lapointe, MD, FRCSC, Sami Obaid, MD, Alexander G. Weil, MD, FRCSC, Michel W. Bojanowski, MD, FRCSC, and André Turmel, MD, MSc, CSPQ. (2015) Predicting success of endoscopic third ventriculostomy: validation of the ETV Success Score in a mixed population of adult and pediatric patients. *Journal of Neurosurgery* 123:6, 1447-1455.
- [26] Kunz U, Goldmann A, Bader C, Waldbaur H, Oldenkott P. Endoscopic fenestration of floor of the third ventricle in aqueductal stenosis. *Minim Invasive Neurosurg* 1994;37:42-7.
- [27] Cinalli G, Sainte-Rose C, Chumas P, Zerah M, et.al. Failure of Third ventriculostomy in the treatment of aqueductal stenosis in children. *J Neurosurg* 1999;90:448-54.
- [28] Warf BC, Campbell JW. Combined endoscopic third ventriculostomy and choroid plexus cauterization as primary treatment of hydrocephalus for infants with myelomeningocele: Long term results of a prospective intent-to-treat study in 115 East African infants. *J Neurosurg Pediatr* 2008;2:310-6
- [29] Chugh A, Husain M, Gupta R, et al. Surgical outcome of tuberculous meningitis hydrocephalus treated by endoscopic third ventriculostomy: prognostic factors and postoperative neuroimaging for functional assessment of ventriculostomy. *J Neurosurg Pediatrics*. 2009;3:371–7.
- [30] Yadav YR, Parihar V, Agrawal M, Bhatele PR. Endoscopic third ventriculostomy in tubercular meningitis with hydrocephalus. *Neurol India* 2011;59:855-60
- [31] Bilginer B, Oguz KK, Akalan N. Endoscopic third ventriculostomy for malfunction in previously shunted infants. *Childs Nerv Syst* 2009;25:683-8.
- [32] Sandberg DI. Endoscopic management of hydrocephalus in pediatric patients: A review of indications, techniques and outcomes. *J Child Neurol* 2008;23:550-60.
- [33] Baldauf J, Fritsch MJ, Oertel J, Gaab MR, Schroder H. Value of endoscopic third ventriculostomy instead of shunt revision. *Minim Invasive Neurosurg* 2010;53:159-63.
- [34] Boschert J, Hellwig D, Krauss JK. Endoscopic third ventriculostomy for shunt dysfunction in occlusive hydrocephalus: Long term follow up and review. *J Neurosurg* 2003;98:1032-9.
- [35] Melikian A, Korshunov A. Endoscopic third ventriculostomy in patients with malfunctioning CSF-shunt. *World Neurosurg* 2010;74:532-7.
- [36] Marton E, Feletti A, Basaldella L, Longatti P. Endoscopic third ventriculostomy in previously shunted children: A retrospective study. *Childs Nerv Syst* 2010;26:937-43.
- [37] Yadav YR, Mukerji G, Parihar V, Sinha M, Pandey S. Complex hydrocephalus (combination of communicating and obstructive type): An important cause of failed endoscopic third ventriculostomy. *BMC Res Notes* 2009;2:137.
- [38] Gagemi M, Donati P, Maiuri F, Longatti P, Gondano U, Mascari C. Endoscopic third ventriculostomy for hydrocephalus. *Minim Invasive Neurosurg* 1999;42:128-32
- [39] Schroeder HWS, Gabb MR. Endoscopic aqueductoplasty. *Neurosurgery* 1999;45:508-16.
- [40] Bech-Azeddine R, Nielsen OA, Løgager VB, Juhler M. Lumbar elastance and resistance to CSF outflow correlated to patency of the cranial subarachnoid space and clinical outcome of endoscopic third ventriculostomy in obstructive hydrocephalus. *Minim Invasive Neurosurg* 2007;50:189-94.
- [41] Santamarta D, Martín-Vallejo J, Díaz-Alvarez A, Mailló A. Changes in ventricular size after endoscopic third ventriculostomy. *Acta Neurochir (Wien)* 2008;150:119-27; discussion 127.
- [42] Romeo A, Naftel RP, Griessenauer CJ, Reed GT, Martin R, Shannon CN, Grabb PA, Tubbs RS, Wellons JC 3rd. Long-term change in ventricular size following endoscopic third ventriculostomy for hydrocephalus due to tectal plate gliomas. *J Neurosurg: Pediatrics*. 2013 Jan;11(1):20-5. doi: 10.3171/2012.9.PEDS12243. Epub 2012 Nov 9.
- [43] Khalid N Mayah. Endoscopic third ventriculostomy - Experience in Basrah, Iraq. *Pan Arab Journal of Neurosurgery*. volume 13, no. 2, october 2009.
- [44] Bouras T, Sgouros S. Complications of endoscopic third ventriculostomy. *Areview. J Neurosurg Pediatrics* 2011; 7: 643-9.
- [45] Mobbs Ralph J, Vonau, Marianne, Davies, Mark A. Death after Late Failure of Endoscopic Third Ventriculostomy: A Potential Solution. *Neurosurgery*:August 2003 - Volume 53 - Issue 2 - pp 384-386.
- [46] Mohanty A, Suman R. Role of galeal-pericranial flap in reducing postoperative CSF leak in patients with intracranial endoscopic procedures. *Childs Nerv Syst* 2008;24:961-4

- [47] Schroeder HW, Niendorf WR, Gaab MR. Complications of endoscopic third ventriculostomy. *J Neurosurg* 2002;96:1032-40. 12.
- [48] Kwiek SJ, Mandra M, Baowski P, Luszawski J, Duda I, Wolwender A, et al. Endoscopic third ventriculostomy for hydrocephalus: early and late efficacy in relation to aetiology. *Acta Neurochir (Wien)* 2003;145:181-4.
- [49] Dusick JR, McArthur DL, Bergsneider M. Success and complication rates of endoscopic third ventriculostomy for adults hydrocephalus: a series of 108 patients. *Surg Neurol* 2008; 69: 5-15.
- [50] Schwartz TH, Yoon SS, Cutruzzola FW. Third ventriculostomy: post-operative ventricular size and outcome. *Minim Invas Neurosurg* 1996; 39: 122-9.
- [51] Schwartz TH, Ho B, Prestigiacomo CJ, et al. Ventricular volume following third ventriculostomy. *J Neurosurg* 1999; 91: 20-5.
- [52] Grand W, Leonardo J. Endoscopic third ventriculostomy in adults: a technique for dealing with the neural (opaque) floor. *J Neurosurg* 2011; 114: 446-53.