

## Sion Test: - As A Screening Test in Infertile Women before the Laparoscopy.

Dr. G P.N Karunavathi<sup>1</sup> Dr Ratna<sup>2</sup>

<sup>1,2</sup> (Dept of obst & gynaec, Siddhartha medical college/DRNTR UHS, India.)

**Abstract:** The study consists of 50 infertile women for a period of 2yrs after excluding male factors and ovulatory factors. The tubal test is done by sion test & the tubal patency is examined. Patients who exhibit tubal block .are subjected for laparoscopy chromotubation.The study shows 82% of tubal patency & 18% tubal block. Those 18% patients are subjected to laproscopy. In that 55% shows unilateral patency 45% shows bilateral block. Other causes of infertility I.e fibroid, polyp, polycystic ovaries, uterine anomalies are detected with this sion test. The management of the study is discussed.

**Keywords:** Infertility, laparoscopy, sion test ( Hydro Sono salpingography) tubal block and tubal patency.

### I. Introduction

The incidence of the female infertility is 37%. The tubal factors accounts for 30-40%. Sion test is simple screening method, it can study the tubal patency, tubal block, other associated causes of infertility i.e., fibroid, polyp, polycystic ovaries, uterine anomalies are detected. Every method has its own merits and demerits. Laparoscopy is invasive procedure, it has anesthetic, surgical complication, expensive, time consuming procedure.

### II. Material And Methods

3D u/s with transvaginal probe, Instruments such as sim's speculum, Vulsellum sponge holder, Drape, Beta dine solution ,no8 foley's catheter, Inj hydrocortisone Inj atropine Inj hyaluronidase, Inj gentamycin ,Inj avil, Distilled water 5cc &20cc syringes. The study consists of 50 infertile women including both primary and secondary cases for a period of 2yrs after excluding male factors, pelvic inflammatory disease, ovulatory factors for tubal patency.

#### 2.1 Procedure:

Ask the patient to attend for the test in follicular phase(7<sup>th</sup> day). Before the procedure, patients detailed history was taken, the patient is examined preliminary for any vaginal infection and are treated. The procedure is explained and informed consent is taken. Inj atropine is given to prevent to vasovagal attack.20ccsyringe is loaded with distilled water mixed with inj hydrocortisone250mg, inj hyaluronidase, inj gentamycin80mg ,& kept aside. Patient is kept in lithotomy position, vaginal is cleaned with antiseptic solution, vaginal probe is introduced & preliminary survey is done. Then the probe is taken out & sim's speculum is introduced anterior lip of cervix is hold with vulsellum no 8 foley's catheter is introduced into the uterine cavity after dilatation of cervix 3ml of distilled water is injected into the bulb so as to retain the catheter . The tvs probe is introduced and the position of foley's bulb within the uterine cavity is checked.

The uterus is scanned longitudinally and transverse axis. Then visualize both ovaries & any fluid in POD. Approximately 20-30ml of distilled water is pushed through the catheter. The flow of the fluid through the tube is detected and fluid collection in POD is seen. All the patient were allowed to take rest for a period of 8hrs. then sent home by giving 7 day course of antibiotic and analgesic. Those who exhibit tubal block patients are subjected to chromotubation, later for confirmation.


#### Observations:

The present study was carried out in 50 infertile women both the primary and secondary infertile women are included in the study. Results are as follow:

#### Tables

**Table1:** The distribution of cases according to type of infertility.

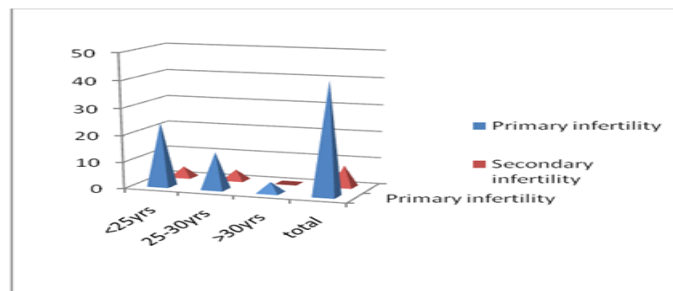
Primary infertility	Secondary infertility	Total
42(84.1%)	8(16)	50



**Table 1** shows the majority of the cases are belonging to primary infertility 84%

**Table2:** The distribution of cases according to age.

Age	Primary infertility	Secondary infertility
<25yrs	24(57.14%)	4(50%)
25-30yrs	14(33.33%)	4(50%)
>30yrs	4(9.52%)	0
total	42(100%)	8(100%)



**Table 2** shows the majority of the cases comes under less than 30 years age group.

**Table3:**The distribution of cases according to marital life.

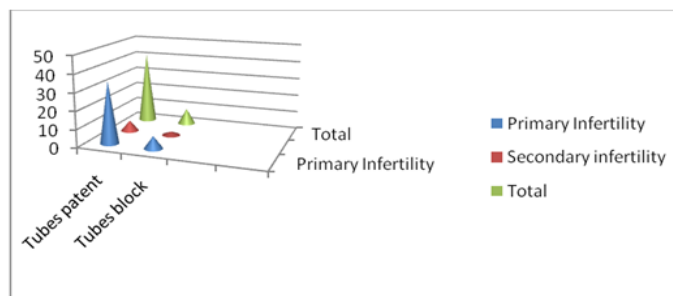
Age	Primary infertility	Secondary infertility
1-3yrs	10(23.80%)	4(50%)
4-6yrs	18(42.85%)	2(25%)
6-9yrs	8(19.04%)	0
>9yrs	6(14.28%)	2(25%)
total	42(100%)	8(100%)



**Table 3** shows the majority of cases are in between 4 -6 years marital life

**Table4:** The distribution of cases according to tubal spillage.

Tubal spillage	Primary Infertility	Secondary infertility	Total
Tubes patent	35(83.83%)	6(75%)	41(82%)
Tubes block	7(16.66%)	2(25%)	9(18%)



**Table 4** shows the tubal patency 82%

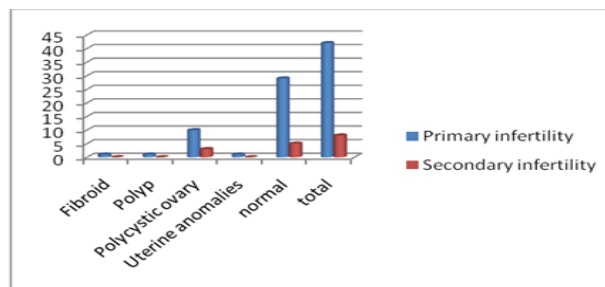
**Table5:** Laparoscopic chromotubation result.

.Unilateral patency	Bilateral block	total
5(55.55%)	4(44.44%)	9(100%)

**Table6:** Abnormal findings detected..

**Table6:** Abnormal findings detected.

others	Primary infertility	Secondary infertility
Fibroid	1(2.38%)	0
Polyp	1(2.38%)	0
Polycystic ovary	10(23.80%)	3(37.5%)
Uterine anomalies	1(2.38%)	0
normal	29(69.04%)	5(62.5%)
total	42(100%)	8(100%)

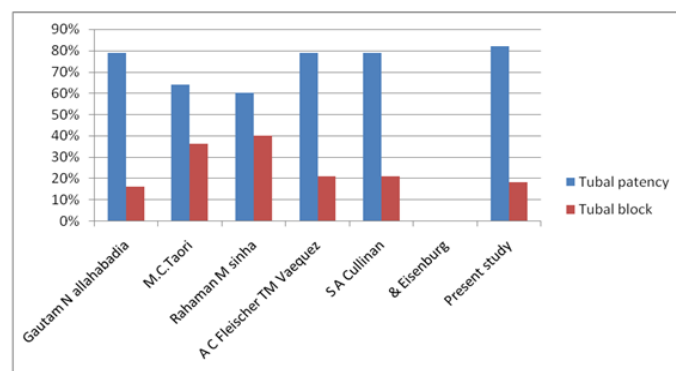


Cases of primary infertility who had bilateral block during chromotubation showed partial spill in sion test indicate the threpeutic value of procedure. Also 3 patients conceived after tubal proving threpeutic value.

### III. Discussion

Sion test is used for Tubal patency test in infertile women. Along with tubal patency, it can detect fibroid , polyp, & uterinal anomalics [3,4,5,6,7}Tubal patency test by Transvaginal sonography can be used safely as a first step examination of tubal patency. Whose tubes are patent can go for medical treatment of infertility, while doubtful cases should be investigated by laproscopy.[3,4]Sevaral Ultrasound technique 3D Sonography, Color Doppler Sonography, Transvaginal sonography , sion test for detection of tubal patency is equivalent to laproscopy hysteroscopy procedure[2]Transvaginal sonography is an office simple op procedure.[3,5] Transvaginal sonography is practically useful for diagnosis of endometrial polyp, endometrial abnormalities [6,7] The present study includes 50 cases of infertile women of both primary and secondary. This test for tubal patency is done by sion test &those patient who exhibit tubal block are subjected to laparoscopic chromotubation for confirmation. In present study tubal patency is 82%.

studies	Tubal patency	Tubal block
Gautam N allahabadia	79%	16%
M.C.Taori	64%	36%
Rahaman M sinha	60%	40%
A C Fleischer TM Vaequez	79%	21%
S A Cullinan & Eisenburg	79%	21%
Present study	82%	18%



**Disadvantage** of test : which side of tubal block cannot be detected.

2) presence of fluid in POD may be due to hydrosapinx.

#### **IV. Conclusion**

No ideal test for tubal patency. Laparoscopy is the surgical procedure, it is diagnostic, therapeutic and can diagnose tubal adhesions also.

Advantage of sion test over laparoscopy- No surgical and anaesthetic complications, cost effective, simple procedure, time saving. It can be used as a preliminary screening test and borderline or negative cases are posted for laparoscopy.

#### **Reference**

- [1]. M. Nabil El-Tabbakh, Md and Peter Slamka, MD, Transvaginal Sonohysterography (Tv-Sh), Versus Hysterosalpingography (Hsg) And Laparoscopy, *Obgyn.net* July 05, 2011
- [2]. FERNANDO BONILLA-MUSOLES, FRANCISCO RAGA, JAVIER BLANES, LUIZ A. BILAO, and NEWTON G. OSBORNE .Sonohysterosalpingography with Transvaginal color Doppler and Three-Dimensional Ultrasound: State of the Art, *Journal of Gynecologic Surgery* February 2, 2009
- [3]. Seal Subrata Lall, Ghosh Debdatta, Saha Debdas, Bhattacharya Ajit Ranjan, Ghosh Suhash, Mitra Supratim Comparative evaluation of sonosalpingography, hysterosalpingography, and laparoscopy for determination of tubal patency, *The Journal of obstetrics and gynaecology of India.*, March/April 2007
- [4]. Volpi E, Zuccaro G, Patriarce A, Rustichelli S, Sismondi P Transvaginal sonographic tubal patency testing using air and saline solution as contrast media in a routine infertility clinic setting, *researchgate.net* 1996 Jan: 7
- [5]. Allahbadia GN, Fallopian tubes and ultrasonography: the Sion experience. *Fertil Steril* 1992
- [6]. Syrop CH, Sahakian V Transvaginal sonographic detection of endometrial polyps with fluid contrast augmentation *Obstet gynecol*, 1992 June
- [7]. Steven R Goldstein, MD Saline infusion sonohysterography